




OPEN ACCESS

Acute intracerebral haemorrhage: diagnosis and management

Iain J McGurgan ¹, Wendy C Ziai,² David J Werring,³ Rustam Al-Shahi Salman,⁴ Adrian R Parry-Jones⁵

¹Wolfson Centre for Prevention of Stroke and Dementia, Nuffield Department of Clinical Neurosciences, University of Oxford, UK

²Division of Brain Injury Outcomes, Department of Neurology, The Johns Hopkins University, Baltimore, Maryland, USA

³Stroke Research Centre, Department of Brain Repair and Rehabilitation, UCL Queen Square Institute of Neurology and the National Hospital for Neurology and Neurosurgery, UCL, London, UK

⁴Centre for Clinical Brain Sciences, University of Edinburgh, Edinburgh, UK

⁵Manchester Centre for Clinical Neurosciences, Manchester Academic Health Science Centre, Salford Royal NHS Foundation Trust, Salford, UK

Correspondence to

Adrian R Parry-Jones, Clinical Sciences Building, Salford Royal NHS Foundation Trust, Stott Lane, Salford M6 8HD, UK; adrian.parry-jones@manchester.ac.uk

Accepted 18 October 2020



Check for updates

© Author(s) (or their employer(s)) 2020. Re-use permitted under CC BY-NC. No commercial re-use. See rights and permissions. Published by BMJ.

To cite: McGurgan IJ, Ziai WC, Werring DJ, et al. *Pract Neurol* Epub ahead of print: [please include Day Month Year]. doi:10.1136/practneurol-2020-002763

ABSTRACT

Intracerebral haemorrhage (ICH) accounts for half of the disability-adjusted life years lost due to stroke worldwide. Care pathways for acute stroke result in the rapid identification of ICH, but its acute management can prove challenging because no individual treatment has been shown definitively to improve its outcome. Nonetheless, acute stroke unit care improves outcome after ICH, patients benefit from interventions to prevent complications, acute blood pressure lowering appears safe and might have a modest benefit, and implementing a bundle of high-quality acute care is associated with a greater chance of survival. In this article, we address the important questions that neurologists face in the diagnosis and acute management of ICH, and focus on the supporting evidence and practical delivery for the main acute interventions.

INTRODUCTION

Spontaneous intracerebral haemorrhage (ICH) refers to non-traumatic bleeding in the brain parenchyma and is the deadliest form of stroke. The high 1-month case-fatality rate of ~40% and poor long-term outcome make it a major contributor to global morbidity and mortality.^{1 2} Although ICH accounts for a minority of stroke worldwide (10–30%), it is associated with a greater burden of disability-adjusted life years than ischaemic stroke, given its high incidence in low- and middle-income countries.³ Despite dramatic drops in ischaemic stroke mortality rates,³ there has been limited improvement in case fatality from ICH in the last few decades^{2 4 5} and most survivors are left with severe disability.^{2 6 7}

ICH is not a single entity; 85% of cases are due to cerebral small vessel disease, predominantly deep perforator arteriopathy (also termed hypertensive arteriopathy or arteriosclerosis) and cerebral

amyloid angiopathy, while the remainder results from a macrovascular (eg, arteriovenous malformation, cavernoma, aneurysm and venous thrombosis) or neoplastic cause. Vascular malformations are the most common cause of ICH in young adults, accounting for up to one-third of cases.⁸ The term ‘primary’ ICH is often applied to cases caused by cerebral small vessel disease, but it discourages adequate investigation and accurate classification and is not recommended. Deep haemorrhages account for about two-thirds of cases, occur in the internal capsule, basal ganglia or brainstem, and more likely result from deep perforator arteriopathy. About 5–10% of ICH occurs in the cerebellum. The remainder is lobar haemorrhage located in cortico-subcortical areas, often near or reaching the cerebral convexities, of which ~40% are due to arteriosclerosis alone, ~40% to arteriosclerosis and amyloid angiopathy and the remaining ~20% to amyloid angiopathy alone.⁹

There are no medical treatments for acute ICH that have been definitively proven in primary outcome analyses of randomised clinical trials. Patients with ICH are frequently referred for surgery, but the roles of various surgical methods and timing of surgery remain controversial. In this article, we outline a practical approach to the diagnosis and management of acute ICH.

ACUTE EVALUATION

Time is limited; what information do I need to obtain early on?

The approach to an efficient and focused history and physical examination in suspected acute stroke has been outlined in the first article in this series.¹⁰ It is important to obtain a history of any recent trauma, including from a witness if available, and to assess for any circumstantial evidence, making sure to determine

HOW TO DO IT

clinically whether the trauma preceded the haemorrhage or vice versa. Acute ischaemic stroke and ICH cannot be reliably distinguished at the bedside but the diagnosis is made rapidly and easily on imaging, so every effort should be made to minimise delays to the initial CT brain scan. Crucial information specific to the management of ICH must be obtained as early as possible after the CT brain scan; [table 1](#) lists the key questions to ask focused on *modifiable* predictors of outcome.

The National Institutes of Health Stroke Scale (NIHSS) used for ischaemic stroke is also valuable in ICH, but its utility may be limited by the more frequent occurrence of depressed consciousness in ICH.²¹ The Glasgow Coma Scale (GCS) score is the most useful initial evaluation because of its similar prognostic value to NIHSS, its simplicity and its incorporation in the ICH score ([figure 1](#) outlines its calculation). However, as in ischaemic stroke, aphasia can reduce the verbal subdomain score, and thus cause underestimation of the GCS.

What baseline tests should I perform?

For all the complexity and uncertainty in ICH management, the initial diagnosis of acute blood in the brain substance is straightforward. Non-contrast brain CT ([figure 2](#)) is rapid, highly sensitive and specific for all forms of ICH, and widely available, so is considered the reference standard for ICH diagnosis.^{21 26 27}

The CT scan should be assessed for ICH location, brain changes consistent with small vessel disease (atrophy, leukoaraiosis ([figure 2](#)) and lacunes), the presence and degree of mass effect or midline shift, hydrocephalus, intraventricular extension and the size of the haematoma. Haematoma volume independently predicts haematoma expansion and early mortality^{11 28} and can be estimated rapidly and accurately on CT with the ABC/2 formula, as shown in [figure 1](#). A blood-fluid level is highly specific for coagulopathy or the use of anticoagulants and should prompt a search for these factors if not already established.²⁹ MR is as sensitive as CT in the hyperacute diagnosis of ICH^{26 30} but it rarely provides more information in the acute stage; the longer scan duration and delays obtaining MR for often critically ill patients make CT a preferred choice.

Blood tests including coagulation studies, glucose, cardiac-specific troponin and a toxicology screen should be performed. Point-of-care INR testing should be implemented to avoid delays in anticoagulation reversal for patients taking warfarin.³¹ ECG abnormalities are common, but concomitant myocardial injury should not be overlooked.³²

Do I need to request further imaging?

Early diagnosis of macrovascular causes of ICH allows timely starting of specific treatment and refines the prognosis. The decision whether to pursue further imaging has often been made based on assumptions guided

Table 1 Important information to obtain as soon as possible after ICH to guide prognostication and management

Question to ask	Rationale
<p><i>Is the patient taking anticoagulation or antiplatelet medications?</i></p> <p><i>Further details of antithrombotic treatment: what agent, what dose and when was the most recent dose (or the most recent International Normalised Ratio(INR) for warfarin)?</i></p>	<p>Anticoagulant and antiplatelet use are independent predictors of haematoma expansion¹¹ and death.¹²</p> <p>This is relevant to establish if anticoagulation reversal is needed, and if so, the type and dose of reversal agent to be used.</p>
<p><i>What was the time of onset of symptoms?</i></p>	<p>This is obviously crucial to determine in all stroke presentations, but is relevant in ICH as the time from symptom onset to baseline imaging relates inversely to the risk of haematoma expansion¹¹ and determines whether to pursue acute blood pressure lowering. Most expansion occurs in the first few hours after ICH.¹³ It is also important to establish whether the imaging appearances are consistent with the time of onset; a haematoma may appear isodense with brain tissue as early as five days after the onset, so the diagnosis may be missed if CT imaging is delayed.</p>
<p><i>Is the patient's blood pressure elevated (systolic blood pressure >150 mm Hg)?</i></p>	<p>Blood pressure is frequently very high in the acute phase.¹⁴ Elevated systolic blood pressure is associated with further neurological deterioration and mortality^{15 16} and early treatment may be beneficial, although there is much uncertainty about this.</p>
<p><i>Has ICH been distinguished from haemorrhagic transformation of ischaemic stroke?</i></p>	<p>ICH cannot always be definitely distinguished from haemorrhagic transformation of infarction on imaging.¹⁷ Features suggesting haemorrhagic transformation include a patchy rather than uniform appearance of the haematoma, hypodensity surrounding the haematoma that may reach the cortex in a wedge shape, and evidence of an occluded vessel visible in the same arterial territory.</p>
<p><i>Are there imaging or clinical signs of intraventricular extension of haemorrhage and hydrocephalus?</i></p>	<p>Intraventricular extension of haemorrhage and raised intracranial pressure (ICP) from hydrocephalus each predict higher mortality and poor functional outcome¹⁸ and require urgent consideration for surgical management (external ventricular drain insertion).</p>
<p><i>Are there imaging or clinical signs of mass effect and increased ICP?</i></p>	<p>Blood pressure targets may require revision if there are signs of elevated ICP, and hyperosmolar agents and ICP management may be indicated.^{19 20}</p>

ICH, intracerebral haemorrhage.

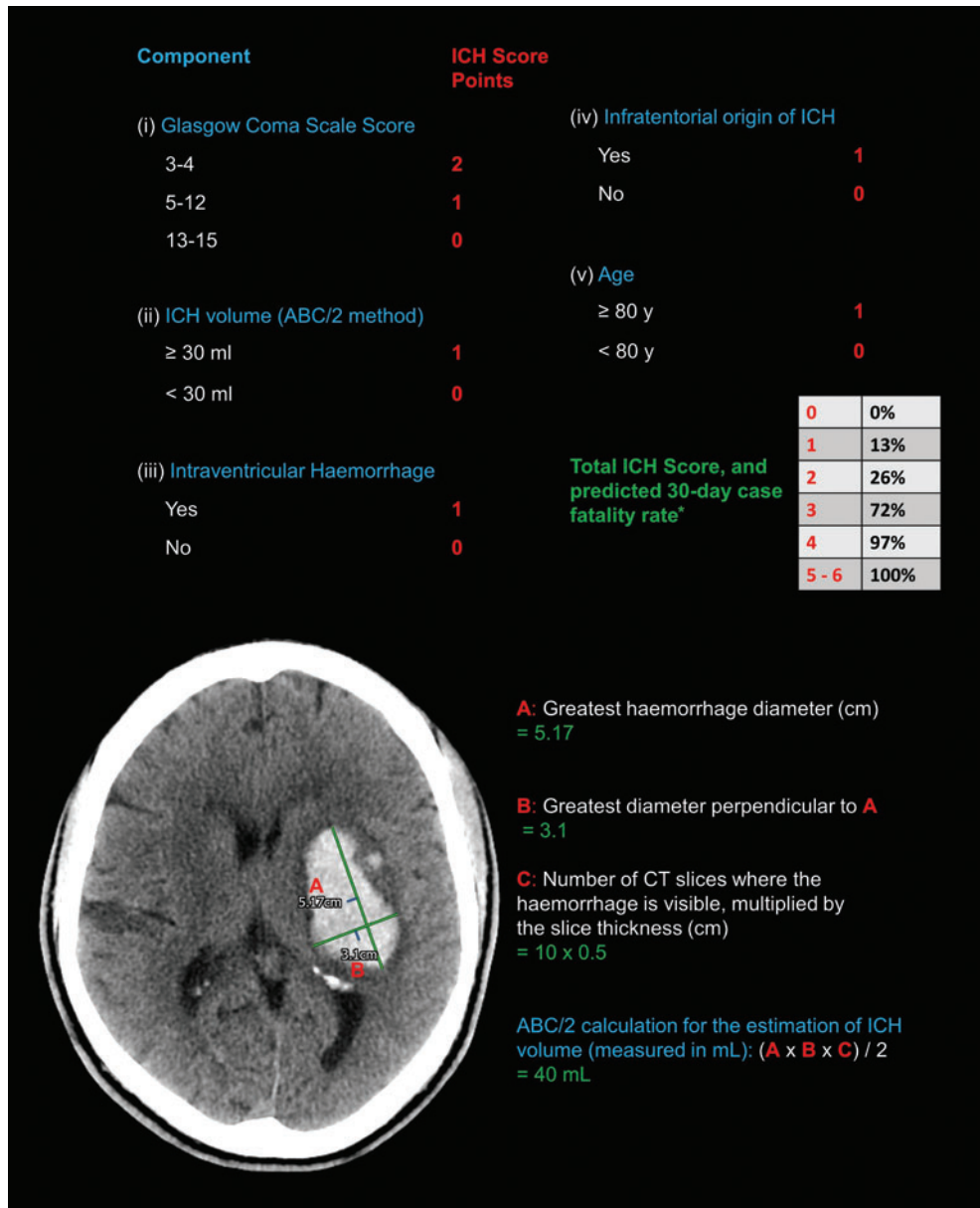


Figure 1 Upper panel: Calculation of the intracerebral haemorrhage score, a clinical grading scale and a useful communication tool. Predicted 30-day case-fatality rates are derived from the original validation study²²; *a subsequent study in which early do-not-resuscitate orders were not placed observed 30% lower mortality rates.²³ Lower panel: The use of the ABC/2 calculation (essentially the formula for the volume of an ellipsoid) to rapidly and accurately^{24 25} estimate the volume of an acute left-sided ganglio-capsular haemorrhage on non-contrast CT brain scan. (Copyright Iain McGurgan).

by patient risk factors, but these are not a reliable way to exclude a potential macrovascular cause in all cases, and clinical practice varies widely.³³

CT angiography (CTA) should be performed acutely in all patients, preferably within 2 days of the non-contrast brain CT,³⁴ except those definitely at low risk of having an underlying macrovascular cause (figure 3). Imaging predictors of haematoma expansion on CTA such as the 'spot sign' (foci of contrast extravasation within the haematoma) may also add prognostic value.^{11 35} If CTA is negative for structural vascular abnormalities, MR/MR angiography should be considered as soon as

possible as it has additional diagnostic yield.³⁴ Digital subtraction angiography is then warranted in patients at high risk of an underlying macrovascular cause after negative CTA (and negative MR, if performed).³⁴ There is an appreciable yield of repeat digital subtraction angiography performed a few weeks later, especially in lobar ICH,³⁶ so persistence is often required.

Beyond the acute phase, MR (including blood-sensitive sequences to detect cerebral microbleeds and cortical superficial siderosis) provides important additional information about the underlying cerebral small vessel disease.

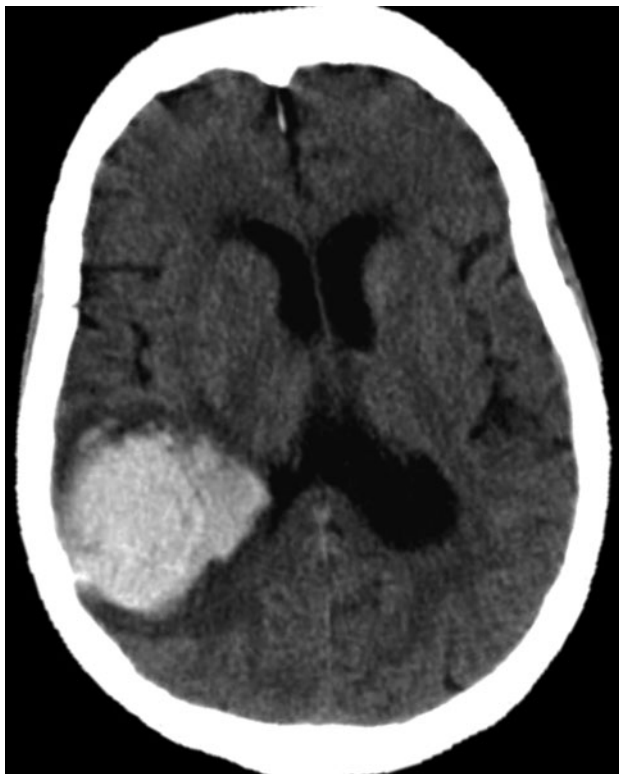

Figure 2 This axial non-contrast CT brain scan shows an acute large right parietal lobar haematoma, with moderately severe confluent low attenuation (leuкоaraiosis) extending from the lateral ventricles into the subcortical white matter. (Copyright David Werring.)

Should I pursue intensive treatment?

The focus for the great majority of patients should be on the full provision of high-quality active treatment and supportive care, at least in the first 24–48 hours. Decisions about instituting a ceiling of care should depend on an assessment of prognosis, but this is difficult to determine acutely. There are multiple dedicated ICH prognostic grading scales, the most widely used being the ICH score,²² which has acceptable discrimination for functional outcome measured by the modified Rankin score at up to 12 months (figure 1). Such scales should not be used, however, as the sole means to gauge prognosis or guide the withdrawal of supportive treatment.²¹

Like other conditions with high rates of poor outcomes and a perceived lack of effective treatments, ICH is vulnerable to therapeutic nihilism. Early ceilings of care and a focus on comfort measures are more likely to be pursued acutely in ICH than in ischaemic stroke, independent of neurological deterioration and comorbidities, and are associated with poorer outcome.⁴¹ While timely do-not-resuscitate orders are important considerations in stroke management, these should not influence other aspects of care. In practice, however, do-not-resuscitate orders in ICH often herald less active supportive care,^{42 43} so clinicians should be cautious when considering early do-not-resuscitate orders.

ACUTE MANAGEMENT

How do I approach the management of ICH?

ICH is a neurological emergency. The presence of expanding haematoma and vasogenic oedema inside the fixed volume of the cranial vault can lead to a precipitous increase in intracranial pressure (ICP) and fatal brain herniation syndromes. The principle of ‘time is brain’ also firmly applies to ICH; haematoma expansion occurs very early¹¹ and independently predicts a poor outcome.¹⁸ The rapid delivery of a care bundle incorporating anticoagulation reversal, intensive blood pressure management and neurosurgery/critical care if required has been associated with a substantial improvement in 30-day case-fatality rates.⁴⁴

The overarching goals of acute management are to stabilise the patient to ensure they survive the initial insult, and to prevent secondary brain injury (figure 4). Patients with ICH may require immediate intensive care unit admission. Otherwise, all patients should be admitted to an acute stroke unit as soon as possible; the benefit is at least as great for patients with ICH as it is for those with ischaemic stroke.⁴⁵ The general principles of acute care are the same as those for acute ischaemic stroke, as outlined in the first article in this series.¹⁰ Secondary prevention measures, cerebral small vessel disease and decisions regarding restarting antithrombotic therapy will be addressed in subsequent articles.

Management of the complications of ICH is a key focus of acute care. Raised ICP can result from the mass effect of the bleed or peri-haematoma oedema or from hydrocephalus. Although there is a lack of evidence to guide its management in ICH, measures used for raised ICP in other settings may help. These include raising the head of the bed to 30° (although without supportive evidence in acute stroke⁴⁶), mild sedation, analgesia and mannitol (or hypertonic saline, depending on cardiac and renal comorbidities).¹⁸ Intensive ICP monitoring is recommended in those with a GCS < 9, evidence of herniation or hydrocephalus.²¹ Corticosteroids are possibly associated with more harm than benefit when used for lowering ICP in ICH, so should not be used.⁴⁷ Early-onset seizures are not uncommon, occurring in one in seven patients, with most occurring at or near the onset.⁴⁸ Clinical seizures should be managed with antiseizure medications, but prophylactic treatment should not be offered routinely.²¹ Cortical involvement, age younger than 65 years, volume greater than 10 mL and early seizures within 7 days of ICH identify patients at higher risk of subsequent late seizure development.⁴⁹

If the patient takes anticoagulant treatment, how do I reverse it?

Anticoagulation-associated ICH accounts for nearly 20% of all cases.⁵⁰ The haemorrhage in this setting is of larger volume,^{51 52} is more likely to exhibit

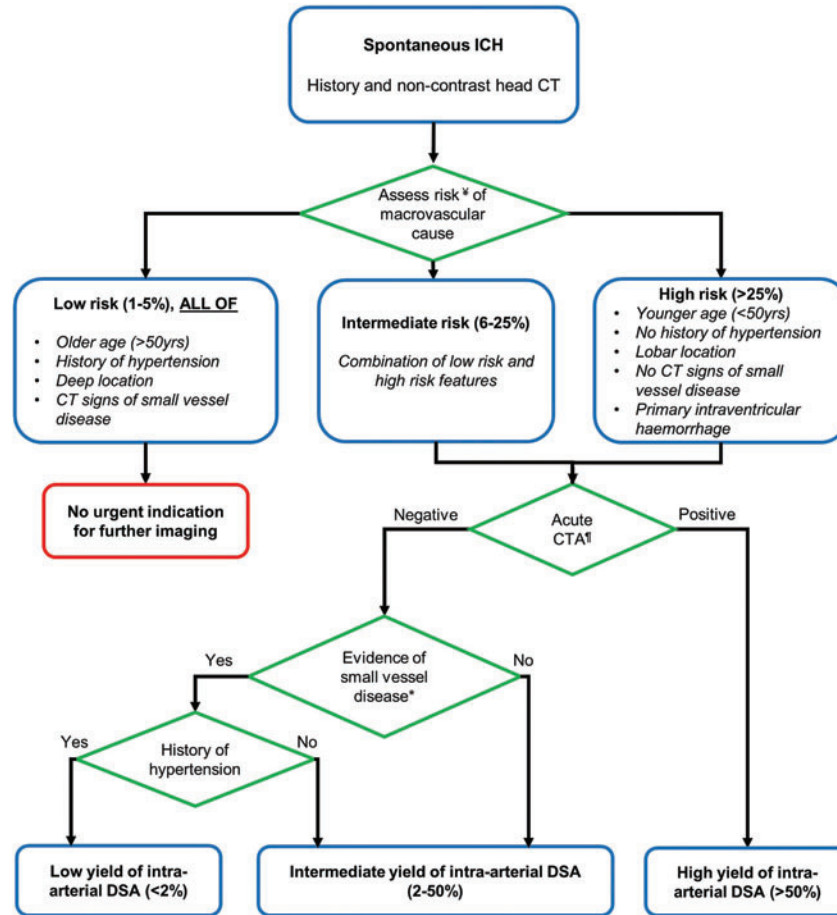


Figure 3 Algorithm with risk stratification to aid decision-making on further imaging, and the diagnostic yield of intra-arterial digital subtraction angiography in ICH. CTA, CT angiography; DSA, digital subtraction angiography; ICH, intracerebral haemorrhage. [‡]Parameters for pre-test risk estimation are derived from scoring systems based on patient characteristics and non-contrast CT from the Diagnostic AngioGRAphy to find vascular Malformations (DIAGRAM) study, a prospective, multicentre study assessing the accuracy of multiple imaging modalities in the diagnosis of macrovascular causes of ICH.^{34,37} Individuals meeting the 'low risk' criteria above were excluded from the DIAGRAM study because of the low probability of finding an underlying macrovascular cause,³⁸ and the yield of CTA in the remainder was 17%. Low rates of underlying macrovascular causes in this group were confirmed in a subsequent validation cohort.³⁷ Primary intraventricular haemorrhage (ie, that with no discernible parenchymal component) has been added to the high-risk group, based on high detected rates of underlying macrovascular causes.³⁹ [†]Acute CTA should be performed within 2 days of CT, where possible. The diagnostic algorithm of the yield of intra-arterial DSA based on the CTA and clinical characteristics has been adapted from Wilson *et al.*⁴⁰ MR/MR angiography performed acutely after a negative CTA may have additional value, particularly for the diagnosis of non-macrovascular causes, before considering intra-arterial DSA.³⁴ *Confluent leukoaraiosis (see figure 2) or lacunar infarction on acute CT brain scan.

haematoma expansion¹¹ and is associated with higher morbidity and mortality^{53–55} compared with ICH not associated with anticoagulation. Stopping antithrombotic therapy and reversing anticoagulation immediately after the diagnosis of ICH is, therefore, crucial.⁵⁶ Although ICH risk associated with the use of direct oral anticoagulants (DOACs) was around half that of warfarin in randomised trials,⁵⁷ a previous lack of specific reversal agents for DOACs prompted concerns that DOAC-associated ICH may be associated with poorer outcomes. In fact, the prognosis of ICH associated with DOACs is likely better⁵⁸ or at least no worse⁵⁹ than that of warfarin, and the availability of approved specific reversal agents for DOACs has improved. Table 2 provides a guide to the reversal of anticoagulation.

Poorer outcomes are also seen for ICH associated with antiplatelet therapy,⁷⁰ but platelet transfusions increase rather than decrease morbidity and mortality in this group,⁷¹ and therefore should not be used.

Patients with ICH in the context of coagulation factor deficiencies or thrombocytopenia should undergo replacement, with input from a haematologist.²¹ Several trials have assessed the efficacy of coagulation factors more generally in the management of acute ICH but found that the risk of thromboembolic complications outweighed the benefits.⁷² A trial of early administration of factor VIIa in an identified subgroup of patients most likely to benefit, however, has been approved (FASTEST, NCT03496883). Antifibrinolytic drugs, on the other hand, have

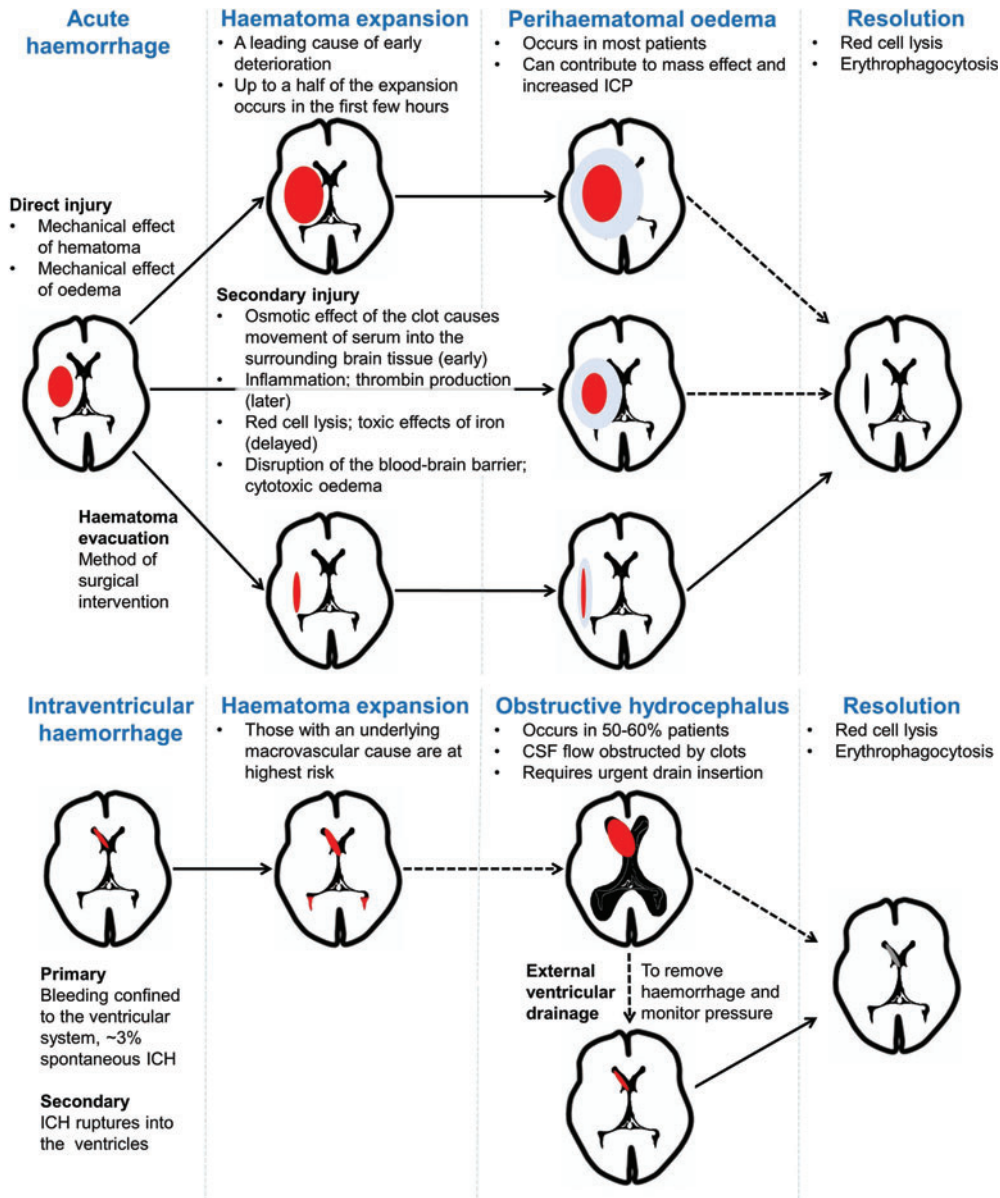


Figure 4 Schema of the time course and mechanisms of secondary brain injury in intracerebral haemorrhage, including intraventricular haemorrhage.

proven promising. A large trial of intravenous tranexamic acid (TICH-2) showed a significant reduction in haematoma growth and early mortality, but there was no overall benefit for the primary outcome of later functional recovery,⁷³ and it is thus not recommended as part of current care. A further study focusing on effects on early mortality and targeting earlier treatment is planned, and an ongoing trial is evaluating tranexamic acid in hyperacute presentations of ICH including mobile units (STOP-MSU, NCT03385928). Randomised evidence on associations of tranexamic acid in anticoagulation-associated ICH is lacking, although a trial in DOAC-associated ICH is currently underway (TICH-NOAC, NCT02866838).

Do I need to lower the patient’s blood pressure, and if so, by how much?

Observational data suggest that blood pressure is very high in the acute phase after ICH, significantly higher than that after ischaemic stroke.¹⁴ High blood pressure in acute ICH is associated with haematoma expansion and poor clinical outcome.^{15 16} There have been concerns for many years that high blood pressure may be necessary to ensure adequate cerebral perfusion after ICH, and that aggressively treating it may cause harm. Such concerns have been assuaged by evidence that suggests that adequate cerebral blood flow is maintained after acute blood pressure reduction in ICH.^{74 75} However, results of the two largest trials of intensive blood pressure lowering early after ICH^{76 77} have

Table 2 Strategies and rationale for anticoagulation reversal in acute ICH

Anticoagulant	Reversal strategy	Rationale
Warfarin	(1) Stop warfarin immediately and check the INR, but don't wait for the result to act in life-threatening bleeds. ^{60 61} (2) Vitamin K 10 mg intravenous infusion (slow-acting), monitor for anaphylaxis. (3) Four-factor prothrombin complex concentrate with INR-based dosing. (4) Repeat INR every 3–6 hours; the optimal target is uncertain, but aim for normalisation of the INR (<1.3).	Prothrombin complex concentrate is superior to fresh frozen plasma in normalising the INR for warfarin-associated ICH. ⁶² Vitamin K administration, in addition, may help to prevent a later re-increase in INR. ⁶³
Dabigatran	(1) Stop dabigatran immediately, check thrombin time, activated partial thromboplastin time. (2) Consider oral-activated charcoal (50 g) if last intake is <4 hours and safe to administer to the patient. (3) Idarucizumab 2×2.5 g boluses intravenously if recent ingestion or prolonged laboratory clotting times (not recommended if the thrombin time is within the normal range).	Idarucizumab, a humanised monoclonal antibody fragment, rapidly and safely reverses dabigatran anticoagulation. ⁶⁴ Effects on haematoma expansion are uncertain, as follow-up imaging was not mandated in the trial.
Factor Xa inhibitors (apixaban, rivaroxaban, edoxaban and betrixaban)	(1) Stop the agent immediately, check prothrombin time, anti-factor Xa activity. (2) Consider oral-activated charcoal (50 g) if last intake is <4 hours and safe to administer to the patient. (3) Andexanet alpha intravenous bolus and infusion, dosing dependent on the dose and last dose timing of the factor Xa inhibitor. (4) Most centres have protocols prescribing the use of andexanet alpha; prothrombin complex concentrate is still more often used in practice. ⁶⁵	Andexanet alpha, a recombinant inactive factor Xa 'decoy', rapidly and effectively reduces anti-factor Xa activity. ⁶⁶ A trial in ICH is ongoing. Given that clinical and cost-effectiveness has not yet been confirmed, a recent National Institute for Health and Care Excellence (NICE) guideline consultation has not recommended its use. ⁶⁷
Heparin	(1) Stop heparin infusion/low-molecular-weight heparin (LMWH) immediately, check activated partial thromboplastin time. (2) Protamine sulphate slow intravenous infusion, 1 mg per 100 units of heparin, if activated partial thromboplastin time is prolonged or heparin was administered within the previous 2 hours. (3) Max dose 50 mg, monitor for anaphylaxis.	Protamine sulphate fully reverses the effect of unfractionated heparin but only partly neutralises the effect of LMWH; the same dosing strategy can be used, but the longer half-life of LMWH may require cautious repeat infusions. ⁶⁸ Further evidence is needed to establish the role of andexanet alpha in the management of LMWH-associated ICH; trials are ongoing. ⁶⁹

ICH, intracerebral haemorrhage.

renewed uncertainty. Meta-analyses of these trials and other smaller studies showed that early intensive blood pressure lowering was safe, but without functional or mortality benefit.^{78–82} In contrast, a linear association between systolic blood pressure achieved in the first 24 hours and functional status was found in a recent individual participant data meta-analysis of the two largest trials, with improvements in functional recovery seen for blood pressure as low as 120–130 mm Hg.⁸³ These trials excluded patients with large and severe haematomas, however, so caution must be exercised when treating such patients, especially where large reductions in very hypertensive patients might predispose to harm.^{19 84} Table 3 provides some practical advice for blood pressure management in acute ICH, based on existing guidelines.⁸⁵ It should be noted that, in light of the uncertainty described above, future research might conclude that there is no benefit from acute intensive blood pressure lowering.

Which patients should I refer for neurosurgery?

The rationale for clot removal surgery is to reduce direct and secondary brain injury (figure 4). The

location of ICH has a large bearing on decision-making. Neurosurgical intervention is generally recommended for infratentorial bleeding despite a lack of randomised evidence,⁸⁸ given the high risk of brainstem compression and herniation syndromes in the confined space of the posterior fossa. Clinical guidelines recommend posterior fossa decompressive evacuation for cerebellar ICH >3 cm in diameter, or for smaller haematomas associated with brainstem compression or hydrocephalus from ventricular obstruction.²¹ This recommendation is based on observational evidence that haematoma evacuation is associated with decreased mortality, but there is no evidence for improvements in functional outcome.⁸⁹ Management of hydrocephalus by external ventricular drainage alone is not recommended in this setting and may be harmful, especially if the basal cisterns are compressed.⁹⁰ The lack of clinical equipoise probably precludes the design of any future randomised trials to address the question of surgical vs conservative management.

Equipoise exists in bounds, however, where supratentorial haemorrhage is concerned. Seventeen

HOW TO DO IT

Table 3 Strategies for blood pressure management in acute ICH based on the most recent UK^{85 86} and US²¹ ICH management guidelines. Blood pressure management strategies in rows 1–3 are relevant to patients presenting within 6 hours of symptom onset

Blood pressure management questions	Management strategy (for mild-to-moderate ICH)
What blood pressure warrants acute treatment?	Reduce blood pressure in people with acute ICH who have a blood pressure of 150–220 mm Hg with symptom onset within the last 6 hours.
What blood pressure should I target?	Aim for a systolic blood pressure of 130–140 mm Hg, sustained thereafter for at least a week.
How rapidly should I lower blood pressure?	In most cases, aim to achieve the target blood pressure within 1 hour of starting treatment. Rapid blood pressure lowering should be avoided if elevated ICP is suspected, the GCS is <6, or neurosurgical evacuation is pending.
What agents should I use?	Local protocols usually exist for guiding the choice of agent. Intravenous treatment (bolus or infusion) is generally warranted. Glyceryl trinitrate and labetalol are commonly used. Oral (or nasogastric) treatment should be started as soon as possible for maintenance treatment, and the intravenous therapy weaned and stopped within 2–3 days.
Should prehospital blood pressure treatment be advised?	Prehospital treatment with glyceryl trinitrate appeared to worsen outcome in a subgroup analysis of the RIGHT-2 trial, ⁸⁷ so ultra-acute treatment may be harmful and should not be used.

ICH, intracerebral haemorrhage; ICP, intracranial pressure; GCS, Glasgow Coma Scale.

Table 4 Summary of the evidence for different neurosurgical techniques in ICH

Surgical technique	Evidence
Open craniotomy	Craniotomy was the selected surgical management for most patients in the largest trials to date. ^{94 98} There was no benefit from early haematoma evacuation in either, but surgery was performed relatively late, and a marginal improvement in mortality was shown for those with superficial ICH without intraventricular extension.
Minimally invasive surgery (±clot lysis)	Minimally invasive surgical techniques incorporate removal of the haematoma in a single procedure using an endoscope or exoscope, or image-guided placement of a drainage catheter followed by catheter irrigation with a thrombolytic agent to allow passive drainage of the haematoma over several days. A variation, the minimally invasive craniopuncture technique, has been standard ICH surgical practice in China and improved independent survival in small basal ganglia ICH in a randomised trial. ⁹⁹ These techniques hold promise for the surgical management of deep bleeds, where access is limited or risky for open surgery, and recent meta-analyses demonstrated higher rates of good functional outcome than after medical management. ^{91 100}
External ventricular drainage (±clot lysis)	Intraventricular extension of haemorrhage occurs in 30–50% of patients with ICH, predisposes to the development of hydrocephalus and strongly predicts a poor prognosis. ¹⁸ Insertion of an external ventricular drain to remove haemorrhage and monitor pressure improves survival. ²¹ Functional outcome was not improved in the CLEAR III trial of alteplase versus saline irrigation in those with pre-placed drains. ¹⁰¹ A low proportion of participants in the trial achieved complete/near-complete clot removal, however, and functional benefit from removing greater amounts of haemorrhage volume remains a possibility.
Decompressive craniectomy	The aim of decompressive craniectomy is to mitigate the consequences of mass effect, in particular that of delayed oedema. Safety of the procedure and potential beneficial effects have been shown in retrospective studies and case series. ^{102–105} The first randomised controlled trial to compare the procedure to best medical treatment (SWITCH, NCT02258919) is currently underway.

ICH, intracerebral haemorrhage.

randomised controlled trials have addressed surgical evacuation of supratentorial ICH, with all of the larger trials and meta-analyses returning neutral results on the primary outcomes.⁹¹ As a result, best medical management is usually pursued, but trials were complicated by high crossover rates, and there appear to be subgroups of patients who might benefit from surgical intervention. Patients with a GCS at presentation of 10–13, that is, not at either extreme of arousal, those with large ICH and those with superficial bleeds may experience improved outcomes.^{92–94}

Multiple surgical techniques have been investigated for different indications; [table 4](#) provides a summary of the evidence for each. Developments in minimally invasive surgery for patients with supratentorial ICH are promising. The only large trial of catheter

evacuation followed by irrigation with alteplase (MISTIE III⁹⁵) found no clear benefit but noted that the procedure was safe. There was, however, evidence of functional improvement in patients meeting the surgical goal of reducing haematoma size to <15 mL.⁹⁶ The ongoing ENRICH trial (NCT02880878) is investigating a novel minimally invasive technique involving a small-directed craniotomy and image-guided trans-sulcal evacuation⁹⁷ and is one of several currently enrolling trials, some with an earlier time window for surgery (Dutch ICH Surgery Trial, NCT03608423; MIND, NCT03342664; INVEST, NCT02654015).

Optimal timing of surgical intervention remains controversial due to the risk of re-bleeding, although reducing haematoma volume early may

reduce secondary brain injury and could improve outcome.^{91 100}

FUTURE DIRECTIONS

The management of ICH has not paralleled the dramatic advances in acute ischaemic stroke therapeutics driven by many large randomised controlled trials. Clinical trials in ICH face unique challenges; a less common and more severe on average condition with poorly understood pathophysiology results in a sizeable proportion of patients being ineligible.¹⁰⁶ Aspiring to recruit every ICH survivor to at least one trial is the only way to resolve uncertainties and improve outcome. Fortunately, we have much about which to be optimistic. There are currently over 60 active recruiting (or soon-to-be recruiting) ICH trials, many focused on the possible interventions of haemostatic agents and surgical techniques, where much uncertainty persists.

CONCLUSION

ICH has the worst outcomes of all stroke subtypes, but increased research interest in recent years has led to significant advances in its diagnosis and management. The focus of existing treatment is the prevention of haematoma expansion, and progress in supportive care, blood pressure control and anticoagulation reversal has been rewarded with improved outcome. The role of neurosurgery is still unclear but the field is rapidly evolving, with minimally invasive techniques showing promise in selected groups, even in the context of neutral trials so far.

Key points

- ▶ Intracerebral haemorrhage is a medical emergency; its rapid diagnosis, investigation and treatment should prevent further brain injury and improve outcome.
- ▶ Although 30-day case fatality is ~40%, full supportive care should be considered for at least the first 24–48 hours, as prognostication can be difficult.
- ▶ Hyper-acute interventions such as anticoagulation reversal, blood pressure lowering and neurosurgery may improve recovery, but many uncertainties remain.
- ▶ Clinical trials based on pathophysiological knowledge and embedded in routine clinical practice are the main hope for its better management.

FURTHER READING

1. Cordonnier C, Demchuk A, Ziai W, Anderson CS. Intracerebral haemorrhage: current approaches to acute management. *Lancet*. 2018;392(10 154):1257–1268.
2. Balami JS, Buchan AM. Complications of intracerebral haemorrhage. *The Lancet Neurology*. 2012;11(1):101–18.

Contributors IJMG drafted the manuscript. The other authors revised the manuscript.

Funding The authors have not declared a specific grant for this research from any funding agency in the public, commercial or not-for-profit sectors.

Competing interests None declared.

Patient consent for publication Not required.

Provenance and peer review Commissioned. Externally peer-reviewed by Anthony Pereira, London, UK.

Open access This is an open access article distributed in accordance with the Creative Commons Attribution Non Commercial (CC BY-NC 4.0) license, which permits others to distribute, remix, adapt, build upon this work non-commercially, and license their derivative works on different terms, provided the original work is properly cited, appropriate credit is given, any changes made indicated, and the use is non-commercial. See: <http://creativecommons.org/licenses/by-nc/4.0/>.

ORCID iD

Iain J McGurgan <http://orcid.org/0000-0001-8457-1748>

REFERENCES

- 1 Feigin VL, Lawes CM, Bennett DA, *et al*. Worldwide stroke incidence and early case fatality reported in 56 population-based studies: a systematic review. *Lancet Neurol* 2009;8:355–69.
- 2 van Asch CJ, Luitse MJ, Rinkel GJ, *et al*. Incidence, case fatality, and functional outcome of intracerebral haemorrhage over time, according to age, sex, and ethnic origin: a systematic review and meta-analysis. *Lancet Neurol* 2010;9:167–76.
- 3 Krishnamurthi RV, Ikeda T, Feigin VL. Global, regional and country-specific burden of ischaemic stroke, intracerebral haemorrhage and subarachnoid haemorrhage: a systematic analysis of the global burden of disease study 2017. *Neuroepidemiology* 2020;54:171–9.
- 4 Béjot Y, Grelat M, Delpont B, *et al*. Temporal trends in early case-fatality rates in patients with intracerebral hemorrhage. *Neurology* 2017;88:985–90.
- 5 Jolink WMT, Klijn CJM, Brouwers PJAM, *et al*. Time trends in incidence, case fatality, and mortality of intracerebral hemorrhage. *Neurology* 2015;85:1318–24.
- 6 Li L, Luengo-Fernandez R, Zuurbier SM, *et al*. Ten-year risks of recurrent stroke, disability, dementia and cost in relation to site of primary intracerebral haemorrhage: population-based study. *J Neurol Neurosurg Psychiatry* 2020; jnnp-2019-32266.
- 7 Poon MT, Fonville AF, Al-Shahi Salman R. Long-term prognosis after intracerebral haemorrhage: systematic review and meta-analysis. *J Neurol Neurosurg Psychiatry* 2014;85:660–7.
- 8 Al-Shahi R. A systematic review of the frequency and prognosis of arteriovenous malformations of the brain in adults. *Brain* 2001;124:1900–26.
- 9 Rodrigues MA, Samarasekera N, Lerpiniere C, *et al*. The Edinburgh CT and genetic diagnostic criteria for lobar intracerebral haemorrhage associated with cerebral amyloid angiopathy: model development and diagnostic test accuracy study. *Lancet Neurol* 2018;17:232–40.
- 10 Hurford R, Sekhar A, Hughes TAT, *et al*. Diagnosis and management of acute ischaemic stroke. *Pract Neurol* 2020; practneurol-2020-002557.
- 11 Al-Shahi Salman R, Frantzas J, Lee RJ, *et al*. Absolute risk and predictors of the growth of acute spontaneous intracerebral haemorrhage: a systematic review and meta-analysis of individual patient data. *Lancet Neurol* 2018;17:885–94.

- 12 Rosand J, Eckman MH, Knudsen KA, *et al.* The effect of warfarin and intensity of anticoagulation on outcome of intracerebral hemorrhage. *Arch Intern Med* 2004;164:880–4.
- 13 Brott T, Broderick J, Kothari R, *et al.* Early hemorrhage growth in patients with intracerebral hemorrhage. *Stroke* 1997;28:1–5.
- 14 Fischer U, Cooney MT, Bull LM, *et al.* Acute post-stroke blood pressure relative to premorbid levels in intracerebral haemorrhage versus major ischaemic stroke: a population-based study. *Lancet Neurol* 2014;13:374–84.
- 15 Rodriguez-Luna D, Pineiro S, Rubiera M, *et al.* Impact of blood pressure changes and course on hematoma growth in acute intracerebral hemorrhage. *Eur J Neurol* 2013;20:1277–83.
- 16 Sakamoto Y, Koga M, Yamagami H, *et al.* Systolic blood pressure after intravenous antihypertensive treatment and clinical outcomes in hyperacute intracerebral hemorrhage. *Stroke* 2013;44:1846–51.
- 17 Lovelock C E, Philip Anslow J, Molyneux A, *et al.* Substantial observer variability in the differentiation between primary intracerebral hemorrhage and hemorrhagic transformation of infarction on CT brain imaging. *Stroke* 2009;40:3763–7.
- 18 Balami JS, Buchan AM. Complications of intracerebral haemorrhage. *Lancet Neurol* 2012;11:101–18.
- 19 Divani A A, Liu X, Petersen A, *et al.* The magnitude of blood pressure reduction predicts poor in-hospital outcome in acute intracerebral hemorrhage. *Neurocrit Care* 2020;33:389–98.
- 20 Ziai WC, Thompson CB, Mayo S, *et al.* Intracranial hypertension and cerebral perfusion pressure insults in adult hypertensive intraventricular hemorrhage: occurrence and associations with outcome. *Crit Care Med* 2019;47:1125–34.
- 21 Hemphill JC 3rd, Greenberg SM, Anderson CS, *et al.* Guidelines for the management of spontaneous intracerebral hemorrhage: a guideline for healthcare professionals from the American Heart Association/American Stroke Association. *Stroke* 2015;46:2032–60.
- 22 Hemphill JC 3rd, Bonovich DC, Besmertis L, *et al.* The ICH score: a simple, reliable grading scale for intracerebral hemorrhage. *Stroke* 2001;32:891–7.
- 23 Morgenstern L B, Zahuranec D B, Sanchez B N, *et al.* Full medical support for intracerebral hemorrhage. *Neurology* 2015;84:1739–44.
- 24 Kothari RU, Brott T, Broderick JP, *et al.* The ABCs of measuring intracerebral hemorrhage volumes. *Stroke* 1996;27:1304–5.
- 25 Webb AJS, Ullman NL, Morgan TC, *et al.* Accuracy of the ABC/2 score for intracerebral hemorrhage. *Stroke* 2015;46:2470–6.
- 26 Chalela J A, Kidwell C S, Nentwich L M, *et al.* Magnetic resonance imaging and computed tomography in emergency assessment of patients with suspected acute stroke: a prospective comparison. *Lancet* 2007;369:293–8.
- 27 Brazzelli M, Ag Sandercock P, Chappell F M, *et al.* Magnetic resonance imaging versus computed tomography for detection of acute vascular lesions in patients presenting with stroke symptoms. *Cochrane Database Sys Rev* 2009.
- 28 Broderick JP, Brott TG, Duldner JE, *et al.* Volume of intracerebral hemorrhage. A powerful and easy-to-use predictor of 30-day mortality. *Stroke* 1993;24:987–93.
- 29 Pfleger MJ, Hardee EP, Contant CF Jr., *et al.* Sensitivity and specificity of fluid-blood levels for coagulopathy in acute intracerebral hematomas. *AJNR Am J Neuroradiol* 1994;15:217–23. Available <https://pubmed.ncbi.nlm.nih.gov/8192064/>
- 30 Macellari F, Paciaroni M, Agnelli G, *et al.* Neuroimaging in intracerebral hemorrhage. *Stroke* 2014;45:903–8.
- 31 Parry-Jones A. Cutting delays in reversing anticoagulation after intracerebral haemorrhage: three key changes at a UK comprehensive stroke centre. *BMJ Qual Improv Rep* 2015;4:u208763.w3521.
- 32 Hasegawa K, Fix ML, Wendell L, *et al.* Ischemic-appearing electrocardiographic changes predict myocardial injury in patients with intracerebral hemorrhage. *Am J Emerg Med* 2012;30:545–52.
- 33 Cordonnier C, Klijn CJM, Van Beijnum J, *et al.* Radiological investigation of spontaneous intracerebral hemorrhage. *Stroke* 2010;41:685–90.
- 34 van Asch CJ, Velthuis BK, Rinkel GJ, *et al.* Diagnostic yield and accuracy of CT angiography, MR angiography, and digital subtraction angiography for detection of macrovascular causes of intracerebral haemorrhage: prospective, multicentre cohort study. *BMJ* 2015;351:h5762.
- 35 Demchuk AM, Dowlatsahi D, Rodriguez-Luna D, *et al.* Prediction of haematoma growth and outcome in patients with intracerebral haemorrhage using the CT-angiography spot sign (PREDICT): a prospective observational study. *Lancet Neurol* 2012;11:307–14.
- 36 Hino A, Fujimoto M, Yamaki T, *et al.* Value of repeat angiography in patients with spontaneous subcortical hemorrhage. *Stroke* 1998;29:2517–21.
- 37 Hilken NA, van Asch CJJ, Werring DJ, *et al.* Predicting the presence of macrovascular causes in non-traumatic intracerebral haemorrhage: the DIAGRAM prediction score. *J Neurol Neurosurg Psychiatry* 2018;89:674–9.
- 38 Zhu XL, Chan MSY, Poon WS. Spontaneous Intracranial hemorrhage: which patients need diagnostic cerebral angiography?. *Stroke* 1997;28:1406–9.
- 39 Fam M D, Alice Pang A, Zeineddine H, *et al.* Demographic risk factors for vascular lesions as etiology of intraventricular hemorrhage in prospectively screened cases. *Cerebrovasc Dis* 2017;43:223–30.
- 40 Wilson D, Ogungbemi A, Ambler G, *et al.* Developing an algorithm to identify patients with intracerebral haemorrhage secondary to a macrovascular cause. *Eur Stroke J* 2017;2:369–76.
- 41 Parry-Jones AR, Paley L, Bray BD, *et al.* Care-limiting decisions in acute stroke and association with survival: analyses of UK national quality register data. *Int J Stroke* 2016;11:321–31.
- 42 Silvennoinen K, Meretoja A, Strbian D, *et al.* Do-not-resuscitate (DNR) orders in patients with intracerebral hemorrhage. *Int J Stroke: Off J Int Stroke Soc* 2014;9:53–8.
- 43 Zahuranec DB, Morgenstern LB, Sanchez BN, *et al.* Do-not-resuscitate orders and predictive models after intracerebral hemorrhage. *Neurology* 2010;75:626–33.
- 44 Parry-Jones AR, Sammut-Powell C, Paroutoglou K, *et al.* An intracerebral hemorrhage care bundle is associated with lower case fatality. *Ann Neurol* 2019;86:495–503.
- 45 Langhorne P, Fearon P, Ronning OM, *et al.* Stroke unit care benefits patients with intracerebral hemorrhage: systematic review and meta-analysis. *Stroke* 2013;44:3044–9.
- 46 Anderson C S, Arima H, Lavados P, *et al.* Cluster-randomized, crossover trial of head positioning in acute stroke. *N Engl J Med* 2017;376:2437–47.
- 47 Feigin VL, Anderson N, Rinkel GJ, *et al.* Corticosteroids for aneurysmal subarachnoid haemorrhage and primary

- intracerebral haemorrhage. *Cochrane Database Syst Rev* 2005;Cd004583.
- 48 Herdt VD, Dumont F, Henon H, *et al.* Early seizures in intracerebral hemorrhage: incidence, associated factors, and outcome. *Neurology* 2011;77:1794–800.
 - 49 Haapaniemi E, Strbian D, Rossi C, *et al.* The CAVE score for predicting late seizures after intracerebral hemorrhage. *Stroke* 2014;45:1971–6.
 - 50 Flaherty ML. Anticoagulant-associated intracerebral hemorrhage. *Semin Neurol* ; 30: 565–72.
 - 51 Flaherty ML, Tao H, Haverbusch M, *et al.* Warfarin use leads to larger intracerebral hematomas. *Neurology* 2008;71:1084–9.
 - 52 Dequatre-Ponchelle N, Hénon H, Pasquini M, *et al.* Vitamin K antagonists: associated cerebral hemorrhages. *Stroke* 2013;44:350–5.
 - 53 Cucchiara B, Messe S, Sansing L, *et al.* Hematoma growth in oral anticoagulant related intracerebral hemorrhage. *Stroke* 2008;39:2993–6.
 - 54 Bower MM, Sweidan AJ, Shafie M, *et al.* Contemporary reversal of oral anticoagulation in intracerebral hemorrhage. *Stroke* 2019;50:529–36.
 - 55 Dowlatshahi D, Butcher KS, Asdaghi N, *et al.* Poor prognosis in warfarin-associated intracranial hemorrhage despite anticoagulation reversal. *Stroke* 2012;43:1812–17.
 - 56 Kuramatsu J B, Gerner S T, Schellinger P D, *et al.* Anticoagulant reversal, blood pressure levels, and anticoagulant resumption in patients with anticoagulation-related intracerebral hemorrhage. *JAMA* 2015;313:824.
 - 57 Ruff CT, Giugliano RP, Braunwald E, *et al.* Comparison of the efficacy and safety of new oral anticoagulants with warfarin in patients with atrial fibrillation: a meta-analysis of randomised trials. *Lancet* 2014;383:955–62.
 - 58 Inohara T, Xian Y, Liang L, *et al.* Association of intracerebral hemorrhage among patients taking non-vitamin K antagonist vs vitamin K antagonist oral anticoagulants with in-hospital mortality. *JAMA* 2018;319:463.
 - 59 Wilson D, Seiffge DJ, Traenka C, *et al.* Outcome of intracerebral hemorrhage associated with different oral anticoagulants. *Neurology* 2017;88:1693–700.
 - 60 Keeling D, Baglin T, Tait C, *et al.* Guidelines on oral anticoagulation with warfarin: fourth edition. *Br J Haematol* 2011;154:311–24.
 - 61 Witt DM, Nieuwlaat R, Clark NP, *et al.* American society of hematology 2018 guidelines for management of venous thromboembolism: optimal management of anticoagulation therapy. *Blood Adv* 2018;2:3257–91.
 - 62 Steiner T, Poli S, Griebel M, *et al.* Fresh frozen plasma versus prothrombin complex concentrate in patients with intracranial haemorrhage related to vitamin K antagonists (INCH): a randomised trial. *Lancet Neurol* 2016;15:566–73.
 - 63 Yasaka M, Sakata T, Minematsu K, *et al.* Correction of INR by prothrombin complex concentrate and vitamin K in patients with warfarin related hemorrhagic complication. *Thromb Res* 2002;108:25–30.
 - 64 Pollack CV, Reilly PA, Van Ryn J, *et al.* Idarucizumab for dabigatran reversal: full cohort analysis. *N Engl J Med* 2017;377:431–41.
 - 65 Kuramatsu JB, Sembill JA, Huttner HB. Reversal of oral anticoagulation in patients with acute intracerebral hemorrhage. *Crit Care* 2019;23:1.
 - 66 Connolly SJ, Crowther M, Eikelboom JW, *et al.* Full study report of Andexanet Alfa for bleeding associated with factor Xa inhibitors. *N Engl J Med* 2019;380:1326–35.
 - 67 National Institute for Health and Care Excellence (NICE). NICE []. 2020. <https://www.nice.org.uk/consultations/891/1/recommendations>
 - 68 Schulman S, Bijsterveld NR. Anticoagulants and their reversal. *Transfus Med Rev* 2007;21:37–48.
 - 69 Carpenter E, Singh D, Dietrich E, *et al.* Andexanet alfa for reversal of factor Xa inhibitor-associated anticoagulation. *Ther Adv Drug Saf* 2019;10:204209861988813.
 - 70 Thompson BB, Bejot Y, Caso V, *et al.* Prior antiplatelet therapy and outcome following intracerebral hemorrhage: a systematic review. *Neurology* 2010;75:1333–42.
 - 71 Baharoglu MI, Cordonnier C, Al-Shahi Salman R, *et al.* Platelet transfusion versus standard care after acute stroke due to spontaneous cerebral haemorrhage associated with antiplatelet therapy (PATCH): a randomised, open-label, phase 3 trial. *Lancet (London, England)* 2016;387:2605–13.
 - 72 Al-Shahi Salman R, Law ZK, Bath PM, *et al.* Haemostatic therapies for acute spontaneous intracerebral haemorrhage. *Cochrane Database Syst Rev* 2018;4:Cd005951.
 - 73 Sprigg N, Flaherty K, Appleton JP, *et al.* Tranexamic acid for hyperacute primary intracerebral haemorrhage (TICH-2): an international randomised, placebo-controlled, phase 3 superiority trial. *Lancet* 2107–15.
 - 74 Butcher KS, Jeerakathil T, Hill M, *et al.* The intracerebral hemorrhage acutely decreasing arterial pressure trial. *Stroke* 2013;44:620–6.
 - 75 Gould B, McCourt R, Asdaghi N, *et al.* Autoregulation of cerebral blood flow is preserved in primary intracerebral hemorrhage. *Stroke* 2013;44:1726–8.
 - 76 Anderson CS, Heeley E, Huang Y, *et al.* Rapid blood-pressure lowering in patients with acute intracerebral hemorrhage. *N Engl J Med* 2013;368:2355–65.
 - 77 Qureshi AI, Palesch YY, Barsan WG, *et al.* Intensive blood-pressure lowering in patients with acute cerebral hemorrhage. *N Engl J Med* 2016;375:1033–43.
 - 78 Boulouis G, Morotti A, Goldstein JN, *et al.* Intensive blood pressure lowering in patients with acute intracerebral haemorrhage: clinical outcomes and haemorrhage expansion. Systematic review and meta-analysis of randomised trials. *J Neurol Neurosurg Psychiatry* 2017;88:339–45.
 - 79 Tsvigoulis G, Katsanos AH, Butcher KS, *et al.* Intensive blood pressure reduction in acute intracerebral hemorrhage. *A Meta-anal* 2014;83:1523–9.
 - 80 Gong S, Lin C, Zhang D, *et al.* Effects of intensive blood pressure reduction on acute intracerebral hemorrhage: a systematic review and meta-analysis. *Sci Rep* 2017;7:1–9.
 - 81 Lattanzi S, Cagnetti C, Provinciali L, *et al.* How should we lower blood pressure after cerebral hemorrhage? A systematic review and meta-analysis. *Cerebrovasc Dis* 2017;43:207–13.
 - 82 Shi L, Xu S, Zheng J, *et al.* Blood pressure management for acute intracerebral hemorrhage: a meta-analysis. *Sci Rep* 2017;7:1–8.
 - 83 Moullaali TJ, Wang X, Martin RH, *et al.* Blood pressure control and clinical outcomes in acute intracerebral haemorrhage: a preplanned pooled analysis of individual participant data. *Lancet Neurol* 2019;18:857–64.
 - 84 Qureshi AI, Huang W, Lobanova I, *et al.* Outcomes of intensive systolic blood pressure reduction in patients with intracerebral hemorrhage and excessively high initial systolic blood pressure. *JAMA Neurol* 2020.

- 85 National Institute for Health and Care Excellence (NICE). NICE guideline [NG128] stroke and transient ischaemic attack in over 16s: diagnosis and initial management. NICE 2019. Available <https://www.nice.org.uk/guidance/ng128> (accessed 13 Aug 2020).
- 86 Rudd AG, Bowen A, Young G, *et al*. National clinical guideline for stroke: 5th edition 2016. *Clin Med (Northfield Il)* 2017. Available [https://www.strokeaudit.org/SupportFiles/Documents/Guidelines/2016-National-Clinical-Guideline-for-Stroke-5t-\(1\).aspx](https://www.strokeaudit.org/SupportFiles/Documents/Guidelines/2016-National-Clinical-Guideline-for-Stroke-5t-(1).aspx) (accessed 13 Aug 2020).
- 87 Bath PM, Woodhouse LJ, Krishnan K, *et al*. Prehospital transdermal glyceryl trinitrate for ultra-acute intracerebral hemorrhage. *Stroke* 2019;50:3064–71.
- 88 Cordonnier C, Demchuk A, Ziai W, *et al*. Intracerebral haemorrhage: current approaches to acute management. *Lancet (London, England)* 2018;392:1257–68.
- 89 Kuramatsu JB, Biffi A, Gerner ST, *et al*. Association of surgical hematoma evacuation vs conservative treatment with functional outcome in patients with cerebellar intracerebral hemorrhage. *JAMA* 2019;322:1392.
- 90 Loon JV, Calenbergh FV, Coffin J, *et al*. Controversies in the management of spontaneous cerebellar haemorrhage a consecutive series of 49 cases and review of the literature. *Acta Neurochir (Wien)* 1993;122:187–93.
- 91 Lotte Sondag M, Schreuder FHB, Boogaarts H D, *et al*. Neurosurgical intervention for supratentorial intracerebral hemorrhage. *Ann Neurol* 2020.
- 92 Gregson BA, Broderick JP, Auer LM, *et al*. Individual patient data subgroup meta-analysis of surgery for spontaneous supratentorial intracerebral hemorrhage. *Stroke* 2012;43:1496–504.
- 93 Gregson BA, Mitchell P, Mendelow AD. Surgical decision making in brain hemorrhage. *Stroke* 2019;50:1108–15.
- 94 Mendelow AD, Gregson BA, Rowan EN, *et al*. Early surgery versus initial conservative treatment in patients with spontaneous supratentorial lobar intracerebral haematomas (STICH II): a randomised trial. *Lancet (London, England)* 2013;382:397–408.
- 95 Hanley DF, Thompson RE, Rosenblum M, *et al*. Efficacy and safety of minimally invasive surgery with thrombolysis in intracerebral haemorrhage evacuation (MISTIE III): a randomised, controlled, open-label, blinded endpoint phase 3 trial. *Lancet* 2019;393:1021–32.
- 96 Awad IA, Polster SP, Carrión-Penagos J, *et al*. Surgical performance determines functional outcome benefit in the minimally invasive surgery plus recombinant tissue plasminogen activator for intracerebral hemorrhage evacuation (MISTIE) procedure. *Neurosurgery* 2019;84:1157–68.
- 97 Labib MA, Shah M, Kassam AB, *et al*. The safety and feasibility of image-guided brainpath-mediated transsulcal hematoma evacuation: a multicenter study. *Neurosurgery* 2017;80:515–24.
- 98 Mendelow AD, Gregson BA, Fernandes HM, *et al*. Early surgery versus initial conservative treatment in patients with spontaneous supratentorial intracerebral haematomas in the international surgical trial in intracerebral haemorrhage (STICH): a randomised trial. *Lancet (London, England)* 2005;365:387–97.
- 99 Wang W-Z, Jiang B, Liu GM, *et al*. Minimally invasive craniopuncture therapy vs. conservative treatment for spontaneous intracerebral hemorrhage: results from a randomized clinical trial in China. *Int J* 2009;4:11–16.
- 100 Scaggiante J, Zhang X, Mocco J, *et al*. Minimally invasive surgery for intracerebral hemorrhage. *Stroke* 2018;49:2612–20.
- 101 Hanley DF, Lane K, McBee N, *et al*. Thrombolytic removal of intraventricular haemorrhage in treatment of severe stroke: results of the randomised, multicentre, multiregion, placebo-controlled CLEAR III trial. *Lancet* 2017;389:603–11.
- 102 Esquenazi Y, Savitz SI, El Khoury R, *et al*. Decompressive hemicraniectomy with or without clot evacuation for large spontaneous supratentorial intracerebral hemorrhages. *Clin Neurol Neurosurg* 2015;128:117–22.
- 103 Fung C, Murek M, Klinger-Gratz PP, *et al*. Effect of decompressive craniectomy on perihematomal edema in patients with intracerebral hemorrhage. *PLoS One* 2016;11:e0149169.
- 104 Murthy JM, Chowdary GV, Murthy TV, *et al*. Decompressive craniectomy with clot evacuation in large hemispheric hypertensive intracerebral hemorrhage. *Neurocrit Care* 2005;2:258–62.
- 105 Ramnarayan R, Anto D, Anilkumar TV, *et al*. Decompressive hemicraniectomy in large putaminal hematomas: an Indian experience. *J Stroke Cerebrovasc Dis* 2009;18:1–10.
- 106 Hansen B M, Ullman N, Bo Norrving F, *et al*. Applicability of clinical trials in an unselected cohort of patients with intracerebral hemorrhage. *Stroke* 2016;47:2634–7.