


Complications and outcome of cats with congenital extrahepatic portosystemic shunts treated with thin film: Thirty-four cases (2008-2017)

Paula Valiente¹  | Mary Trehy² | Rob White³ | Pieter Nelissen⁴ | Jackie Demetriou¹ | Giacomo Stanzani⁵ | Benito de la Puerta²

¹Dick White Referrals, Cambridgeshire, United Kingdom

²North Downs Specialist Referrals, Bletchingley, United Kingdom

³School of Veterinary Medicine and Science, University of Nottingham, Leicestershire, United Kingdom

⁴Tierklinik Haar, Haar, Germany

⁵Division of Medicine, Bloomsbury Institute for Intensive Care Medicine, University College London, London, United Kingdom

Correspondence

Paula Valiente, Dick White Referrals, Station Farm, London Road, Six Mile Bottom, Cambridgeshire, CB8 0UH, United Kingdom. Email: pvd@dwr.co.uk

Abstract

Background: Congenital extrahepatic portosystemic shunts (CEHPSS) are rare in cats. Outcome after attenuation of CEHPSS with thin film has been described in a small number of cases.

Objectives: To describe the clinical presentation, postoperative complications, and outcome of cats treated with thin film to attenuate CEHPSS.

Animals: Thirty-four cats with CEHPSS were identified from the database of 3 institutions over 9 years.

Methods: Retrospective study. Medical records were reviewed to identify cats with a diagnosis of a CEHPSS that underwent surgical attenuation. Congenital extrahepatic portosystemic shunts were suspected from clinical signs, clinicopathologic findings, and diagnostic imaging, and confirmed at exploratory laparotomy. Cats treated with thin film band attenuation were included. Postoperative complications and follow-up were recorded.

Results: Complications were recorded in 11 of 34 cats. Deaths related to CEHPSS occurred in 6 of 34; 4 cats did not survive to discharge. Persistent seizures were the cause of death in 4 cats. Seizures were recorded in 8 of 34 cats after surgery; all these cats received preoperative antiepileptic drugs. Serum bile acid concentrations normalized in 25 of 28 of the cats for which data was available. Three cats had persistently increased serum bile acid concentrations and underwent a second exploratory laparotomy. One had a patent shunt, the other 2 had multiple acquired portosystemic shunts. Median follow-up was 8 months (0.5-84 months).

Conclusions and Clinical Importance: Congenital extrahepatic portosystemic shunts attenuation using thin film in cats carries a good short- and mid-term prognosis if they survive the postoperative period. Seizures were the most common cause of death.

KEYWORDS

bile acids, feline, seizures, shunt closure, thin film

Abbreviations: CEHPSS, congenital extrahepatic portosystemic shunts; CPSS, congenital portosystemic shunt.

This is an open access article under the terms of the Creative Commons Attribution-NonCommercial License, which permits use, distribution and reproduction in any medium, provided the original work is properly cited and is not used for commercial purposes.

© 2019 The Authors. *Journal of Veterinary Internal Medicine* published by Wiley Periodicals, Inc. on behalf of the American College of Veterinary Internal Medicine.

1 | INTRODUCTION

A congenital portosystemic shunt (CPSS) is an abnormal vascular communication between the portal and systemic venous circulatory system diverting portal blood away from the liver.¹⁻⁹ A CPSS can be an extrahepatic or intrahepatic vessel.¹⁰ Congenital extrahepatic portosystemic shunts (CEHPSS) are the most common shunts in cats.^{7,11,12}

Medical management of CPSS is aimed at treating clinical signs of hepatic encephalopathy without shunt correction.¹⁰ Surgical treatment allows for shunt closure¹³ and is the treatment of choice for most cats with CPSS.¹⁴

Although there are no prospective studies evaluating the medical management of cats with portosystemic vascular anomalies,¹ long-term medical treatment of cats with CEHPSS is associated with a poor outcome.¹⁵ In a study with 25 cats, there was no clinical response to medical treatment in 3 (12%) cats, partial clinical response in 14 (56%) cats, and complete resolution of clinical signs occurred in 8 (32%) cats.¹¹ In dogs, surgical treatment is associated with better outcomes compared to medical treatment.¹⁶ A similar study comparing the 2 has not been performed in cats.

Animals undergoing complete surgical shunt occlusion present a better prognosis compared to those with partial attenuation.^{14,17,18} However, dogs undergoing acute complete shunt ligation have a higher risk of developing portal hypertension.^{19,20} Complete, acute attenuation of a CPSS can be well tolerated in some cats.^{7,11,14}

Two methods of slow occlusion using extravascular techniques have been reported in cats: ameroid constrictor and cellophane band.^{3,6,12,14,21,22} The aim was to produce complete shunt attenuation gradually without causing portal hypertension.¹⁴ Cellophane or similar materials produce a foreign body reaction responsible for progressive vascular occlusion.^{5,9,14,23}

Postoperative complications in cats undergoing surgical attenuation are common, occurring in up to 75% of animals.^{1,6,7,21} The most common complications are signs of neurological disease, including generalized seizures in 8% to 22% of cats and central blindness in up to 44% of the cats.^{1,7,21}

Cats with CEHPSS undergoing ameroid constrictor occlusion present a survival rate of 33%-75%, with an excellent long-term outcome in 22.2%²¹ (clinically normal, normal shunt fraction on scintigraphy) to 75% cats⁶ (clinically normal, receiving no medical treatment). In cats undergoing ligation, survival rate ranges from 66% to 75% with excellent outcome (clinically normal, receiving no medical treatment) reported in 56% of the cases.⁷ In the present study, 21 of 49 cats had complete shunt attenuation at the first surgery and 28 had partial attenuation.

Regarding cellophane banding attenuation, survival rates are reported as 66%-100%^{3,24} with 1 study reporting excellent outcome (clinically normal, receiving no medical treatment) in 57.1% of the cases.³

The objective of this study was to describe the clinical presentation, postoperative complications, and outcome of cats treated surgically with thin film to attenuate a CEHPSS. Our hypothesis was that thin film attenuation is an appropriate management strategy for cats with CEHPSS and preoperative variables are not associated with postoperative outcomes.

2 | MATERIALS AND METHODS

2.1 | Case selection

Medical records at 3 different institutions (specialist referral centers) were reviewed to identify cats with a diagnosis of a CEHPSS that underwent surgical attenuation (from July 2008 through February 2017). A definitive diagnosis was made and shunt location confirmed during exploratory laparotomy, aided by portovenography in most cases. Only cats with a confirmed CEHPSS treated with thin film band attenuation were included in the study. Short-term outcome was defined as complications developed during hospitalization. Mid-term outcome was defined as complications and deaths related to CEHPSS occurring during the follow-up period. Mortality rate was defined as CEHPSS-related deaths in the immediate postoperative period or during the follow-up period.

2.2 | Medical records review

Data obtained from the medical records included age at presentation, sex, breed, weight, pertinent medical history, medical and dietary treatment (before and after surgery), clinicopathologic findings (including ammonia and bile acid stimulation test), results of diagnostic imaging, type of shunt, duration of hospitalization, short- and mid-term postoperative complications, and outcome. Survival to discharge, time to last follow-up, and, when available, survival time were also recorded. Fasting and poststimulation serum bile acid concentration was considered normal if $\leq 15 \mu\text{mol/L}$ and $\leq 25 \mu\text{mol/L}$, respectively.^{4,25} Abnormal behavior was defined as stuporous mentation, disorientation, or abnormal aggression.

2.3 | Surgical procedure

After induction of general anesthesia, a midline exploratory laparotomy was performed, the shunt was identified, and its anatomic location was recorded. Some cats underwent portovenography, according to the surgeon's preference. A polypropylene suture was placed after dissection of the shunt to temporarily occlude and confirm the identification of the correct vessel. An injection of a nonionic iodine contrast agent (Iohexol, Omnipaque, GE Healthcare) at a dosage of 1-2 mL/kg was used for portovenography. The polypropylene suture was left in place in all cases. This suture could be used to completely close the shunt during a second procedure, by the placement of surgical vascular clips on the 2 strands of the ligature or by tying a knot. In 2 institutions, the polypropylene suture was placed loosely around the vessel before placing the thin film, leaving long ends (3-4 cm) with a knot at the end. In 1 institution, the suture was ligated around the shunt to the same degree of occlusion as the thin film. Placement of the thin film was performed as described elsewhere,²⁴ although there were some variations according to the different institutions. The thin film was folded once or twice to form a 2- to 4-layered strip with thickness between 1 and 2 mm, and 3 to 5 titanium clips were used to secure it. The brand of the clips varied depending on the center.

The type of thin film used in 1 of the institutions was made of regenerated cellulose film, coated on both sides with nitrocellulose

(Cellophane 430 MS; Innovia Films Ltd). The composition of the thin film in the remaining centers was not recorded. The degree of attenuation applied on the vessel by the thin film varied from no compression to mild compression. Changes in heart rate, arterial pressure, intestinal color, and motility were taken in consideration to determine the degree of compression.

In 1 institution, liver biopsies were routinely obtained. In the other 2 institutions, liver biopsies were only obtained if the liver showed macroscopic abnormalities. The abdominal incision was routinely closed.

2.4 | Follow-up

Follow-up information included survival time and the presence of clinical signs and was obtained at the time of data collection for all cats that survived to discharge. This information was gathered through a combination of review of clinical records and telephone conversation with referring veterinarians and owners.

2.5 | Statistical analysis

Categorical variables are reported as percentages. Visualization of histograms and Shapiro-Wilk tests were used to assess for normality of continuous variables. Continuous data were not normally distributed and therefore were summarized as median and range (minimum-maximum).

Pairwise Fisher's exact test was used to evaluate the association between preoperative categorical variables (sex, neuter status, and preoperative clinical signs) and survival to discharge or occurrence of postoperative seizures. For the purpose of this analysis, clinical signs were grouped into major body systems as signs of neurological disease (abnormal behavior, ataxia, depression, lethargy, seizures, blindness, twitching, pacing, and muscle hypotonicity), signs of urinary disease (cystoliths, polyuria and polydipsia, hematuria, and dysuria) or signs of gastrointestinal disease (ptyalism, inappetence, and vomiting). The presence of stunted growth or copper-colored irides was analyzed separately. Due to their clinical relevance, preoperative seizures were also analyzed independently. A Mann-Whitney test was used to evaluate the association between preoperative continuous variables (age, duration of medical treatment before surgery, preoperative prestimulation and poststimulation bile acids, preoperative ammonia) and survival to discharge or occurrence of postoperative seizures. A Wilcoxon Signed-Rank test was used to evaluate differences between preoperative and postoperative serum bile acid concentration in cats where paired samples were available. Significance was set at a P -value $< .05$. Data analysis was performed with a commercial statistical software (IBM, SPSS Statistics Version 25).

3 | RESULTS

3.1 | Study population

Thirty-four cats met inclusion criteria. The study population comprised 9 different breeds including domestic shorthair (13/34–38%), British shorthair (7/34–20%), Persian (4/34–11%), Havana (2/34–5%),

Birman (2/34–5%), domestic long hair (2/34–5%), and 1 each of exotic short hair, Maine Coon, Tonkinese, and Siamese. The median age was 8 months (3–87 months), and median body weight was 2.5 kg (1.4–5 kg). Fourteen cats were female (8 spayed, 6 intact) and 20 cats were male (9 neutered, 11 intact). No significant association was present between occurrence of postoperative seizures (SEIZURES) or survival to discharge (SURVIVAL) and the following factors: sex (SEIZURES $P > .99$, SURVIVAL $P > .99$), neutering status (SEIZURES $P = .69$, SURVIVAL $P = .60$), age (SEIZURES $P = .41$, SURVIVAL $P = .74$), and weight (SEIZURES $P = .44$, SURVIVAL $P = .82$).

3.2 | Presurgical findings

Clinical findings included abnormal behavior (28/34–82%), ptyalism (25/34–73%), stunted growth (16/34–47%), ataxia (14/34–41%), copper-colored irides (13/34–38%), depression (12/34–35%), inappetence (10/34–29%), lethargy (10/34–29%), seizures (6/34–17%), cystoliths (5/34–14%), twitching (4/34–11%), vomiting (3/34–8%), polyuria and polydipsia (3/34–8%), hematuria (2/34–5%), pacing (2/34–5%), blindness (2/34–5%), dysuria (1/34–2%), and muscle hypotonicity (1/34–2%). Median duration of clinical signs before surgery was 4 months (0.4–48). No significant association between occurrence of postoperative seizures or survival to discharge and clinical signs of gastrointestinal disease (SEIZURES $P > .99$, SURVIVAL $P = .56$), clinical signs of urinary disease (SEIZURES $P > .99$, SURVIVAL $P > .99$), copper-colored irides (SEIZURES $P = .44$, SURVIVAL $P = .63$), or stunted growth (SEIZURES $P = 0.70$, SURVIVAL $P > .99$) was found. All cats presented at least 1 type of clinical signs of neurological disease, preventing meaningful analysis of this category. Due to their clinical relevance, seizures were analyzed independently. The presence of seizures before surgery was not significantly associated with an occurrence of postoperative seizures or survival to discharge (SEIZURES $P = .13$, SURVIVAL $P > .99$). Only 3 of the 6 cats with seizures before surgery developed seizures after surgery.

All cats received medical treatment before and after surgery. Median duration of medical treatment was 28 days (7–42 days) before surgery and 28 days (14–2046 days) after surgery. All cats were treated with an antibiotic. Ampicillin (Ampicillin, AAH Pharmaceuticals Ltd) was administered in 4 of 34 (11%) cats (dose unavailable from the medical records). Twenty-eight of 34 (82%) cats received potentiated amoxicillin (Synulox, Pfizer) at a median dose of 13 mg/kg (5–18 mg/kg) twice a day (dose information available for 18 cases). Two of 34 cats (5%) received metronidazole (dose unavailable). Thirty-three of 34 (97%) cats were treated with lactulose (Lactulose, Sandoz) at a median dose of 1 mL (0.2–3 mL) 3 times a day. Thirty-three of 34 (97%) cats received a low protein diet. Fifteen of 34 (44%) cats received an antiepileptic, which consisted of phenobarbitone (Phenobarbital elixir, Thornton and Ross) in 3 of 34 (8%) cats, at a median dose of 1.22 mg/kg (0.67–2 mg/kg), or levetiracetam (Keppra, GlaxoSmithKline) in 12 of 34 (35%) of the cases, at a median dose of 19 mg/kg (10–20 mg/kg) 3 times a day.

Of the cats pretreated with an antiepileptic ($n = 15$), 8 developed seizures after surgery, 4 of which subsequently died. Ten of 17 (58%) cats in the first institution were pretreated with antiepileptics, 5 of

TABLE 1 Median (range) values for results of plasma ammonia concentration and bile acid stimulation test in cats with a CEHPSS before shunt occlusion by thin film

Variable	Reference limits	Value
Ammonia ^a (μmol/L)	5-44	217 (22-466.6)
Fasting bile acids ^b (μmol/L)	≤ 15	37 (0.5-157)
Poststimulation bile acids ^c (μmol/L)	≤ 25	108 (5-276.4)

^aValues were available for 11 of 34 cats.

^bValues were available for 30 of 34 cats.

^cValues were available for 33 of 34 cats.

8 (62%) in the second institution, and 1 of 9 (11%) from the third institution.

Preoperative plasma ammonia concentrations were available in 11 of 34 (32%) cats, and in 10 of 11 (90%) cats, these levels were increased (Table 1). No significant association was found between preoperative plasma ammonia concentration and occurrence of postoperative seizures or survival to discharge (SEIZURES $P = .19$, SURVIVAL $P = .36$). Before surgery, fasting serum bile acid concentration was available in 30 of 34 (88%) cats and poststimulation serum bile acid concentration was available in 33 of 34 (97%) cats. Fasting serum bile acid concentration was abnormal in 22 of 30 (73%) cats, and poststimulation serum bile acid concentration was abnormal in 32 of 33 (97%) cats (Table 1). No significant association was found between postoperative seizures or survival to discharge and preoperative pre- (SEIZURES $P = .89$, SURVIVAL $P = .90$) and poststimulation (SEIZURES $P = .14$, SURVIVAL $P = .38$) bile acids.

In 1 cat, the bile acid stimulation test was normal before surgery; however, plasma ammonia concentration in this cat was markedly increased.

In 31 of 34 (91%) cats, CEHPSS were detected by ultrasound. Of the remaining 3 cats, 1 had both an ultrasound and computed tomography angiography performed to confirm the presence of a shunt, whereas in 2 cats, the diagnosis was achieved by computed tomography angiography only.

3.3 | Surgical findings

Portovenography was performed intraoperatively in 31 of 34 (91%) cats. A liver biopsy was obtained in 22 of 34 (64%) cats, and histopathology was available for 17 of 22 (77%) of these cats. The results of the histopathology showed arteriolar proliferation (16/17—94%), portal vein hypoplasia (15/17—88%), mild chronic multifocal biliary hyperplasia (1/17—5%), and abnormal triads without vena porta branches (1/17—5%).

The anatomy of the shunt was left gastro-phrenic (12/34—35%), spleno-caval (5/34—14%), left gastro-caval (4/34—11%), porto-caval (3/34—8%), and 1 each of pancreaticoduodeno-caval, left colo-caval, and porto-azygos. There were 7 cases (7/34—20%) in which the origin and insertion of the shunts were not described in the surgical report.

Cystotomy was not performed in any case. Gonadectomy was performed in 2 cases.

3.4 | Postsurgical findings

Median duration of hospitalization was 3 days (range, 2-6) for the cats that survived to discharge (30/34—88%). In these cats, the median duration of follow-up after discharge was 8 months (0.5-84 months). Updated information could not be obtained at the time of manuscript preparation in 1 cat. Complications occurred in 11 of 34 (32%) cats and consisted of seizures in 8 of 34 (23%) cats, apnea and coma on recovery in 1 of 34 (2%) cats, ascites in 1 of 34 (2%) cats, reduced vision/blindness in 2 of 34 (5%) cats, and pancreatitis in 1 of 34 (2%) cats. Some cats had more than 1 complication. Of the cats that developed seizures postoperatively, 5 of 8 (62%) cats did not have seizures before surgery. All the cats that developed seizures after surgery had received antiepileptic drugs before surgery, consisting in levetiracetam in 6 cases and phenobarbitone in 2 cases. In the cats that developed seizures during hospitalization (4 cases), these occurred within 5 days of surgery.

Six cats (6/34—17%) were euthanized after surgery due to CEHPSS-related causes. Four of these deaths occurred during hospitalization (short-term). Cats did not survive to discharge due to refractory seizures (3 cases) or apnea and coma on recovery (1 case). The cat that died because of apnea and coma on recovery had a normal bile acid stimulation test before surgery; however, plasma ammonia concentration in this cat was markedly increased. The 2 cats that died after discharge developed multiple acquired portosystemic shunts, which were diagnosed during a second surgery. Both had a persistently abnormal bile acid stimulation test. One of them was euthanized due to worsening seizures 6 months after a second surgery, which was performed due to persistently abnormal bile acid stimulation test 3 months after the first surgery. The other cat was euthanized 6 years after surgery due to weight loss and anorexia. This cat had persistently abnormal bile acid stimulation test, but it is unknown if the clinical signs of this cat were CEHPSS-related, given the significant time gap between the original surgery and the euthanasia.

In the mid-term, 3 of 28 (10%) of the surviving cats presented CEHPSS-related clinical signs: 2 cats developed postoperative seizures not present before surgery, 3 months after the first surgery and 6 months after a second surgery, respectively (the latter cat was euthanized). Postoperative persistence of preoperative seizures was present in a third case. In 2 cases, the seizures were successfully controlled with phenobarbitone or levetiracetam. Two cats were also euthanized in the follow-up period due to non-CEHPSS-related causes.

Ultrasound after surgery was performed in 4 of 30 (13%) cats. In 1 case, serial ultrasound were performed and revealed the presence of a very small residual flow 2 months after surgery; however, the liver received the majority of the blood flow and was increased in size. One cat had residual flow 4 months after surgery. This cat had a normal bile acid stimulation test and was clinically well up to the last follow-up 60 months after surgery and no subsequent ultrasounds

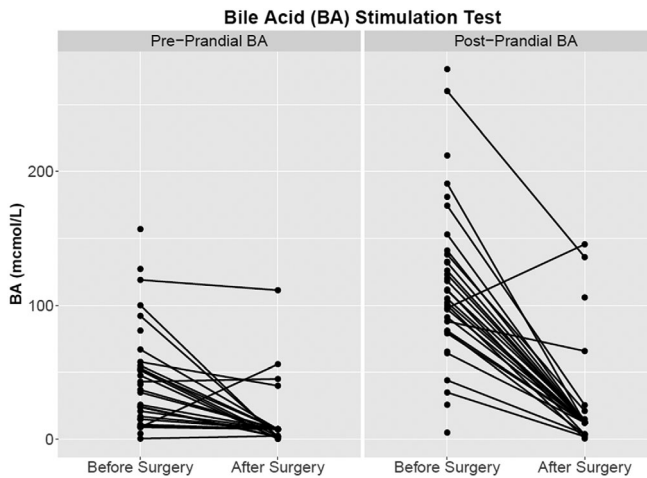


FIGURE 1 Bile acid stimulation test before and after surgery for 34 cats. (The dots without an associated line represent those cases where paired serum bile acid concentration was not available). After surgery, there was a significant decrease in both prestimulation ($P < .001$) and poststimulation ($P < .001$) serum bile acid concentration

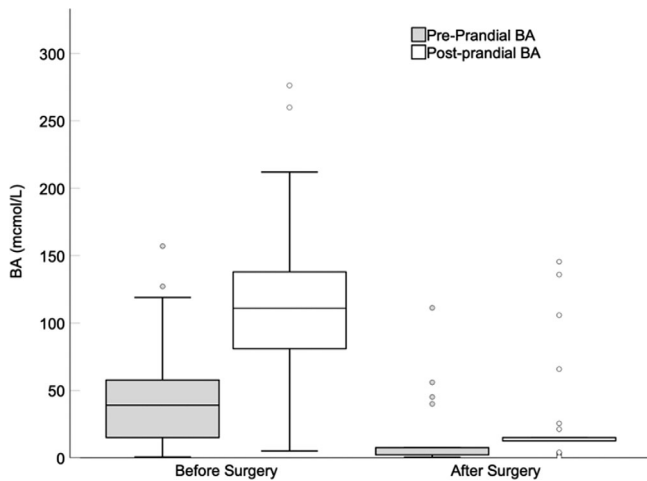


FIGURE 2 Boxplot that summarizes the serum bile acid concentration data for all the animals. The box identifies the interquartile range, while the line across it indicates the median. The whiskers indicate $1.5 \times$ the interquartile range or the maximum and minimum values. Individual dots represent outliers $>1.5 \times$ the interquartile range

were performed. The 2 remaining cats had no evidence of residual flow 2 months after surgery.

Postoperative bile acid stimulation test was performed in 28 of 34 (82%) cats. The cats that died during hospitalization and 2 of 30 (6%) cats that survived hospitalization did not have repeated bile acid stimulation test. Both of these cats were doing clinically well at their last follow-up at 36 and 40 months, respectively.

Both pre- ($P < .001$) and poststimulation ($P < .001$) serum bile acid concentration decreased significantly after surgery (Figures 1 and 2). Of the cats that survived to discharge and had a postoperative bile acid stimulation test performed, 25 of 28 (89%) cats had normal

results; In these cats, bile acid stimulation test normalized within a median of 90 days (14-196 days). Of the 3 cats with an abnormal postoperative bile acid stimulation test, 1 had a patent shunt and 2 had multiple acquired portosystemic shunts. In the cat with a patent shunt, a second surgery was performed and bile acid stimulation test normalized subsequently. The 2 cats with multiple acquired portosystemic shunts were both euthanized and have been described in greater detail above.

3.5 | Follow-up

The median follow-up period was 8 months (0.5-84 months).

4 | DISCUSSION

In the present study, cats that underwent attenuation of a single CEHPSS by thin film and survived the short-term postoperative period had good mid-term outcome. However, cats that developed postoperative seizures had a poor outcome. In the short- or mid-term, seizures were the most common reason for euthanasia. In the mid-term, only 3 cats had persistent clinical signs. Bile acid stimulation test normalized after shunt attenuation in all but those 3 cats. In cases in which bile acid stimulation test remained abnormal, patent shunt or acquired portosystemic shunts were observed.

The population of cats in this study was comparable with previous similar studies^{3,6,7} and consisted of young cats. There was an overrepresentation of male cats^{1,6,21} and domestic shorthair cats, which is in agreement with previous literature.^{3,6,7} The most common type of CPSS was extrahepatic, similarly to previous reports.^{3,7,11,12} In our study, the most common anatomy of the portosystemic shunt was left gastro-phrenic. A shunt originating from the left gastric vein was the most common type of extrahepatic portosystemic shunt in a similar study.³

The clinical signs observed before surgical attenuation were similar to those described previously.^{3,6,7} All cats presented with signs of neurological disease that most commonly consisted of abnormal behavior (28/34—82%). Signs of gastrointestinal disease occur more commonly in dogs than cats^{1,26} and, in the present study, only 3 of 34 (8%) cats presented with vomiting. However, ptyalism was frequent in this population (25/34—73%). Ptyalism is a common finding in cats with portosystemic shunts^{1,3,21} but is rarely described in dogs with this condition.⁶ Copper-colored irides (inappropriate for the breed) have been previously documented in cats^{1,3} and, in our study, 13 of 34 (38%) cats presented with this abnormality.

The total complication rate associated with thin film attenuation of CEHPSS in our study was 32% (11/34 cats), which is lower than previously reported. Cabassu et al³ reported 9 cats treated with thin film, and of the 7 surviving cats, 3 (43%) had persistent clinical signs. In another study using ameroid ring constrictors, 77% of the cats showed postoperative complications.⁶ In a study of cats treated with acute complete shunt ligation, 16 of 36 (44%) of the surviving cats had long-term complications.⁷ In a recent study²⁷ in which outcomes of dogs treated with ameroid ring constrictor or cellophane banding were compared,

postoperative complication rates did not differ between the 2 methods and clinical outcomes were good to excellent.

In our population, postoperative seizures were reported in 23% cases (8/34 cats) which is lower in comparison to a similar study of cats treated with CB, in which 33% of cats experienced seizures.³ The proportion of cats developing seizures in our population was similar to the previously reported 22% using ligature⁷ but higher than in a study using ameroid ring constrictors (14%).⁶ It appears that seizures occur in similar frequency after treatment with gradual occlusion devices when compared to suture ligation.

As previously documented, development of uncontrollable seizures is the most complication after portosystemic shunt surgery in cats.³ In this study, the presence of seizures before surgery was not significantly associated with an adverse outcome; only 3 of the 6 cats with seizures before surgery continued to have seizures after surgery. However, death was due to seizure activity in 4 of 6 cats, which is in agreement with previous findings.³ The cause of post-ligation neurologic dysfunction remains unclear; potential etiologies include decreased endogenous inhibitory central nervous system benzodiazepine agonist concentrations and imbalances in excitatory and inhibitory neurotransmitters.²⁸ Seizures might be secondary to hepatic encephalopathy or other metabolic abnormalities.²¹ However, in 3 cats of this study, seizures persisted despite normal bile acid stimulation test (2 cases) and normal bile acid stimulation test and plasma ammonia concentration (1 case). All 3 cats had experienced seizures before surgery. It would have been useful to obtain postmortem examination from the cats with seizures to determine whether irreversible changes were present despite normal bile acid stimulation tests.

The small sample size and the use of different medications and doses prevented us from evaluating any association between preoperative treatments, in particular, the use of antiepileptic drugs and postoperative outcomes. However, it is worth noting that all the cats that presented postoperative seizures were on treatment with antiepileptic drugs, including those that did not have seizures before surgery. Conversely, cats that were not treated with antiepileptic drugs before surgery did not develop seizures postoperatively. In addition, all the cats that developed new onset seizures after surgery were treated with levetiracetam.

The limitations of our study preclude speculation on the clinical importance of these findings; however, it raises questions on the benefit of preoperative antiepileptic drugs that will need to be addressed in future prospective studies. Interestingly, seizure aggravation after levetiracetam treatment was recently reported in 2 children with refractory epilepsies.²⁹

In a study of dogs with a CPSS surgically attenuated with ameroid ring constrictors, dogs pretreated with levetiracetam were at significantly lower risk of postoperative seizures and death and no dogs treated with levetiracetam experienced postoperative seizures.²⁸ However, in a large recently published study, including 253 dogs treated with cellophane banding or either partial or complete suture ligation, prophylactic levetiracetam did not reduce postattenuation neurological signs or seizures.³⁰

No studies assessing the potential prevention of seizures in cats were published at the time of writing. Whether the use of prophylactic

antiepileptic treatment has a positive, neutral, or negative effect in the development of seizures after surgery in cats remains unknown.

In this study, seizures that occurred during hospitalization did so on days 1, 2, 3, and 5, which emphasize the need for in-hospital monitoring after surgery.⁷

Blindness or reduced vision occurred only in 2 cats (5%), whereas previously this has been reported as a common complication affecting up to 44% of cats undergoing surgery.^{6,7,21} It is not known why cats appear more likely to develop this complication than dogs but usually it resolves within 2 months after surgery.^{1,6} The lower number of cats with this abnormality could be due to a true lower prevalence of blindness in this population or as a consequence of the retrospective nature of the study and possible lack of information within their records.

Case fatality rate secondary to CEHPSS in our cat population was 17% (6/34) and mid-term survival rate was 82%, which is similar to previous reports in cats undergoing cellophane banding attenuation with 2 separate studies showing a survival rate of 66% at 3 years³ and a 100% survival rate at 2 weeks.²⁴ Of the cats available for follow-up in a study with the ameroid ring constrictor, the mortality rate was 44%.²¹ Good long-term outcome was reported in 66%-75% of cats undergoing ligation.^{1,7}

Regarding the correlation between postoperative serum bile acid concentration and clinical outcome, it seems that postoperative serum bile acid concentration correlated well with shunt correction given that all the cats with persistently abnormal bile acid stimulation test had either a patent shunt or multiple acquired shunts. However, postoperative repeated imaging (computed tomography angiography or ultrasound) was performed only in a limited number of cats and therefore persistent shunting could have been missed in the remaining cases. Three cats with clinical signs in the long term (presenting with persistent seizures) had normal bile acid stimulation test. This suggests that serum bile acid concentration might not be sensitive enough to predict seizures, which could be due to failure to detect residual flow or due to a different cause for seizures. In a study including 23 cats treated with ameroid ring constrictors, 57% of cats had persistent shunting after performing portal scintigraphy.⁶ None of the cats in our study underwent scintigraphy and only 4 cats underwent abdominal ultrasonography after surgery; therefore, reasonable comparisons cannot be made with the results of our study.

Bile acid stimulation test is used for the diagnosis of portosystemic shunts with a reported sensitivity and specificity of 100% and 71%, respectively,^{1,31} and appears to be a sensitive predictor of long-term outcome after surgery.⁷ This test was therefore 1 of the outcome measures used in the present study. In this study, all cats free of clinical signs during the follow-up had normalization of the bile acid stimulation test.

The major limitation of this study was its retrospective nature and therefore the lack of standardized protocols. Cats received different medications (i.e., antibiotics, lactulose), and the effect of the use of these medications in the outcome was not analyzed. Although the diagnostic and therapeutic protocol was similar among the referral centers, complete data were not available for all cats given that it was a multicentric study. Other limitations included the lack of hepatic

histopathology in several cases, the low number of cases and events which limits statistical analysis, the lack of detailed information about the characteristics of the thin film in 2 institutions, the different anti-epileptic protocols used for each cat, the different diagnostic methods for diagnosis of the portosystemic shunts, and the lack of standardized times for reassessment of the cats and follow-up. Another limitation was the lack of postoperative gold-standard imaging techniques (i.e., computed tomography angiography) to confirm shunt closure.

5 | CONCLUSION

Congenital extrahepatic portosystemic shunt occlusion by thin film in cats carries a good short- and mid-term prognosis in cats that survive the postoperative period and do not develop postoperative seizures, the most common cause for death in this study. Bile acid stimulation test might be a good indicator of shunt attenuation and correlates well with clinical outcome.

ACKNOWLEDGMENTS

The authors thank our colleagues for assistance in providing the cases for the study and the private practitioners who referred cases for treatment. An abstract of this study (including 9 cases) was presented at the 27th ECVIM-CA Congress. Intercontinental, Saint Julian's, Malta, 14-16 September, 2017.

CONFLICT OF INTEREST DECLARATION

Authors declare no conflict of interest.

OFF-LABEL ANTIMICROBIAL DECLARATION

Authors declare no off-label use of antimicrobials.

INSTITUTIONAL ANIMAL CARE AND USE COMMITTEE (IACUC) OR OTHER APPROVAL DECLARATION

Authors declare no IACUC or other approval was needed.

HUMAN ETHICS APPROVAL DECLARATION

Authors declare human ethics approval was not needed for this study.

ORCID

Paula Valiente  <https://orcid.org/0000-0002-9920-8113>

REFERENCES

- Berent A, Tobias K. Portosystemic vascular anomalies. *Vet Clin Small Anim Pract.* 2009;39:513-541.
- Mankin TK. Current concepts in congenital portosystemic shunts. *Vet Clin Small Anim Pract.* 2015;45:477-487.
- Cabassu J, Seim H, MacPhail C, Monnet E. Outcomes of cats undergoing surgical attenuation of congenital extrahepatic portosystemic shunts through cellophane banding: 9 cases (2000-2007). *J Am Vet Med Assoc.* 2011;238(1):89-93.
- Cocker S, Richter K. Diagnostic evaluation of the liver. In: Ettinger S, Feldman E, Cote E, eds. *Textbook of Veterinary Internal Medicine.* St. Louis, MO: Elsevier; 2017:1611-1621.
- Frankel D, Seim H, MacPhail C, Monnet E. Evaluation of cellophane banding with and without intraoperative attenuation for treatment of congenital extrahepatic portosystemic shunts in dogs. *J Am Vet Med Assoc.* 2006;228(9):1355-1360.
- Kyles A, Hardie E, Mehl M, Gregory C. Evaluation of ameroid ring constrictors for the management of single extrahepatic portosystemic shunts in cats: 23 cases (1996-2001). *J Am Vet Med Assoc.* 2002;220(9):1341-1347.
- Lipscomb V, Jones H, Brockman D. Complications and long-term outcomes of the ligation of congenital portosystemic shunts in 49 cats. *Vet Rec.* 2007;160:465-470.
- Berent A, Tobias K. Hepatic vascular anomalies. In: Tobias K, Johnston S, eds. *Veterinary Small Animal Surgery.* 2nd ed. St Louis, Missouri: Elsevier; 2011.
- Youmans K, Hunt G. Experimental evaluation of four methods of progressive venous attenuation in dogs. *Vet Surg.* 1999;28:38-47.
- Tivers M, Lipscomb V. Congenital portosystemic shunts in cats: investigation, diagnosis and stabilisation. *J Feline Med Surg.* 2011;13(3):173-184.
- Lipscomb V, Lee K, Lamb C, Brockman D. Association of mesenteric portovenographic findings with outcome in cats receiving surgical treatment for single congenital portosystemic shunts. *J Am Vet Med Assoc.* 2009;15(234):221-228.
- Vogt JC, Krahwinkel DJ, Bright RM, et al. Gradual occlusion of extrahepatic portosystemic shunts in dogs and cats using an ameroid constrictor. *Vet Surg.* 1996;25:495-502.
- Scavelli TD. Complications associated with the diagnostic, medical, and surgical management of portosystemic shunts. *Probl Vet Med.* 1989;1:145-158.
- Tivers M, Lipscomb V. Congenital portosystemic shunts in cats: surgical management and prognosis. *J Feline Med Surg.* 2011;13:185-194.
- Blaxter A, Holt P, Pearson G, Gibbs C, Gruffydd-Jones T. Congenital portosystemic shunts in the cat: a report of nine cases. *J Small Anim Pract.* 1988;29:631-645.
- Greenhalgh SN, Dunning MD, McKinley TJ, et al. Comparison of survival after surgical or medical treatment in dogs with a congenital portosystemic shunt. *J Am Vet Med Assoc.* 2010;236:1215-1220.
- Hottinger HA, Walshaw R, Hauptman JG. Long term results of complete and partial ligation of congenital portosystemic shunts in dogs. *Vet Surg.* 1995;24:331-336.
- Hunt GB, Hughes J. Outcomes after extrahepatic portosystemic shunt ligation in 49 dogs. *Aust Vet J.* 1999;77:303-307.
- Swalec KM, Seguin B, Johnston G. Surgical approaches to single extrahepatic portosystemic shunts. *Compend Contin Educ Pract Vet.* 1998;20:593-601.
- Kummeling A, Van Sluijs FJ, Rothuizen J. Prognostic implications of the degree of shunt narrowing and the portal vein diameter in dogs with congenital portosystemic shunts. *Vet Surg.* 2004;22:17-24.
- Havig M, Tobias KM. Outcome of ameroid constrictor occlusion of single congenital extrahepatic portosystemic shunts in cats: 12 cases (1993-2000). *J Am Vet Med Assoc.* 2002;220:337.
- Bright RM, Vogt JC, Krahwinkel DJ, et al. Gradual occlusion of portosystemic shunts in dogs and cats using an ameroid ring constrictor. *Vet Surg.* 1997;26:253.
- Macalinden A, Buckley C, Kirby B. Biomechanical evaluation of different numbers, sizes and placement configurations of ligaclips required to secure cellophane bands. *Vet Surg.* 2010;39:59-64.

24. Hunt GB, Kummeling A, Tisdall PLC, et al. Outcomes of cellophane banding for congenital portosystemic shunts in 106 dogs and 5 cats. *Vet Surg.* 2004;33:25-31.
25. Webster C, Cooper J. Diagnostic approach to hepatobiliary disease. In: Bonagura J, Twedt D, eds. *Kirk's Current Veterinary Therapy XV*. St Louis, MO: Elsevier; 2014:569-575.
26. Winkler JT, Bohling MW, Tillson DM, et al. Portosystemic shunts: diagnosis, prognosis and treatment of 64 cases (1993-2001). *J Am Anim Host Assoc.* 2003;39:169-185.
27. Traverson M, Lussier B, Huneault L, Gatineau M, Gatineau M. Comparative outcomes between ameroid ring constrictor and cellophane banding for treatment of single congenital extrahepatic portosystemic shunts in 49 dogs (1998-2012). *Vet Surg.* 2017;00:1-9.
28. Fryer KJ, Levine JM, Peycke LE, Thompson JA, Cohen ND. Incidence of postoperative seizures with and without levetiracetam pretreatment in dogs undergoing portosystemic shunt attenuation. *J Vet Intern Med.* 2011;25:1379-1384.
29. Caraballo R, Cersosimo R, de los Santos C. Levetiracetam-induced seizure aggravation associated with continuous spikes and waves during slow sleep in children with refractory epilepsies. *Epileptic Disord.* 2010;12(2):146-150.
30. Strickland R, Tivers M, Adamantos S, Harcourt-Brown T, Fowkes R, Lipscomb V. Incidence and risk factors for neurological signs after attenuation of single congenital portosystemic shunts in 253 dogs. *Vet Surg.* 2018;1-11.
31. Ruland K, Fischer A, Hartmann K. Sensitivity and specificity of fasting ammonia and serum bile acids in the diagnosis of portosystemic shunts in dogs and cats. *Vet Clin Pathol.* 2010;39(1):57-64.

How to cite this article: Valiente P, Trehy M, White R, et al.

Complications and outcome of cats with congenital extrahepatic portosystemic shunts treated with thin film:

Thirty-four cases (2008-2017). *J Vet Intern Med.* 2020;34:

117-124. <https://doi.org/10.1111/jvim.15649>