

## CHOLEDOCHODUODENAL FISTULA SECONDARY TO DUODENAL ULCER DISEASE AND CHOLEDOCHOLITHIASIS: REPORT OF 2 CASES

Aziz MZA<sup>1</sup>, Ahmed M<sup>2</sup>, Siddiqui MMR<sup>3</sup>, Shipa MRA<sup>4</sup>, Sarker S<sup>5</sup>, Arif SM<sup>6</sup>, Siddiqui FM<sup>7</sup>

### Abstract

**Choledochoduodenal fistula is an uncommon complication of penetrated duodenal peptic ulcer or cholelithiasis or choledocholithiasis. The presenting features of these fistulas are those of the ulcer or recurrent attack of fever, abdominal pain and jaundice for recurrent cholangitis. Confirmation of the fistula may be difficult, although use of endoscopic retrograde cholangio-pancreatography has greatly facilitated their diagnosis. The majority of these fistulas heal spontaneously with intensive medical management. The remainder requires surgery and the operation of choice is vagotomy and antrectomy or gastrojejunostomy. We represent two cases of Choledochoduodenal fistula. One of them had proximal variety and another one was distal variety.**

**Key Words:** Abdominal pain, Fever, Jaundice, Pneumobilia, Choledochoduodenal fistula

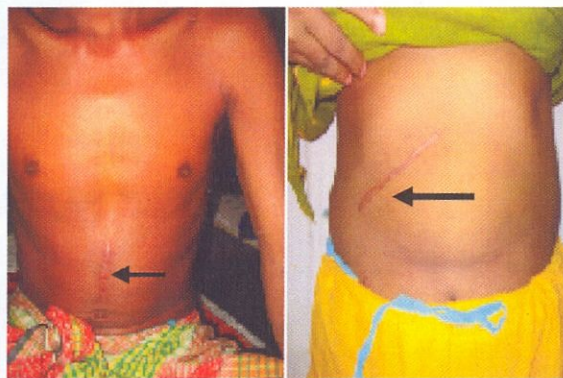### Introduction

Only 5% of all choledochoduodenal fistulas (CDF) are the consequence of complicated duodenal ulcer disease<sup>1</sup>, but also can occur by cholelithiasis or choledocholithiasis or iatrogenic. Although they often present without specific clinical symptoms and may be incidentally picked up on upper GI radiographic study or endoscopy, in some cases it may present with recurrent cholangitis and complicated duodenal ulcer disease. Now a day advances in Endoscopic retrograde cholangio pancreatography (ERCP) have lead to an increased detection of choledochoduodenal fistula (CDFs).

### Case Report 1

Mr. Afsar Ali, 28 years old man, muslim, married, smoker, normotensive, non-diabetic admitted at Department of Medicine, Dhaka Medical College (DMC) Hospital with the complaints of severe upper abdominal pain, high grade fever, vomiting 2-3 times per day and jaundice for the last two months. Two months back, the patient developed colicky pain in right upper quadrant of the abdomen which was intermittent initially and later became continuous, without any radiation and associated

with vomiting. Vomitus contained food material only but no blood and bitter in taste. Fever was intermittent, associated with chills and rigors and subsided with profuse sweating. He also developed fluctuating jaundice which was not associated with pruritus. With this presentation, he was admitted to other 2 hospitals during this 2 months period and treated conservatively with out confirming the diagnosis and discharged after clinical improvement but the same symptoms recurred with in a few days and lastly he came to DMC hospital on 15/2/2008. His bowel and bladder habit was normal, urine was dark and there was no history of abdominal swelling or malena. He was a known chronic case of duodenal ulcer disease for last 13 years and he used to take ranitidine irregularly. Seven years back he underwent surgery for perforated duodenal ulcer. He is a garment worker; lead a stressful life with poor socio-economic condition. There was no history of blood transfusion or unsafe sexual practice previously. On physical examination, he was mildly anaemic, moderately icteric, 2 cm palpable firm liver which was tender with ill defined margin and smooth texture. There was no other palpable mass in abdomen. Other systems revealed no abnormality.

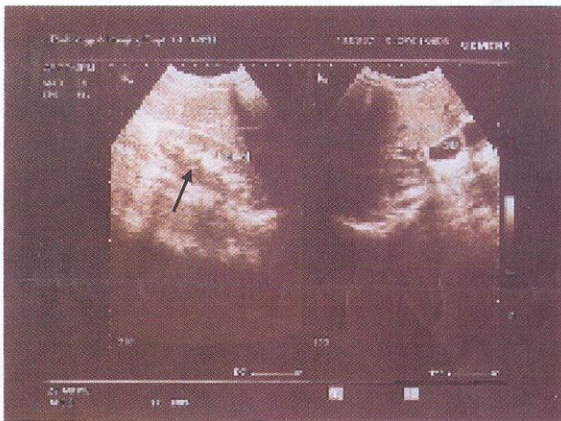


**Fig-1:** Scar mark in the abdomen: case 1 for perforated duodenal ulcer (left arrow), case 2 for cholecystectomy (right arrow).

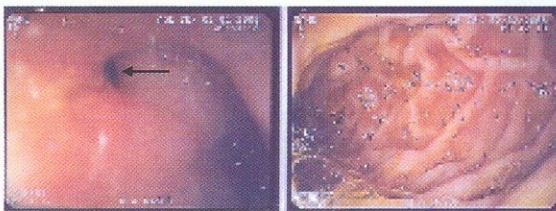
Investigations revealed Hb- 50%, total white blood cell

1. Dr. Md. Zakaria Al-Aziz, Assistant Registrar MU-Blue DMCH, 2. Dr. Mashrafi Ahmed, Indoor Medical Officer, BSMMU, 3. Dr. Md. Mahmudur Rahman Siddiqui, Postgraduate Resident, MU, DMCH, 4. Dr. Md. Ruhul Amin Shipa, Postgraduate Resident, MU-Blue, DMCH 5. Dr. Simal Sarker, Consultant, MU, DMCH 6. Dr. Syed Md. Arif, Associate Professor, Dept. of Medicine DMCH, 7. Prof. (Dr.) F. M. Siddiqui, Professor, Department of Medicine, DMCH.

count - 9,800/cmm, Differential count: Polymorph- 68%, Lymphocytes- 30%, Eosinophil- 01%, Monocyte- 01%, Basophil- 0%, Liver Function Test (LFT on 28/11/07): S. Bilirubin (total) - 3.4 mg/dl, ALT - 550 U/L Alkaline Phosphatase - 360 U/L Anti HBc IgM - < 2.0 U/ml (-ve) Prothrombin time - 20.3 sec INR- 1.69. LFT (on 26/01/08) S. Bilirubin (total) - 5.49 mg/dl ALT - 36.8 U/L HBs Ag (screening) - Negative, Prothrombin time - 17.6 sec INR- 1.54, Random blood sugar(RBS): 4.68m mol/L, S. Creatinine 0.9 mg/dl, Chest X-ray: Normal, Ultrasonogram of whole abdomen revealed distended gallbladder with sludge and pneumobilia, upper gastro intestinal endoscopy: Duodenal ulcer disease with choledocoduodenal fistula, Endoscopic retrograde cholangio pancreatography (ERCP): Normal ERCP with Choledocoduodenal Fistula (CDF). Finally he was diagnosed as a case of Proximal Choledocoduodenal Fistula due to chronic duodenal peptic ulcer disease.



**Fig-2:** Ultrasonography of hepatobiliary system showing distended gallbladder with sludge and pneumobilia.

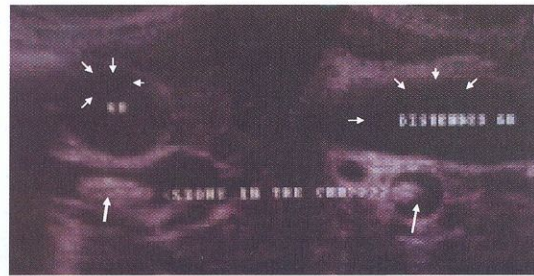


**Fig-3:** In upper GI endoscopy duodenal ulcer disease with choledocoduodenal fistula (arrow) with liking bile.

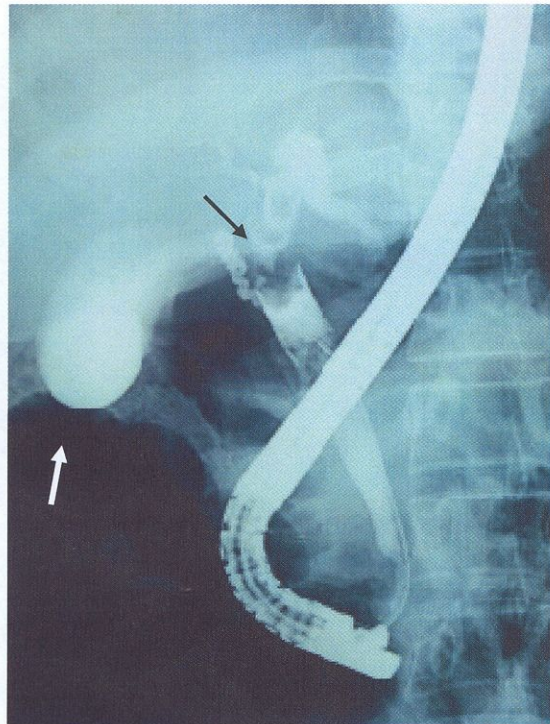
### Case Report 2

Mrs. Hasina, 35 year old, muslim, married, normotensive, non-diabetic lady admitted at Medical unit, Dhaka Medical College Hospital, with the complaints of recurrent right upper abdominal pain for last 1 year, which was associated with fever and chills. About 4 months back she was diagnosed as a case of choledocholithiasis as evident by dilated common bile duct (CBD) with multiple stones in CBD and distended gallbladder at a private hospital. Then they had done ERCP and tried to extract the stone from CBD, but the

attempt failed. Then second time ERCP and extraction was tried, but only one stone was extracted. Following



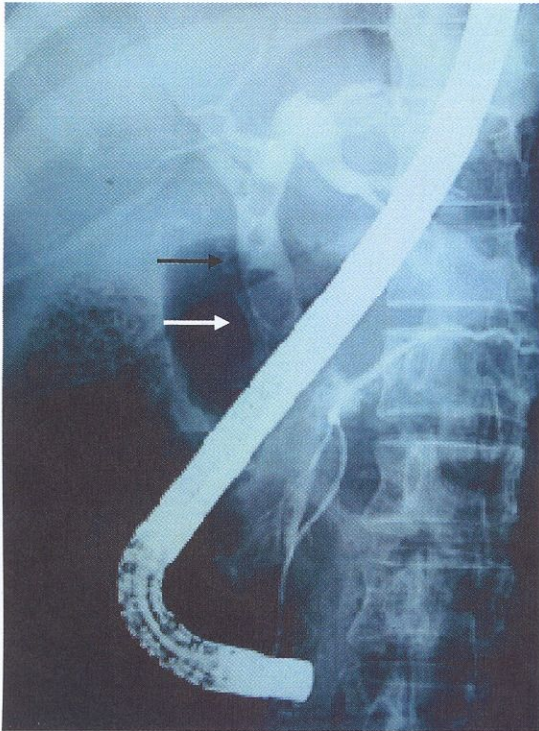**Fig-4:** Ultrasonography of hepatobiliary system showing stone (large arrows) in CBD with distended gallbladder (small arrows) .



**Fig-5:** ERCP showing stones in CBD (black arrow) with distended gallbladder (white arrow).

second day of ERCP she developed black stool, which persist for 5 days. After failure of ERCP extraction of stone open cholecystectomy was done. But After operation, there was no improvement of symptoms. She took several medications, which gave her temporary relieve of symptoms for few days then again became symptomatic.

At the day of admission, patient was febrile, toxic and abdominal examination revealed a healthy right subcostal scar mark with tenderness in epigastric and right hypochondrium region. Otherwise all systemic examinations were normal. Investigation revealed HB%-



**Fig-6:** ERCP showing stones in CBD (arrows).

11.2 g/dl, ESR- 55 mm in 1st hour, total white blood cell count - 15,500/cmm, differential count: Polymorph- 85%, Lymphocytes- 13%, Eosinophil- 01%, Monocyte- 01%, Basophil- 0%, S. Bilirubin- 0.68 mg/dl, S. ALT-34 U/L, Alkaline phosphatase-260 U/L, Prothombin time-15 sec, RBS-6.50 mmol/L, S. creatinine- 0.70 mg/dl, Urine routine examination-normal, Ultrasonography of the whole abdomen-absent gallbladder, Upper GI endoscopy-normal. But repeated ERCP revealed that Choledochoduodenal fistula, post papillotomy papilla with papillary stenosis with cholangitis. Finally the case was diagnosed as a case of Distal Choledochoduodenal fistula most probably due to choledocholithiasis or iatrogenic during cholecystectomy.

#### Discussion

CDF constitutes only 5% of the cases producing biliary enteric fistulae<sup>2</sup>. The reason for the rarity of this condition becomes apparent when one realizes that a duodenal ulcer most typically occurs about 4 cm distal to the pylorus whereas the CBD is about 7 cm distal to the pylorus<sup>3</sup>. A study of 81 patients over a 50-year period had attempted to list the incidences of several types of spontaneous bilioenteric fistulae. They include (a) cholecystoduodenal (68%), (b) cholecysto-colonic (13.6%), (c) choledochoduodenal (8.6%), (d) cholecysto-gastric (4.9%) and (e) duodeno-left hepatic (4.9%)<sup>4</sup>. Subclassification of CDFs: (a) Proximal CDFs - Primarily located along the posterior wall of the duodenal bulb. (b) Distal CDFs - Periampullary typically connects to the

distal 2 cm of the CBD. A review of 1929 ERCPs in Japan found 33 cases (1.9%)<sup>5</sup>. Another review of 1066 ERCPs in Taiwan found 27 cases (2.5%)<sup>6</sup>. Historically, CDFs have been reported more frequently in females; Proximal CDFs: 2:1, Distal CDFs: 3:1. More recently, it has been suggested that Proximal CDFs are more common in men. 75-90% of bilioenteric fistulas are associated with cholelithiasis and 5-6% are associated with duodenal PUD. In the past, 75-80% of CDFs reported in Western countries were due to PUD, while only 15% in Japan. With improved treatment options for PUD, these numbers appear to be changing.

80% of Proximal CDFs are caused by a penetrating duodenal ulcer, in a patient with a long history of PUD; like in case 1. Overall incidence of CDFs due to duodenal ulcers is low. Demonstration of an ostium in the duodenal bulb discharging bile during endoscopy is the most common means of diagnosis. Pneumobilia is an inconsistent finding, present in only 14-58% of patients, but reported first case was CDF. Barium reflux into the biliary tree is highly suggestive of the disease. Treatment of Proximal CDFs remains controversial. The natural history of CDFs due to ulcer disease is determined by the ulcer itself. Healing of ulcers frequently leads to the healing of the fistula. With recent advances in acid-suppression therapy, many authors advocate medical

therapy<sup>7</sup>, but they may require surgery if poor response to medical therapy. In the absence of primary biliary disease, there is minimal risk of cholangitis and biliary stricture.

In distal CDFs greater than 90% of cases are believed to be due to cholelithiasis or choledocholithiasis (in case2). Data is further supported by greater prevalence of Distal CDFs in cholelithiasis-endemic areas<sup>8</sup>. The presentation of Distal CDFs also mimics cholelithiasis, with right upper quadrant abdominal pain, fever and jaundice<sup>6</sup>. Ikeda Classification of Distal CDFs: Type I - Fistula present on longitudinal fold, just adjacent to the papilla. Type II - Fistula present on duodenal mucosa, proximal and adjacent to the duodenal fold<sup>9</sup>. Type I forms when small stone enters intramural portion of CBD. Fistulae and stones tend to be smaller. Type II forms, when a larger stone impacts in the extramural portion of CBD. Fistulas and stones are larger, with a 1.5 cm fistula and 4.2 x 2.6 x 2.5 cm stone reported<sup>9</sup>.

Karincaoglu et al. retrospectively reviewed 841 patients who underwent ERCPs in Turkey with 311 patients with CBD stones, 16 patients with CBD stones + Distal CDFs, 7 without prior surgeries/ERCPs, 9 with history of cholecystectomy, 6 with intraoperative bile duct exploration, 3 without<sup>8</sup>. Karincaoglu et al showed that, of their patients with distal CDFs, only 37.5% (6 out of their 16) had prior instrumentation of the CBD. However, 56% (9 out of 16) had a prior cholecystectomy<sup>8</sup>; likes in reported second case. In a series by Rimer in

Scandinavia, the incidence of iatrogenic CDFs during CBD exploration was 9.3%, rising to 23% when a rigid probe was used. Hunt and Blumgart in 1980 reviewed 90 patients referred for severe post-cholecystectomy problems. In 8 cases of distal CDFs, they found 3 cases occurred during sphincteroplasty or immediately following instrumentation and 5 cases were due to use of rigid probes with high resistance at the sphincter. Distal CDFs may also be created deliberately using a needle knife when routine cannulation methods are unsuccessful.

In proximal CDFs, loss of positive pressure due to CDFs leads to inability of the gallbladder to fill and contract adequately. As stagnant bile in the GB may become a source of infection, so cholecystectomy is advocated. Laparoscopic suturing or stapling can be performed concurrently as well. The remainder requires vagotomy and antrectomy or gastrojejunostomy. Little literature exists regarding the surgical management of distal CDFs. Hunt et al. recommended hepaticoducho-jejunostomy<sup>10</sup>. More recently, fibrin sealants have been used to endoscopically close the fistula.

### Conclusion

Both the reported patients have choledocoduodenal fistula. It may be due to a complication of long standing duodenal ulcer disease or possibly the previous surgery of gastric perforation repair may have created some adhesion between the walls of duodenum and CBD with subsequent formation of fistula in case1. On the other hand CDF in case2 probably due to choledocholithiasis.

Proximal CDFs are typically due to peptic ulcer disease. Distal CDFs are typically associated with cholelithiasis or choledocholithiasis. and the mainstay of treatment involves medical treatment or surgery.

### References

1. Jain GK, Myelavagnam C, Hamid A, Allarakhia L. Spontaneous choledocoduodenal fistula--due to chronic duodenal ulcer. *Med J Zambia*. 1980 Apr-May; 14(3):46-7.
2. Berk RN, Ferrucci JT, Leopold GR. Radiology of gallbladder and bile ducts. Philadelphia: WB Saunders and Co; 1983. p. 22-29.
3. Garg K, Malik N, Katariya RN. Choledochoduodenal fistula: an unusual complication of duodenal ulcer disease. *Ind J Gastroenterol* 1986; 5:51-52.
4. Stagnitti F, Mongardini M, Schillaci F, Dall'Olio D, De Pascalis M, Natalini E. Spontaneous biliodigestive fistulae. The clinical considerations, surgical treatment and complications. *G Chir* 2000; 21:110-7.
5. Yamashita H, Chijiwa K, Ogawa Y, Kuroki S, Tanaka M. The internal biliary fistula--reappraisal of incidence, type, diagnosis and management of 33 consecutive cases. *HPB Surg*. 1997; 10 (3):143-7.
6. Sheu BS, Shin JS, Lin XZ, et al. Clinical analysis of choledochoduodenal fistula with cholelithiasis in Taiwan: assessment by endoscopic retrograde cholangiopancreatography. *American Journal of Gastroenterology* 1996 Jan; 91(1):122-6.
7. Ohtsuka T, Tanaka M, Inoue K, et al. Is peripapillary choledochoduodenal fistula an indication for endoscopic sphincterotomy. *Gastrointestinal Endoscopy* 2001 Mar. 53(3):313-7.
8. Karıncaoğlu M, Yildirim B, Kantarceken B, Aladag M, Hilmioglu F. Association of peripapillary fistula with common bile duct stones and cholangitis. *ANZ J Surg* 2003 Nov; 73(11):884-6.
9. Ikeda S, Okada Y. Classification of choledochoduodenal fistula diagnosed by duodenal fiberoscopy and its etiological significance. *Gastroenterology* 1975 Jul; 69(1):130-7.
10. Hunt DR, Blumgart LH. Iatrogenic choledochoduodenal fistula: an unsuspected cause of post-cholecystectomy symptoms. *Br J Surg* 1980 Jan; 67(1):10-3.