

REVIEW

Neurochemical biomarkers to study CNS effects of COVID-19: A narrative review and synthesis

Arvid Edén^{1,2}  | Joel Simrén^{3,4}  | Richard W. Price⁵ | Henrik Zetterberg^{3,4,6,7}  | Magnus Gisslén^{1,2} 

¹Department of Infectious Diseases, Institute of Biomedicine, Sahlgrenska Academy, University of Gothenburg, Gothenburg, Sweden

²Department of Infectious Diseases, Region Västra Götaland, Sahlgrenska University Hospital, Gothenburg, Sweden

³Department of Psychiatry and Neurochemistry, Institute of Neuroscience & Physiology, the Sahlgrenska Academy at the University of Gothenburg, Mölndal, Sweden

⁴Clinical Neurochemistry Laboratory, Sahlgrenska University Hospital, Mölndal, Sweden

⁵Department of Neurology, University of California San Francisco, San Francisco, CA, USA

⁶Department of Neurodegenerative Disease, UCL Institute of Neurology, London, UK

⁷UK Dementia Research Institute at UCL, London, UK

Correspondence

Arvid Edén, Department of Infectious Diseases, Region Västra Götaland, Sahlgrenska University Hospital, Gothenburg, Sweden.
Email: arvid.eden@gu.se

Funding information

Erling-Persson Family Foundation; Vetenskapsrådet, Grant/Award Number: 2018-02532; Hjärnfonden, Grant/Award Number: FO2019-0228; Science for Life Laboratory, Grant/Award Number: KAW 2020.0182; Stiftelsen för Gamla Tjänarinnor; Swedish State Support for Clinical Research, Grant/Award Number: ALFGBG-717531 and ALFGBG-720931; UK Dementia Research Institute; European Union's Horizon 2020 research and innovation programme under the Marie Skłodowska-Curie grant agreement No 860197 (MIRIADE); Alzheimer Strategic Fund and Alzheimer Association, Grant/Award Number: ADSF-21-831376-C, ADSF-21-831377-C and ADSF-21-831381-C; Olav Thon Foundation; Alzheimer drug discovery foundation (ADDF), USA, Grant/Award Number: 201809-2016862

Abstract

Neurological symptoms are frequently reported in patients suffering from COVID-19. Common CNS-related symptoms include anosmia, caused by viral interaction with either neurons or supporting cells in nasal olfactory tissues. Diffuse encephalopathy is the most common sign of CNS dysfunction, which likely results from the CNS consequences of the systemic inflammatory syndrome associated with severe COVID-19. Additionally, microvascular injuries and thromboembolic events likely contribute to the neurologic impact of acute COVID-19. These observations are supported by evidence of CNS immune activation in cerebrospinal fluid (CSF) and in autopsy tissue, along with the detection of microvascular injuries in both pathological and neuroimaging studies. The frequent occurrence of thromboembolic events in patients with COVID-19 has generated different hypotheses, among which viral interaction with perivascular cells is particularly attractive, yet unproven. A distinguishing feature of CSF findings in SARS-CoV-2 infection is that clinical signs characteristic of neurotropic viral infections (CSF pleocytosis and blood-brain barrier injury) are mild or absent. Moreover, virus detection in CSF is rare and often of uncertain significance. In this review, we provide an overview of the neurological impact that occurs in the acute phase of COVID-19, and the role of CSF biomarkers in the clinical management and research to better treat and understand the disease. In addition to aiding

Abbreviations: ACE2, angiotensin-converting enzyme 2; ADEM, acute disseminated encephalomyelitis; BBB, blood-brain barrier; CNS, central nervous system; COVID-19, coronavirus disease 2019; CRS, cytokine release syndrome; CSF, cerebrospinal fluid; Ct, cycle threshold; EEG, electroencephalography; GBS, Guillain-Barré Syndrome; GFAP, glial fibrillary acidic protein; HIV, human immunodeficiency virus; HLA, human leukocyte antigen; MHC, major histocompatibility complex; MRI, magnetic resonance imaging; NFL, neurofilament light protein; SARS-CoV-2, severe acute respiratory syndrome coronavirus 2; sPDGFR β , soluble platelet-derived growth factor receptor β ; sTREM-2, soluble ectodomain of triggering receptor expressed on myeloid cells 2; TBEV, tick-borne encephalitis virus; TMPRSS2, transmembrane protease, serine 2; WBC, white blood cells; β_2 M, β_2 -microglobulin.

This is an open access article under the terms of the Creative Commons Attribution-NonCommercial-NoDerivs License, which permits use and distribution in any medium, provided the original work is properly cited, the use is non-commercial and no modifications or adaptations are made.

© 2021 The Authors. *Journal of Neurochemistry* published by John Wiley & Sons Ltd on behalf of International Society for Neurochemistry

as diagnostic and prognostic tools during acute infection, the use of comprehensive and well-characterized CSF and blood biomarkers will be vital in understanding the potential impact on the CNS in the rapidly increasing number of individuals recovering from COVID-19.

KEYWORDS

biomarker, central nervous system, cerebrospinal fluid, COVID-19, SARS-CoV-2

1 | INTRODUCTION

It has become increasingly apparent that neurological symptoms are common in patients suffering from coronavirus disease 2019 (COVID-19), during acute infection as well as long-term. Infection with the novel severe acute respiratory syndrome coronavirus 2 (SARS-CoV-2) (Helms et al., 2020; Mao et al., 2020; Wu et al., 2020) can lead to a wide spectrum of neurologic manifestations (or “neuro-COVID”) including headache, anosmia, encephalopathy, encephalitis, cerebrovascular manifestations including stroke, and peripheral neurological manifestations including Guillain-Barré syndrome (GBS) (Ellul et al., 2020; Zubair et al., 2020). Psychiatric manifestations and long-term post-infectious manifestations including anxiety and fatigue are also increasingly recognized as possible infectious complications (Carfi et al., 2020; Mazza et al., 2021; Halpin et al., 2020; Varatharaj et al., 2020). The mechanisms contributing to neurological symptoms are still not fully understood, but likely include toxic or metabolic complications to respiratory and/or systemic disease, as well as consequences of the anti-SARS-CoV-2 immune response including the cytokine release syndrome (CRS) and excessive immune activation (Vabret et al., 2020). It is not clear to what extent direct viral invasion of the brain can occur, and whether active CNS infection contributes to neuro-COVID. However, evidence from cerebrospinal fluid (CSF) analyses clearly indicate that neuro-COVID differs from many other CNS infections in several key aspects. In CSF analyses of patients with COVID-19, viral RNA detection is almost uniformly negative or ambiguous. Moreover, CSF pleocytosis, impaired blood–brain barrier (BBB) integrity, or intrathecal humoral responses commonly found in other CNS infections are often absent or only mildly abnormal (Eden et al., 2021; Meppiel et al., 2021; Virhammar et al., 2020). Despite apparent lack of overt infectious signs in the CSF of many patients, increased concentrations of markers of immune activation as well as neuronal injury have been described in several studies, indicating the importance as well as a potential consequence of the inflammatory response to SARS-CoV-2 during acute infection, and potentially for the long-term pathogenesis of neuro-COVID (Eden et al., 2021; Kanberg et al., 2020; Pilotto et al., 2021; Virhammar, Naas, et al., 2020).

Several mechanisms may contribute to some or all aspects of neuro-COVID and SARS-CoV-2 neuropathogenesis. These include (1) direct viral interaction with neuronal and supportive cells primarily in the olfactory mucosa; (2) indirect consequences of the systemic immune response leading to activation of CNS-resident immune

cells; (3) viral interaction with cells of the vasculature including pericytes and/or endothelial cells; or (4) others. Likely, different combinations of these mechanisms could contribute simultaneously to the clinical disease manifestations of individual patients.

The CSF compartment surrounds the CNS, and CSF sampling has proven to be a very valuable tool for diagnosing, monitoring, and characterizing other CNS infections as well as non-infectious neurological diseases. In this narrative review, we describe the current understanding of the neurochemical diagnosis of neurological manifestations of COVID-19 and SARS-CoV-2 neuropathogenesis, with a special focus on CSF evidence of direct viral infection of the CNS, CNS inflammatory and immunological responses to SARS-CoV-2 infection, and biomarker signs of neuronal injury. Moreover, we evaluate the potential usefulness of CSF and blood biomarkers in both understanding CNS pathogenesis and establishing a diagnosis of CNS infection. A better understanding of the underlying pathogenetic mechanisms in neuro-COVID is vital and has important implications when considering future CNS-targeted treatment interventions. We propose that the use of comprehensive and well-established CSF and plasma biomarkers, complemented by exploratory approaches, is essential in that regard. Moreover, CSF and plasma biomarkers will likely play an important role in the clinical evaluation of patients suffering from neuro-COVID both during the acute phase of infection and for the management of long-term sequelae.

2 | SEARCH STRATEGY AND SELECTION CRITERIA

References were identified by PubMed searches for studies published up to January 2021 using combinations of the search terms SARS-CoV-2, COVID-19, cerebrospinal fluid, central nervous system, biomarker. English language articles, including references from relevant articles, were included based on relevance to the subject of this review.

3 | THE CLINICAL SPECTRUM OF NEUROLOGIC MANIFESTATIONS IN COVID-19

Since the beginning of the pandemic, a variety of symptoms and signs attributable to CNS involvement have been described in

COVID-19 patients, and early reports of CNS manifestations during the SARS-CoV-2 pandemic have been comprehensively reviewed by others (Ellul et al., 2020; Zubair et al., 2020). The most common symptoms attributable to CNS involvement include headache, anosmia, and dysgeusia, which are common in mild as well as severe diseases (Gupta et al., 2020; Lechien et al., 2020; Liotta et al., 2020; Mao et al., 2020). Additional neurological manifestations have been tentatively categorized according to the probable underlying mechanisms and include unspecific or toxic/metabolic encephalopathies, inflammatory CNS disorders including encephalitis and acute disseminated encephalomyelitis (ADEM), vascular injuries (ischemic stroke and others), and peripheral neurological disorders including Guillain-Barré Syndrome (GBS) (Paterson et al., 2020). The frequency of CNS manifestations varies greatly in different reports, ranging from <10% up to over 80% depending on study design, symptom definition, and inclusion criteria (Frontera et al., 2021; Liotta et al., 2020; Mao et al., 2020; Meppiel et al., 2021; Romero-Sanchez et al., 2020; Toklu et al., 2020).

Anosmia and dysgeusia are common symptoms in mild as well as more severe COVID-19. Reported frequencies vary widely from around 10% to as high as 88% in different studies (Gerkin et al., 2021; Giacomelli et al., 2020; Lechien et al., 2020; Liotta et al., 2020). Anosmia is likely a result of viral interaction with non-neuronal cells of the mucosal surfaces in the olfactory epithelium and olfactory bulb, but may not be an immediate consequence of direct infection of neuronal cells (Brann et al., 2020; Fodoulian et al., 2020).

Headache is a common feature of COVID-19 and can be quite severe and sometimes persistent (Iqbal et al., 2021; Mao et al., 2020). Although headache is common in the acute phase of many viral infections and can likely often be attributed to host inflammatory responses, increased CSF opening pressure indicating intracranial hypertension has been noted in patients with COVID-19 with headache without concurrent signs of meningitis or encephalitis (Espindola et al., 2020; Silva et al., 2020). Posterior reversible encephalopathy syndrome (PRES) has also been described in patients with headaches and other neurological symptoms during severe COVID-19 (Lallana et al., 2021). Although not a common finding, central venous thrombosis (CVT) has been described in patients with COVID-19 (Guendouz et al., 2021). While the specific underlying mechanisms related to headache in SARS-CoV-2 infection are not yet clear, it is possible that the endothelial dysfunction and coagulopathy induced by SARS-CoV-2 infection may contribute to alterations in venous outflow or CSF absorption leading to intracranial hypertension in some patients.

The most prevalent sign of CNS dysfunction is new-onset encephalopathy (including altered consciousness or confusion, changes in personality or behavior, and sometimes seizures), reported in 7 to 38% of hospitalized patients (Frontera et al., 2021; Helms et al., 2020; Kremer et al., 2020; Liotta et al., 2020; Mao et al., 2020; Meppiel et al., 2021; Romero-Sanchez et al., 2020; Varatharaj et al., 2020). In patients with COVID-19, encephalopathy is generally not accompanied by CSF pleocytosis or magnetic resonance imaging (MRI) abnormalities and appears to be mostly reversible in many cases (Eden

et al., 2021; Espindola et al., 2020; Kremer et al., 2020; Meppiel et al., 2021; Neumann et al., 2020; Paterson et al., 2020). However, encephalopathy was associated with worse functional outcomes in one report (Liotta et al., 2020), and neurological manifestations, in general, have been associated with increased in-hospital mortality and decreased likelihood of discharge home or higher level of disability at discharge (Frontera et al., 2021; Mao et al., 2020; Pilotto et al., 2020).

Encephalitis, usually defined by the presence of CSF pleocytosis and/or MRI abnormalities or electroencephalography (EEG) alterations, is often accompanied by elevated CSF protein and signs of intrathecal IgG production. Encephalitis is reported in lower frequency than encephalopathy and predominately in individuals with severe COVID-19 (Espindola et al., 2020; Kandemirli et al., 2020; Kremer et al., 2020; Meppiel et al., 2021; Paterson et al., 2020; Pilotto et al., 2021; Romero-Sanchez et al., 2020). In addition, other inflammatory or auto-immune neurological syndromes including acute myelitis, ADEM, and acute hemorrhagic necrotizing encephalitis have been described during, or in close proximity to, infection with SARS-CoV-2 (Espindola et al., 2020; Kandemirli et al., 2020; Kremer et al., 2020; Meppiel et al., 2021; Neumann et al., 2020; Paterson et al., 2020; Pilotto et al., 2021, 2021; Poyiadji et al., 2020; Romero-Sanchez et al., 2020; Virhammar, Naas, et al., 2020). Although ADEM was previously known primarily as a post-infectious complication in children (Pohl et al., 2016), during the current SARS-CoV-2 pandemic, most cases have been described in adults.

The frequency and incidence of vascular complications and ischemic stroke vary greatly in different reports (Liotta et al., 2020; Varatharaj et al., 2020; Yaghi et al., 2020). Observational data suggest an increased incidence of cerebrovascular events and possibly a higher prevalence of large-vessel stroke in patients with COVID-19 (Beyrouiti et al., 2020; Meppiel et al., 2021; Oxley et al., 2020; Pilotto, Benussi, et al., 2020). The pro-thrombotic state generated by inflammatory responses initiated via viral interaction with the perivascular cells likely contributes to the increased risk of thromboembolic events in patients infected by SARS-CoV-2 (Beyrouiti et al., 2020; Ellul et al., 2020; Poillon et al., 2020; Tang et al., 2020; Varga et al., 2020). In addition to evidence of concurrent thromboembolism (pulmonary embolism, deep venous thrombosis), pre-existing risk factors or comorbidities are often present in patients with cerebrovascular complications during COVID-19 (Beyrouiti et al., 2020; Meppiel et al., 2021; Paterson et al., 2020). Cerebral microbleeds and other microvascular complications have also been noted in patients with COVID-19 and maybe a consequence of endothelial dysfunction mediated by the interaction of the virus with angiotensin-converting enzyme 2 (ACE2) receptors on perivascular cells. (Lee et al., 2020; Meppiel et al., 2021; Paterson et al., 2020; Saitta et al., 2020). According to recent reports, the cell-surface receptor for SARS-CoV-2, ACE-2, is expressed mainly on pericytes and to a much lesser extent on endothelial cells (McCracken et al., 2021). Additionally, pericytes express the cellular proteases cathepsin B/L that are important cofactors mediating viral cleavage in infection with SARS-CoV-2, suggesting that pericytes may be the principal



target cells in viral interaction with the vasculature. It has been hypothesized that a previously compromised endothelial barrier function, which is characteristic in hypertension, diabetes, and obesity, may increase pericyte exposure and promote virus–pericyte interaction. The resulting inflammatory response associated with vascular infection may partly explain why these conditions are risk factors for severe COVID-19 and may also contribute to the thromboembolic events seen in predisposed individuals (He et al. 2020).

Guillain-Barré syndrome and other peripheral neuropathies have been described in patients diagnosed with COVID-19 (Bellon et al., 2020; Ellul et al., 2020; Espindola et al., 2020; Frontera et al., 2021; Neumann et al., 2020; Paterson et al., 2020; Varatharaj et al., 2020; Zubair et al., 2020). GBS is an acute para- or post-infectious syndrome of polyradiculopathy that can occur as an immunological complication to bacterial or viral infections (Wakerley & Yuki, 2013; Wijdicks & Klein, 2017). Indications suggest that GBS in COVID-19 usually presents within the first two weeks of disease (Ellul et al., 2020; Toscano et al., 2020), indicating that there may be an overlap between active SARS-CoV-2 infection and GBS onset that suggests a more para-infectious rather than post-infectious syndrome (Espindola et al., 2020). Typical CSF findings in GBS include increased CSF/serum albumin ratio as a sign of blood–brain barrier opening (Brettschneider et al., 2005), and increased CSF as well as plasma NfL concentration as a sign of neuroaxonal injury (Altmann et al., 2020; Axelsson et al., 2018; Martin-Aguilar et al., 2020); like in most cases of COVID-19, CSF cell counts are typically normal (Korinthenberg, 2013).

4 | CSF AND PLASMA BIOMARKERS OF CNS INFECTION, INFLAMMATION, AND INJURY

CSF and plasma biomarkers that reflect different responses and consequences of CNS disease have been shown to be useful for evaluating CNS infections, as well as for providing valuable tools to describe the pathogenesis of various viral and non-viral infections in the CNS (Dittrich et al., 2020; Gisslen et al., 2007; Price et al., 2013). In addition to detecting the invading pathogen, monitoring host inflammatory responses and CNS injury can provide insights to characterizing the magnitude, character, and impact of viral CNS infections. Although available data are still limited, studies of CSF and plasma biomarkers in COVID-19 have similar potential to provide valuable insights regarding the character and pathogenesis of the neurological manifestations in SARS-CoV-2 infection.

4.1 | Core clinical chemistry biomarkers of CNS infection and inflammation

An important marker of CNS infection is the direct detection of the invading pathogen itself, which in many situations provides a diagnosis of the cause of infection, the typical case being Herpes virus encephalitis, where polymerase chain reaction is a highly sensitive and specific

diagnostic method (Lakeman & Whitley, 1995). However, the virus may not always be present in the CSF at the time when clinical symptoms and signs develop. In tick-borne encephalitis virus (TBEV) infection, the virus is present in the CSF early in the infectious course but is usually no longer detectable when the following immune response leads to clinical signs of encephalitis (Veje et al., 2018). Similarly, in influenza virus encephalitis, viral RNA is rarely detected in CSF (Studahl, 2003).

Increased CSF white blood cell (WBC) count is a typical sign of CNS infection. In response to an invading pathogen, leucocytes from the peripheral circulation are recruited across the blood–brain barrier (BBB) into the CSF compartment. Indeed, an elevated CSF white blood cell count (WBC) is often used as the primary indicator of CNS infection, although it is not a universal finding (Berger et al., 1998; Williamson & Berger, 2017).

Although typically more prominent in acute bacterial meningitis, impaired BBB integrity can be a component of all CNS infections. The most established biomarker of BBB integrity is the CSF:serum albumin ratio (Blennow et al., 2010). More specifically, CSF albumin concentration is a reflection of the blood–CSF barrier function (including capillary BBB, protein diffusion, and CSF flow rate), since albumin originates exclusively from blood (Reiber & Peter, 2001). Impaired BBB or blood–CSF barrier integrity is also a common finding in the diagnostic workup of GBS, commonly without corresponding increases in white blood cell count (Willison et al., 2016). Recently, soluble platelet-derived growth factor receptor β (sPDGFR β) has been proposed as a new candidate biomarker of BBB function (Miners et al., 2019; Nation et al., 2019; Sagare et al., 2015). sPDGFR β is abundantly expressed in brain pericytes (Lindahl et al., 1997), a cell type that also expresses ACE2 as well as the viral cofactor TMPRSS2 (a protease mediating S-protein cleavage), making pericytes a theoretical target for SARS-CoV-2 infection. In addition to the potential impact on BBB integrity, infection of pericytes could potentiate other neuroinflammatory processes, which may have special relevance to the pathogenesis of neuro-COVID, similarly to what has been hypothesized in systemic infection (Brann et al., 2020).

Intrathecal humoral immune responses can be measured using the immunoglobulin G and M (IgG and IgM) serum/CSF indices (Yilmaz et al., 2019). Moreover, oligoclonal bands can be present in several infectious as well as other CNS disorders, as a sign of increased intrathecal antibody production, and recent evidence suggests that kappa free light chain index might be a more sensitive measure (Presslauer et al., 2008; Susse et al., 2020). Additionally, intrathecal detection of increased concentrations of pathogen-specific antibodies provides the basis for diagnosis in infections such as TBEV (Veje et al., 2018), West Nile viral encephalitis (Busch et al., 2008), and Lyme neuroborreliosis (Tumani et al., 1995).

4.2 | Novel biomarkers of CNS inflammation and injury

Soluble inflammatory markers in CSF or plasma can be used to measure the CNS immune response to infections (Price et al., 2013).



A variety of biomarkers have been studied more or less extensively in viral and other CNS infections and interesting early findings have recently also been reported in COVID-19. Among the more well studied are YKL-40 (chitinase-3-like-protein), which is a glycoprotein expressed by many cell types, but abundantly in reactive astrocytes (Bonneh-Barkay et al., 2010) and macrophages (Rehli et al., 2003). While serum concentrations are increased in many peripheral inflammatory diseases (Johansen et al., 1999; Koutroubakis et al., 2003), CSF concentrations rise in conditions where neuroinflammation is present, including HIV-associated dementia, Alzheimer's disease, and multiple sclerosis (MS) (Malmstrom et al., 2014), where it decreases in response to treatment. Another established biomarker of predominantly astroglial origin is a glial fibrillary acidic protein (GFAP) (Olsson et al., 2011; Zetterberg & Blennow, 2016). GFAP increases rapidly both in plasma/serum and CSF in response to acute brain injuries, such as in stroke (Katsanos et al., 2017) and traumatic brain injury (TBI) (Laverse et al., 2020) and can also be used as a marker of astrocyte activation (Zetterberg et al., 2006; Neselius et al., 2012; McMahon et al., 2015; Cotto et al., 2019).

Microglial activation biomarkers include the proteolytically released soluble ectodomain of triggering receptor expressed on myeloid cells 2 (sTREM-2), and the cell surface peptide plays a vital role in microglia signaling (Ulland & Colonna, 2018). However, CSF sTREM-2 increases both in the early stages of AD as a response to toxic amyloid- β species and in MS, where it normalizes after treatment in the relapsing-remitting form of the disease (Ohrfelt et al., 2016). Serum levels of sTREM-2 have not yet been shown to be of clinical use (Ashton et al., 2019).

Neopterin (6-(β -erythro-1', 2', 3'-trihydroxypropyl)-pterin), a well-established biomarker of cellular activation, is released from monocytic cells, including macrophages and microglia, after stimulation with IFN- γ (Huber et al., 1984). When measured in CSF, neopterin has been found to be both a sensitive and CNS-specific immune activation marker in viral CNS infections (Fuchs et al., 1991; Hagberg et al., 2010; Molero-Luis et al., 2020) as well as in auto-immune disorders and cancer (Murr et al., 2002). IFN- γ also promotes degradation of tryptophan in the kynurenine pathway that produces several neuroreactive metabolites, including quinolinic acid, that may contribute to neurologic disorders (Schwarcz et al., 2012).

β 2-microglobulin (β 2 M) is a component of the major histocompatibility complex (MHC) class I molecule and is also frequently altered in CSF in neuroinflammatory diseases (Fuchs, Kramer et al., 1991).

Many other biomarkers of innate and adaptive immune responses have been investigated in the context of neuroinflammatory disease and CNS infections. Due to the fact that most are abundantly expressed in peripheral tissues, CSF measurements of cytokines and chemokines illuminating differential immune response patterns have been extensively investigated (IL-6, IL-8, CXCL-13, IL-1 β , TNF- α among others) (for review, see Kothur et al., 2016).

CSF and plasma biomarkers can also be used to detect CNS injury. Neurofilament light chain protein (NfL) is a structural component that is highly expressed in large-caliber subcortical axons. CSF NfL is a sensitive and well-studied marker of axonal injury in CNS infections as well as other non-infectious CNS diseases (Bridel et al., 2019; Jessen Krut et al., 2014; Yilmaz et al., 2017; Zetterberg & Blennow, 2016). In acute settings, plasma concentrations of NfL normally increase (weeks to months) (Gendron et al., 2020), as well as normalizes (months to a year) (Shahim et al., 2016) more slowly than GFAP (Shahim et al., 2016). Serum and plasma concentrations of NfL measured by single molecule array (Simoa) correlate strongly with CSF NfL (Kuhle et al., 2016). NfL has been evaluated as a sensitive and dynamic biomarker of CNS injury and treatment response in neuro-HIV (Gisslen et al., 2016; Anderson et al. 2020), and many other neurologic diseases (Kuhle et al., 2019; Olsson et al., 2019). Additional injury markers including tau and S100B are also under investigation in relation to CNS manifestations of COVID-19. Used in combination with clinical signs, neuroimaging, and other methods, we suggest that biomarkers such as the ones described here give important information regarding the cause, mechanism, and consequence of a CNS infection.

5 | EVIDENCE OF VIRAL CNS INFECTION

Despite the increasing number of reports describing neurological symptoms and signs in patients with COVID-19, SARS-CoV-2 is rarely detected in CSF. In available studies reporting a total of 449 CSF samples from patients with neuro-COVID, viral RNA was detected in only 12 (2.7%) (Alexopoulos et al. 2020; Andriuta et al., 2020; Bellon et al., 2020; Bodro et al. 2020; Cao et al., 2020; Eden et al., 2021; Espindola et al., 2020; Farhadian et al., 2020; Franke et al., 2021; Frontera et al., 2021; Helms et al., 2020; Kandemirli et al., 2020; Keller et al., 2020; Kremer et al., 2020; Lersy et al., 2021; Meppiel et al., 2021; Miller et al., 2020; Moriguchi et al., 2020; Neumann et al., 2020; Paterson et al., 2020; Remsik et al. 2020; Romero-Sanchez et al., 2020; Saitta et al., 2020; Virhammar, Naas, et al., 2020; Perrin et al., 2021; Pilotto et al., 2021; Domingues et al., 2020). Furthermore, when viral RNA has been detected, levels are either very low (Domingues et al., 2020; Lersy et al., 2021; Moriguchi et al., 2020; Virhammar, Kumlien, et al., 2020), or not reported (Espindola et al., 2020; Meppiel et al., 2021; Saitta et al., 2020). One exception is a patient with CSF pleocytosis and MRI abnormalities suggestive of encephalitis, who had an estimated 4.3 log₁₀ viral RNA copies/mL in CSF (Lersy et al., 2021). Additionally, the SARS-CoV-2 genome was detected and sequenced in the CSF of one patient with suspected demyelinating disease (Domingues et al., 2020). Most real-time PCR assays can reliably detect viral RNA >100–500 copies/mL, roughly equivalent of cycle threshold (Ct) values \leq 38. High Ct values >40 are usually considered negative and levels >34 rarely represent meaningful disease when measured in the respiratory tract (Tom & Mina, 2020). Additionally, at high Ct values,

amplification of blood or lab contaminants or primer dimerization can result in false-positive results, making interpretation unreliable. In the absence of other signs of infection, such as CSF pleocytosis or BBB/blood–CSF barrier damage, the significance of viral RNA at very low levels in CSF is unclear, and likely does not in itself indicate active infection or viral CNS invasion. Indeed, we recently reported similar findings in six patients with moderate or severe COVID-19 with neurological symptoms, where 3/6 had detectable SARS-CoV-2 RNA in CSF ($Ct > 37$) without accompanying CSF pleocytosis, IgG-synthesis, or BBB/blood–CSF barrier damage, and where all CSF samples were SARS-CoV-2 RNA negative when retested using another assay. Although lack of repeatability in viral detection may have resulted from technical issues such as loss of material during freezing and thawing of samples, nevertheless the very low levels, if any, of virus detected may not be relevant or even indicate ongoing CNS infection (Eden et al., 2021).

In contrast, most studies of neuro-COVID patients report failure to detect SARS-CoV-2 RNA in CSF (Helms et al., 2020; Kremer et al., 2020; Espindola et al., 2020; Kandemirli et al., 2020; Farhadian et al., 2020; Paterson et al., 2020; Remsik et al. 2020; Neumann et al., 2020; Andriuta et al., 2020; Bellon et al., 2020; Bodro et al. 2020; Pilotto, Odolini, et al., 2020; Frontera et al., 2021; Romero-Sanchez et al., 2020; Perrin et al., 2021; Cao et al., 2020; Franke et al., 2021; Alexopoulos et al. 2020; Keller et al., 2020; Miller et al., 2020; Pilotto et al., 2021; Eden et al., 2021). Accumulated data now include patients across a wide spectrum of neurological manifestations including several individuals with an increased CSF white blood cell (WBC) count and/or neuroimaging abnormalities indicating an inflammatory CNS syndrome. Most reports have used RT qPCR methods for viral detection, a technique that has a high degree of sensitivity in detecting viral genomes in CSF. In addition, attempts of viral culture and antigen detection of viral S1 protein IgG has been unsuccessful (Remsik et al. 2020; Farhadian et al., 2020; Pilotto et al., 2021). Thus, accumulating evidence suggests that SARS-CoV-2 is not present in the CSF compartment to any significant degree when patients present with neurological symptoms. Notably, most CSF samples reported on so far have been collected during the secondary inflammatory phase or in later stages of COVID-19, making it difficult to rule out that virus could be present in CSF early during the infectious process.

Autopsy studies have produced conflicting results regarding viral invasion in the brain (Hanley et al., 2020; Jensen et al., 2020; Paniz-Mondolfi et al., 2020; Skok et al., 2020). In a series of 18 patients with documented neurologic symptoms ante-mortem, viral RNA detection was equivocal, with low levels of SARS-CoV-2 RNA found in a minority of specimens while immunohistochemistry did not reveal staining in neurons, glia, endothelium, or immune cells. Samples did not show encephalitis or other changes referable to viral infection (Solomon et al., 2020). In a report on patients without specific neurological symptoms, 9/11 cerebral samples were positive for SARS-CoV-2 RNA but no signs of encephalitis were noted (Rommelink et al., 2020), while another series of nine patients revealed extensive brain inflammation most pronounced in the olfactory bulb and medulla oblongata,

without immunohistochemical signs of SARS-CoV-2 infected cells in brain tissue (Schurink et al., 2020). Similarly, multifocal microvascular injury and activation of perivascular microglia, macrophage infiltration, and hypertrophic astrocytes were described in 13 deceased patients with COVID-19 using high-resolution MRI and histopathological examination. Although clinical information regarding neurological manifestations was limited, no evidence of SARS-CoV-2 infection was found using multiple PCR primer sets, sequencing, in situ hybridization, or immunostaining (Lee et al., 2020).

In a large cohort of 43 patients, Matschke and colleagues also described pronounced neuroinflammatory changes most pronounced in the brainstem and cerebellum with astrogliosis, glial activation, and infiltration of cytotoxic T lymphocytes seen in most subjects. Notably, a history of neurological symptoms was not part of the study inclusion criteria. Despite this, SARS-CoV-2 RNA could be detected in 21/40 examined patients, and viral proteins were detected in cranial nerves and isolated cells in the brain stem indicating that SARS-CoV-2 can invade the CNS to some extent. Interestingly, detection of viral RNA or positive staining did not seem to correlate with the extent of neuropathological changes, suggesting that other mechanisms play an important part in CNS pathology rather than direct viral infection in the brain (Matschke et al., 2020). In summary, no uniform pattern regarding the pathogenetic contribution of viral CNS invasion has been described so far. Viral RNA detection in various brain tissues has been found without apparent histopathological correlates of infection, while CNS inflammation (notably in the olfactory bulb and brain stem) with microvascular injury and microglial activation have been found without any evidence of active infection by detection of viral particles or virus-infected cells.

The route of viral neuroinvasion has been proposed to occur at the olfactory neural-mucosal interface. In a recent study including 33 patients, SARS-CoV-2 RNA was detected by PCR in predominantly the olfactory mucosa in 20/30 patients. Viral RNA was also detected in several additional regions connected to the olfactory mucosa, including the olfactory bulb, olfactory tubercle, oral mucosa (uvula), trigeminal ganglion, medulla oblongata, and cerebellum in a more sporadic fashion (Meinhardt et al., 2021). Sub-genomic RNA was positive in a small subset of exclusively olfactory mucosal samples, although the significance of subgenomic RNA detection as an indicator of active viral replication is controversial (Dimcheff et al. 2021; Alexandersen et al., 2020). Additionally, SARS-CoV-2 S protein was found in cell types deemed to be of neuronal/neural origin using immunohistochemistry. Moreover, upregulation of human leucocyte antigen (HLA)-DR was seen in microglia/macrophages in a subset of samples, indicating a local innate CNS immune response. Taken together, findings support that SARS-CoV-2 is present at the neural-mucosal entry, although the extent of neuronal infection or subsequent axonal transport into the CNS remains uncertain (Meinhardt et al., 2021). While direct infection of neuronal cells as well as further migration of virus into the CNS needs further verification, viral interaction with the olfactory mucosa and infection of non-neuronal mucosal cells is the probable pathogenetic mechanism contributing to the anosmia that is frequently experienced in mild as well as severe COVID-19. Sustentacular cells, a supportive cell of

the olfactory mucosa important for maintaining the integrity and function of olfactory sensory neurons, have been shown to express ACE2 as well as TMPRSS2, indicating that these cells may be an important target of active viral infection (Brann et al., 2020; Fodoulian et al., 2020; Leist et al., 2020).

Neuroimaging findings in neuro-COVID include ischemic stroke, leptomeningeal enhancement, encephalitis, microvascular lesions, microhemorrhages, and others. However, MRI findings are divergent and often normal and do not clearly indicate a common mechanism of neuronal injury (Cao et al., 2020; Helms et al., 2020; Kandemirli et al., 2020; Kremer et al., 2020; Lersy et al., 2021; Lu et al., 2020; Meppiel et al., 2021; Pilotto et al., 2021; Saitta et al., 2020; Virhammar, Naas, et al., 2020).

Altogether, the neuroinvasive capabilities of SARS-CoV-2 remain difficult to evaluate. Viral genomes and particles can be found in brain tissue of patients with the disease, but neuropathologic correlates to infection are limited. Similarly, although viral RNA can be detected in the CSF of patients with neurological symptoms in rare cases, the vast majority of patients do not have evidence of ongoing viral replication within the CSF compartment and often lack typical signs seen in viral CNS infections.

6 | CSF AND SERUM BIOMARKERS OF CNS INVOLVEMENT IN COVID-19

While direct viral invasion remains uncertain, infection with SARS-CoV-2 can initiate an intense inflammatory response in the CNS as well as systemically. Although the mechanisms are not entirely clear, intrathecal immune activation is likely to a large extent an indirect consequence of the systemic inflammatory response including the cytokine release syndrome, leading to activation of CNS resident immune cells (Figure 1a). In addition, viral interaction with perivascular cells (pericytes or other) of the CNS capillary network may lead to endothelial activation that can contribute to intrathecal immune activation, as well as potentially BBB dysfunction and microvascular injuries that may further potentiate CNS immune responses (Figure 1b) (Perrin et al., 2021; Varga et al., 2020).

A limited number of studies have investigated the effects of COVID-19 on soluble inflammatory biomarkers in CSF. Increased concentrations of inflammatory cytokines or chemokines including IL-6, IL-8, TNF- α , and MCP-1 have been described in patients with encephalopathy or encephalitis in CSF or CSF and plasma during active SARS-CoV-2 infection (Bodro et al., 2020; Farhadian et al., 2020; Lersy et al., 2021; Virhammar, Naas, et al., 2020; Perrin et al., 2021; Pilotto et al., 2021). In a study including 13 patients with encephalitis, higher CSF concentrations of IL-1 β , IL-6, IL-8, TNF- α , and β 2 M as well as the glial activation markers GFAP, sTREM2, and YKL-40 were found compared to healthy controls (Pilotto et al., 2021). Levels were comparable to those found in patients with non-COVID encephalitis, except for the B cell chemoattractant chemokine (C-X-C motif) ligand 13 (CXCL13). Interestingly, CXCL13 was normal in patients with COVID-encephalitis but increased in other types of infectious

encephalitis, suggesting a different mechanism perhaps not associated with direct CNS infection in the pathogenesis of neuro-COVID (Pilotto et al., 2021). We have also reported increased concentrations of CSF β 2 M in patients with moderate or severe COVID-19 and neurological symptoms. Additionally, high concentrations of CSF neopterin were found, indicating profound microglial or immune cell activation within the CNS (Eden et al., 2021). Interestingly, other typical signs of CNS infection including elevated CSF WBC count, BBB/blood-CSF barrier injury, or intrathecal IgG synthesis were absent, further supporting the important differences in the pathobiology of CNS disease in COVID-19 (Eden et al., 2021).

CSF WBC count is often within normal limits, especially in patients with encephalopathy (Eden et al., 2021; Frontera et al., 2021; Kandemirli et al., 2020; Neumann et al., 2020; Virhammar, Naas, et al., 2020). CSF pleocytosis is usually included as one of the diagnostic criteria for encephalitis, where a low or moderate increase in CSF WBC count has been reported in several studies (Espindola et al., 2020; Moriguchi et al., 2020; Kremer et al., 2020; Bellon et al., 2020; Bodro et al., 2020; Pilotto, Masciocchi, et al., 2021; Pilotto et al., 2021; Frontera et al., 2021; Lersy et al., 2021; Meppiel et al., 2021; Miller et al., 2020; Virhammar, Naas, et al., 2020; Franke et al., 2021).

Interestingly, the presence of macrophages in CSF was observed in a majority of subjects in one study, indicating microglial activation resembling mechanisms described in septic encephalopathy (Bellon et al., 2020). In addition to CSF pleocytosis, elevated CSF protein has been reported in patients with encephalopathy as well as encephalitis or inflammatory CNS syndromes in several studies (Andriuta et al., 2020; Bellon et al., 2020; Cao et al., 2020; Espindola et al., 2020; Franke et al., 2021; Frontera et al., 2021; Helms et al., 2020; Kandemirli et al., 2020; Kremer et al., 2020; Lersy et al., 2021; Miller et al., 2020; Paterson et al., 2020; Pilotto, Masciocchi, et al., 2021; Pilotto et al., 2021).

While viral interaction with the capillary endothelium or perivascular cells may be a trigger of immune activation in the CNS, BBB or blood-CSF barrier integrity appears to be mostly intact in most patients with neuro-COVID. However, an increased albumin quotient has been described in several studies with varying frequencies (Alexopoulos et al., 2020; Bellon et al., 2020; Lersy et al., 2021; Saitta et al., 2020; Virhammar, Naas, et al., 2020; Perrin et al., 2021) and has been associated with critical disease (Neumann et al., 2020). However, evidence of microvascular injuries and microhemorrhages clearly indicates the potential contribution of virus-induced vascular injury to CNS pathogenesis in COVID-19 (Lee et al., 2020; Meppiel et al., 2021; Saitta et al., 2020). Local BBB damage not measurable in routine analyses may still contribute to the immune reaction in neuro-COVID patients. CSF sPDGFR β is abundantly expressed in brain pericytes and is an interesting new biomarker that may be useful in the evaluation of BBB function (Miners et al., 2019; Nation et al., 2019; Sagare et al., 2015). However, data on CSF sPDGFR β in patients with COVID-19 are still very limited.

Oligoclonal bands can be found in patients with encephalopathy as well as encephalitis (Bellon et al., 2020; Espindola et al., 2020;

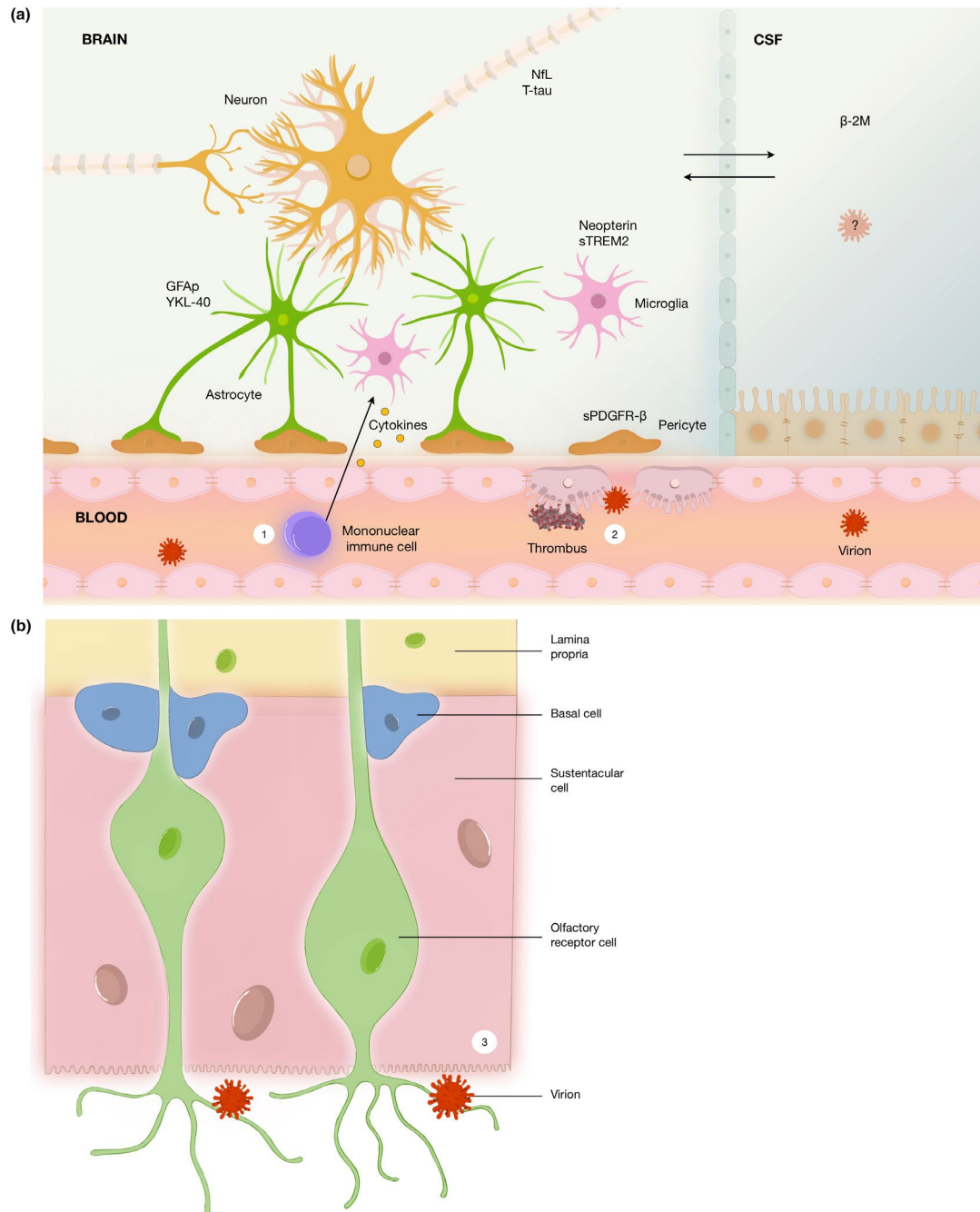


FIGURE 1 (a, b) Model of main contributing mechanisms in COVID-19 CNS pathogenesis and associated neurochemical biomarkers. Viral RNA is rarely detected in CSF in patients with neurological manifestations during COVID-19. Current evidence indicates that the main contributing mechanisms to CNS pathology in SARS-CoV-2 infection are (A:1) indirect effects of the systemic immune responses leading to activation of CNS-resident immune cells; (A:2) the pro-thrombotic state and virus-induced endothelitis possibly via infection of pericytes; and (B:3) direct viral interaction with neuronal and/or supportive cells of the olfactory mucosa. CNS immune activation can be measured using CSF biomarkers of glial/macrophage (neopterin, sTREM-2) and astrocyte (GFAP, YKL-40) activation. CSF β2 M is a useful but unspecific marker of cellular activation. Markers of neuroaxonal injury include NfL and tau. CSF sPDGFR-β is a new candidate biomarker for BBB function and is highly expressed in brain pericytes. Abbreviations: GFAP, Glial fibrillary acidic protein; YKL-40, chitinase-3-like-protein; PDGFR-β, soluble platelet-derived growth factor receptor β; sTREM-2, soluble ectodomain of triggering receptor expressed on myeloid cells; β2 M, β2-microglobulin; NfL, neurofilament light; CSF, cerebrospinal fluid

Franke et al., 2021; Helms et al., 2020; Kremer et al., 2020; Lersy et al., 2021; Neumann et al., 2020; Paterson et al., 2020; Virhammar, Naas, et al., 2020). In a majority of cases, identical bands are found in serum (type IV oligoclonal bands) indicating that humoral responses

are peripheral and passively transported to the CNS, although CSF specific oligoclonal bands indicating intrathecal production has been described in a handful of patients (Espindola et al., 2020; Lersy et al., 2021; Virhammar, Naas, et al., 2020). CSF anti-SARS-CoV-2



IgG has been detected in patients with varying manifestations of neuro-COVID, but again, signs of CNS-specific intrathecal production are rare (Alexopoulos et al. 2020; Andriuta et al., 2020; Bellon et al., 2020; Franke et al., 2021; Virhammar, Naas, et al., 2020). Similarly, an elevated IgG index indicating intrathecal antibody production is rarely seen (Alexopoulos et al. 2020; Bellon et al., 2020; Eden et al., 2021; Helms et al., 2020). Although the timing of CSF sampling may potentially influence these results, available data including patients with CSF samples drawn several weeks after disease onset does not indicate that SARS-CoV-2 generally induces a specific intrathecal B-cell response, but rather a systemic antibody production that is also measurable in CSF. The normal levels of CXCL13 found in COVID encephalitis patients also suggest that SARS-CoV-2 infection does not generally induce B cell specific responses in the CNS (Pilotto et al., 2021).

Biomarkers of axonal injury such as NfL or tau and markers of astroglial activation and injury (GFAP) can provide important information on the consequences of COVID-19 on the CNS. However, available data is still limited in neuro-COVID patients. Increased concentrations of CSF NfL has been found in a subset of severely/critically ill patients with encephalopathy (Eden et al., 2021; Espindola et al., 2020; Franke et al., 2021; Pilotto et al., 2021; Virhammar, Naas, et al., 2020) and was correlated to disease severity in one report (Virhammar, Naas, et al., 2020). Very high concentrations of NfL, tau, and GFAP were found in one patient with COVID-19 with acute necrotizing encephalopathy (ANE), consistent with the underlying diagnosis (Virhammar, Kumlien, et al., 2020). Increased CSF concentrations of tau and GFAP has also been described in patients with encephalopathy or encephalitis, indicating that SARS-CoV-2 infection can result in axonal and astroglial injury in some individuals (Pilotto et al., 2021; Virhammar, Naas, et al., 2020).

In a study of 47 patients with mild to severe COVID-19, we found increased concentrations of plasma GFAP in patients with moderate and of plasma GFAP and NfL in patients with severe COVID-19, while patients with mild disease had normal levels compared to uninfected controls (Kanberg et al., 2020). Concentrations of GFAP decreased on follow-up, while NfL showed a sustained increase, perhaps representing an early astrocytic response to infection followed by a more delayed axonal injury. Neurological symptoms were noted only in a minority of included patients (5/18 with severe disease). Although peripheral axonal injury can potentially contribute to increased plasma concentrations of NfL and GFAP, a strong correlation between plasma and CSF concentration was seen in patients with neurological symptoms, suggesting that plasma levels parallel CSF levels in patients with neuro-COVID (Virhammar, Naas, et al., 2020). In critically ill patients treated in the ICU, significantly higher plasma GFAP was seen in patients with COVID-19 than in patients with respiratory failure due to other causes (Cooper et al., 2020). Higher plasma NfL was also seen in patients with delirium. However, patients with COVID-19 were older than controls and the number of patients were small, making the evaluation of results uncertain (Cooper et al., 2020). Higher serum NfL was also seen in 29 COVID-19 ICU patients compared to 10 general ICU patients after

adjusting for neurological comorbidities and age (Sutter et al., 2020). Although these studies are limited in size, results may indicate that additional neuronal damage can potentially be associated with COVID-19 beyond what is seen in a non-COVID-19 ICU population.

In summary, even if other factors such as hypoxemia or thromboembolic events likely contribute to the neuro-axonal and astroglial injury seen in recent reports, accumulating evidence indicates that SARS-CoV-2 infection generates a marked immune response within the CNS in a significant number of patients with varying disease severity and degree of neurological manifestations, leading to neuro-axonal and astroglial injury in patients with the severe or critical disease. The extent of neuro-axonal injury in patients with the less severe disease remains to be further characterized.

7 | DISCUSSION

Although CNS manifestations are common, the pathogenetic mechanisms by which SARS-CoV-2 infection affects the CNS are still under investigation. Different models have been proposed, including non-specific complications to systemic disease such as hypoxemia and systemic inflammatory responses, direct viral damage to neuronal tissues due to neuroinvasion, or indirect damage as a consequence of excessive immune activation (Ellul et al., 2020). While different mechanisms can all contribute to the disease manifestations of individual patients, accumulating evidence points to the specific importance of immune-mediated mechanisms as a key component in neuro-COVID. Signs of immune activation are evident in studies of CSF biomarkers in patients with neurological symptoms as well as in autopsy studies, while findings typically associated with CNS infections – CSF pleocytosis, BBB or blood-CSF barrier disruption, intrathecal humoral responses, or pathological signs of meningitis or encephalitis – are typically mild or missing and viral RNA remains undetectable in CSF in the absolute majority of subjects. Glial cell activation because of pro-inflammatory cytokine release induced by the systemic response to SARS-CoV-2 infection appears to be of central importance in patients with neuro-COVID. A similar mechanism has been described in immune effector cell-associated neurotoxicity syndrome (ICANS) following CAR- T cell therapy, where a cytokine release syndrome with high CSF concentrations of IL-6, IL-8, and TNF- α induces a glial cell mediated neuroinflammation (Gust et al., 2019; Lee et al., 2019; Santomaso et al., 2018). Inflammatory mediators can likely act directly across the BBB to induce neuroinflammation via astrocyte and microglia activation leading to inflammatory-mediated injury in the CNS (Gust et al., 2019). Moreover, viral interaction with perivascular cells via ACE2 can lead to endothelitis with further exacerbation of inflammatory responses (Varga et al., 2020; Zubair et al., 2020), and microvascular injuries probably related to endothelitis have been described in patients with COVID-19 (Lee et al., 2020; Meppiel et al., 2021; Saitta et al., 2020). Accordingly, glial and cellular activation markers, including CSF neopterin, β 2 M, sTREM2, and GFAP, have been found to be markedly and consistently increased in CSF studies of neuro-COVID patients



(Eden et al., 2021; Pilotto et al., 2021), although significant disruption of BBB or blood-CSF barrier integrity is less common. Indeed, we have found high concentrations of CSF neopterin in every patient with neuro-COVID studied up to this point.

Further indications of the importance of immune-mediated mechanisms in the pathogenesis of neuro-COVID include recent findings of T cell exhaustion and monocyte dedifferentiation in the CSF of 8 neuro-COVID patients with moderate to severe disease. An attenuated interferon-response was seen in comparison to other types of viral encephalitis patients, indicating local immune overactivation despite the absence of detectable virus in the CSF (Heming et al., 2021). Additionally, anti-neuronal antibodies have been detected in 11 critically ill patients with neuro-COVID, possibly suggesting that SARS-CoV-2 induced inflammation may lead to the generation of autoantibodies similar to anti-NMDAR antibodies seen after herpes simplex virus encephalitis (Franke et al., 2021). The potential importance of autoantibodies in patients with long-term sequelae after acute infection remains an interesting area for future studies.

The importance of the immune response in the pathogenesis of neuro-COVID has important therapeutic as well as scientific implications. The lack of detectable virus in CSF during acute neuro-COVID-19 suggests that the potential usefulness of antiviral therapy may be limited. Unlike persistent infections, such as human immunodeficiency virus type 1 (HIV-1) or reactivated infections caused by *Herpesviridae*, the therapeutic potential for antiviral efficacy in SARS-CoV-2 infection is likely greatest during very early symptomatic or presymptomatic infection. However, it is of utmost importance that future clinical trials of potential drug candidates include evaluation of CNS performance and effectiveness in relation to neurological manifestations of COVID-19. While direct antiviral therapy may be of limited use, interventions targeting the CNS immune response and other processes initiated by the infection have the potential to modulate and ameliorate CNS symptoms, as well as the respiratory or systemic inflammatory responses currently being targeted. Immunomodulatory therapies have been used in patient care in a limited number of reports (Freire-Alvarez et al., 2020; Perrin et al., 2021; Romero-Sanchez et al., 2020; Wang et al., 2020), but results are anecdotal and properly designed and powered clinical trials are essential to improve the clinical management of patients with neuro-COVID.

CSF and plasma biomarkers of CNS immune activation and injury also have the potential to be useful in the clinical management of individual patients. Although CSF sampling is not routinely done, and the availability of CSF analyses is often limited locally, serum or plasma biomarkers can provide important information on CNS responses during infection. For instance, serum neopterin has been evaluated as a prognostic biomarker and has been associated with disease severity (Ozger et al., 2020; Robertson et al., 2020) as well as the risk for ICU admission, need for mechanical ventilation, and death (Bellmann-Weiler et al., 2021). Perhaps more interestingly, plasma NFL indicating neuro-axonal injury has

been associated with disease severity and unfavorable outcome (Kanberg et al., 2020; Sutter et al., 2020) and might potentially be of prognostic use for evaluating the risk for neuronal injury or neurological sequelae. In addition, exploratory approaches applied to CSF of well-defined patients have the potential to reveal important information regarding pathogenetic mechanisms as well as the identification of useful clinical biomarkers during neuro-COVID (Remsik et al. 2020).

8 | CONCLUSION

The neurological impact of SARS-CoV-2 is significant during acute infection, and the severity of neurological manifestations is often, but not always, linked to the severity of COVID-19. Although the virus does not seem to be neuroinvasive in most individuals, nevertheless infection with SARS-CoV-2 generates significant immunological responses as well as evidence of neuronal injury within the CNS. These findings may have important implications for therapeutic interventions, as well as future research efforts. In this review, we highlighted the potential importance of utilizing CSF as well as blood biomarkers to increase our understanding of the CNS responses to infection, and in the characterization of neuropathogenic processes related to COVID-19. In addition to aiding as diagnostic and prognostic tools during acute infection, the use of comprehensive and well-characterized CSF and blood biomarkers will likely be very useful in understanding the potential impact on the CNS in the rapidly increasing number of individuals recovering from COVID-19.

DATA AVAILABILITY STATEMENT

Data sharing is not applicable to this article as no new data were created or analyzed in this study.

ACKNOWLEDGEMENTS

The authors kindly thank Nora Odqvist for illustrating the figures featured in this article. This work was supported by the Swedish state, under an agreement between the Swedish government and the county councils (ALF agreement ALFGBG-717531); and by SciLifeLab Sweden (KAW 2020.0182). HZ is a Wallenberg Scholar supported by grants from the Swedish Research Council (#2018-02532), the European Research Council (#681712), Swedish State Support for Clinical Research (#ALFGBG-720931), the Alzheimer Drug Discovery Foundation (ADDF), USA (#201809-2016862), the AD Strategic Fund and the Alzheimer's Association (#ADSF-21-831376-C, #ADSF-21-831381-C and #ADSF-21-831377-C), the Olav Thon Foundation, the Erling-Persson Family Foundation, Stiftelsen för Gamla Tjänarinnor, Hjärnfonden, Sweden (#FO2019-0228), the European Union's Horizon 2020 research and innovation programme under the Marie Skłodowska-Curie grant agreement No 860197 (MIRIAD), and the UK Dementia Research Institute at UCL. JS has received research support from Stohnes stiftelse and Stiftelsen för Gamla Tjänarinnor.



CONFLICTS OF INTEREST

HZ has served at scientific advisory boards for Eisai, Denali, Roche Diagnostics, Wave, Samumed, Siemens Healthineers, Pinteon Therapeutics, Nervgen, AZTherapies, and CogRx, has given lectures in symposia sponsored by Cellectricon, Fujirebio, Alzecure, and Biogen, and is a co-founder of Brain Biomarker Solutions in Gothenburg AB (BBS), which is a part of the GU Ventures Incubator Program (outside submitted work). MG has received research grants from Gilead Sciences and Janssen-Cilag and honoraria as a speaker and/or scientific advisor from Amgen, Biogen, Bristol-Myers Squibb, Gilead Sciences, GlaxoSmithKline/ViiV, Janssen-Cilag, MSD, Novocure, and Novo Nordic. AE, JS, and RWP report no conflicts of interest.

AUTHOR CONTRIBUTIONS

AE and MG conceived the report. AE acquired the data with assistance from JS and MG. AE drafted the initial manuscript. All authors contributed to data interpretation and revision and editing of the manuscript.

ORCID

Arvid Edén  <https://orcid.org/0000-0003-2817-9981>

Joel Simrén  <https://orcid.org/0000-0001-5081-6604>

Henrik Zetterberg  <https://orcid.org/0000-0003-3930-4354>

Magnus Gisslén  <https://orcid.org/0000-0002-2357-1020>

REFERENCES

- Alexandersen, S., Chamings, A., & Bhatta, T. R. (2020). SARS-CoV-2 genomic and subgenomic RNAs in diagnostic samples are not an indicator of active replication. *Nature Communications*, 11, 6059. <https://doi.org/10.1038/s41467-020-19883-7>
- Alexopoulos, H., Magira, E., Bitzogli, K., Kafasi, N., Vlachoyiannopoulos, P., Tzioufas, A., Kotanidou, A., & Dalakas, M. C. (2020). Anti-SARS-CoV-2 antibodies in the CSF, blood-brain barrier dysfunction, and neurological outcome. *Neurology - Neuroimmunology Neuroinflammation*, 7(6), e893.
- Altmann, P., De Simoni, D., Kaider, A., Ludwig, B., Rath, J., Leutmezer, F., Zimprich, F., Hoeflberger, R., Lunn, M. P., Heslegrave, A., Berger, T., Zetterberg, H., & Rommer, P. S. (2020). Increased serum neurofilament light chain concentration indicates poor outcome in Guillain-Barre syndrome. *Journal of Neuroinflammation*, 17, 86.
- Anderson, A. M., Jang, J. H., Easley, K. A., Fuchs, D., Gisslen, M., Zetterberg, H., Blennow, K., Ellis, R. J., Franklin, D., Heaton, R. K., Grant, I., & Letendre, S. L. (2020). Cognitive and neuronal link with inflammation: A longitudinal study in people with and without HIV infection. *Journal of Acquired Immune Deficiency Syndromes*, 85, 617–625. <https://doi.org/10.1097/QAI.0000000000002484>
- Andriuta, D., Roger, P. A., Thibault, W., Toubanc, B., Sauzay, C., Castelain, S., Godefroy, O., & Brochot, E. (2020). COVID-19 encephalopathy: Detection of antibodies against SARS-CoV-2 in CSF. *Journal of Neurology*, 267, 2810–2811. <https://doi.org/10.1007/s00415-020-09975-1>
- Ashton, N. J., Suarez-Calvet, M., Heslegrave, A., Hye, A., Razquin, C., Pastor, P., Sanchez-Valle, R., Molinuevo, J. L., Visser, P. J., Blennow, K., Hodges, A. K., & Zetterberg, H. (2019). Plasma levels of soluble TREM2 and neurofilament light chain in TREM2 rare variant carriers. *Alzheimer's Research & Therapy*, 11, 94.
- Axelsson, M., Sjogren, M., Andersen, O., Blennow, K., Zetterberg, H., & Lycke, J. (2018). Neurofilament light protein levels in cerebrospinal

fluid predict long-term disability of Guillain-Barre syndrome: A pilot study. *Acta Neurologica Scandinavica*, 138, 143–150.

- Bellmann-Weiler, R., Lanser, L., Burkert, F., Seiwald, S., Fritsche, G., Wildner, S., Schroll, A., Koppelstatter, S., Kurz, K., Griesmacher, A., & Weiss, G. (2021). Neopterin predicts disease severity in hospitalized patients with COVID-19. *Open Forum. Infectious Diseases*, 8, ofaa521.
- Bellon, M., Schwebelin, C., Lambeng, N., Cherpillod, P., Vazquez, J., Lalive, P. H., Schibler, M., & Deffert, C. (2020). Cerebrospinal fluid features in SARS-CoV-2 RT-PCR positive patients. *Clinical infectious diseases: an official publication of the Infectious Diseases Society of America*
- Berger, J. R., Pall, L., Lanska, D., & Whiteman, M. (1998). Progressive multifocal leukoencephalopathy in patients with HIV infection. *Journal of Neurovirology*, 4, 59–68. <https://doi.org/10.3109/13550289809113482>
- Beyroufi, R., Adams, M. E., Benjamin, L., Cohen, H., Farmer, S. F., Goh, Y. Y., Humphries, F., Jager, H. R., Losseff, N. A., Perry, R. J., Shah, S., Simister, R. J., Turner, D., Chandratheva, A., & Werring, D. J. (2020). Characteristics of ischaemic stroke associated with COVID-19. *Journal of Neurology, Neurosurgery and Psychiatry*, 91, 889–891.
- Blennow, K., Hampel, H., Weiner, M., & Zetterberg, H. (2010). Cerebrospinal fluid and plasma biomarkers in Alzheimer disease. *Nature Reviews Neurology*, 6, 131–144. <https://doi.org/10.1038/nrneuro.2010.4>
- Bodro, M., Compta, Y., Llanso, L., Esteller, D., Doncel-Moriano, A., Mesa, A., Rodriguez, A., Sarto, J., Martinez-Hernandez, E., Vlasea, A., Egri, N., Filella, X., Morales-Ruiz, M., Yague, J., Soriano, A., Graus, F., & Garcia, F. (2020). Increased CSF levels of IL-1beta, IL-6, and ACE in SARS-CoV-2-associated encephalitis. *Neurol Neuroimmunol Neuroinflamm*, 7, e821. <https://doi.org/10.1212/NXI.0000000000000821>
- Bonneh-Barkay, D., Wang, G., Starkey, A., Hamilton, R. L., & Wiley, C. A. (2010). In vivo CHI3L1 (YKL-40) expression in astrocytes in acute and chronic neurological diseases. *Journal of Neuroinflammation*, 7, 34. <https://doi.org/10.1186/1742-2094-7-34>
- Brann, D. H., Tsukahara, T., Weinreb, C., Lipovsek, M., Van den Berge, K., Gong, B., Chance, R., Macaulay, I. C., Chou, H.-J., Fletcher, R. B., Das, D., Street, K., de Bezieux, H. R., Choi, Y.-G., Rizzo, D., Dudoit, S., Purdom, E., Mill, J., Hachem, R. A., ... Datta, S. R. (2020). Non-neuronal expression of SARS-CoV-2 entry genes in the olfactory system suggests mechanisms underlying COVID-19-associated anosmia. *Science Advances*, 6, eabc5801. <https://doi.org/10.1126/sciadv.abc5801>
- Brettschneider, J., Claus, A., Kassubek, J., & Tumani, H. (2005). Isolated blood-cerebrospinal fluid barrier dysfunction: Prevalence and associated diseases. *Journal of Neurology*, 252, 1067–1073. <https://doi.org/10.1007/s00415-005-0817-9>
- Bridel, C., van Wieringen, W. N., Zetterberg, H., Tijms, B. M., Teunissen, C. E., Alvarez-Cermeño, J. C., Andreasson, U., Axelsson, M., Bäckström, D. C., Bartos, A., Bjerke, M., Blennow, K., Boxer, A., Brundin, L., Burman, J., Christensen, T., Fialová, L., Forsgren, L., Frederiksen, J. L., ... Wild, E. J. (2019). Diagnostic value of cerebrospinal fluid neurofilament light protein in neurology: A systematic review and meta-analysis. *JAMA Neurology*, 76, 1035–1048.
- Busch, M. P., Kleinman, S. H., Tobler, L. H., Kamel, H. T., Norris, P. J., Walsh, I., Matud, J. L., Prince, H. E., Lanciotti, R. S., Wright, D. J., Linnen, J. M., & Caglioti, S. (2008). Virus and antibody dynamics in acute west nile virus infection. *The Journal of Infectious Diseases*, 198, 984–993. <https://doi.org/10.1086/591467>
- Cao, A., Rohaut, B., Le Guennec, L., Saheb, S., Marois, C., Altmayer, V., Carpentier, V. T., Nemlaghi, S., Soulie, M., Morlon, Q., Berthet-Delteil, B., Bleibtreu, A., Raux, M., Weiss, N., & Demeret, S. (2020). Severe COVID-19-related encephalitis can respond to immunotherapy. *Brain*, 143, e102. <https://doi.org/10.1093/brain/awaa337>

- Carfi, A., Bernabei, R., Landi, F., & Gemelli Against, C.-P.-A.- C.- S.- G. (2020). Persistent symptoms in patients after acute COVID-19. *JAMA*, 324, 603–605. <https://doi.org/10.1001/jama.2020.12603>
- Cooper, J., Stukas, S., Hoiland, R. L., Fergusson, N. A., Thiara, S., Foster, D., Mitra, A., Stoessel, J. A., Panenka, W. J., Sekhon, M. S., & Wellington, C. L. (2020). Quantification of neurological blood-based biomarkers in critically ill patients with coronavirus disease 2019. *Critical Care Explorations*, 2, e0238. <https://doi.org/10.1097/CCE.0000000000000238>
- Cotto, B., Natarajaseenivasan, K., & Langford, D. (2019). Astrocyte activation and altered metabolism in normal aging, age-related CNS diseases, and HAND. *Journal of Neurovirology*, 25, 722–733.
- Dimcheff, D. E., Valesano, A. L., Rumpf, K. E., Fitzsimmons, W. J., Blair, C., Mirabelli, C., Petrie, J. G., Martin, E. T., Bhamhani, C., Tewari, M., & Luring, A. S. (2021). SARS-CoV-2 total and subgenomic RNA viral load in hospitalized patients. *The Journal of Infectious Diseases*. <https://doi.org/10.1093/infdis/jiab215>
- Dittrich, T., Marsch, S., Egli, A., Ruegg, S., De Marchis, G. M., Tschudin-Sutter, S., & Sutter, R. (2020). Predictors of infectious meningitis or encephalitis: The yield of cerebrospinal fluid in a cross-sectional study. *BMC Infectious Diseases*, 20, 304. <https://doi.org/10.1186/s12879-020-05022-6>
- Domingues, R. B., Mendes-Correa, M. C., de Moura Leite, F. B. V., Sabino, E. C., Salarini, D. Z., Claro, I., Santos, D. W., de Jesus, J. G., Ferreira, N. E., Romano, C. M., & Soares, C. A. S. (2020). First case of SARS-CoV-2 sequencing in cerebrospinal fluid of a patient with suspected demyelinating disease. *Journal of Neurology*, 267, 3154–3156. <https://doi.org/10.1007/s00415-020-09996-w>
- Edén, A., Kanberg, N., Gostner, J., Fuchs, D., Hagberg, L., Andersson, L.-M., Lindh, M., Price, R. W., Zetterberg, H., & Gisslén, M. (2021). CSF biomarkers in patients with COVID-19 and neurological symptoms: A case series. *Neurology*, 96, e294–e300. <https://doi.org/10.1212/WNL.0000000000010977>
- Ellul, M. A., Benjamin, L., Singh, B., Lant, S., Michael, B. D., Easton, A., Kneen, R., Defres, S., Sejvar, J., & Solomon, T. (2020). Neurological associations of COVID-19. *The Lancet Neurology*, 19, 767–783. [https://doi.org/10.1016/S1474-4422\(20\)30221-0](https://doi.org/10.1016/S1474-4422(20)30221-0)
- Espindola, O. M., Brandão, C. O., Gomes, Y. C. P., Siqueira, M., Soares, C. N., Lima, M. A. S. D., Leite, A. C. C. B., Torezani, G., Araujo, A. Q. C., & Silva, M. T. T. (2020). Cerebrospinal fluid findings in neurological diseases associated with COVID-19 and insights into mechanisms of disease development. *International Journal of Infectious Diseases*, 102, 155–162. <https://doi.org/10.1016/j.ijid.2020.10.044>
- Farhadian, S., Glick, L. R., Vogels, C. B. F., Thomas, J., Chiarella, J., Casanovas-Massana, A., Zhou, J., Odio, C., Vijayakumar, P., Geng, B., Fournier, J., Bermejo, S., Fauver, J. R., Alpert, T., Wyllie, A. L., Turcotte, C., Steinle, M., Paczkowski, P., Dela Cruz, C., ... Barakat, L. A. (2020). Acute encephalopathy with elevated CSF inflammatory markers as the initial presentation of COVID-19. *BMC Neurology*, 20, 248. <https://doi.org/10.1186/s12883-020-01812-2>
- Fodoulian, L., Tuberosa, J., Rossier, D., Boillat, M., Kan, C., Pauli, V., Egervari, K., Lobrinus, J. A., Landis, B. N., Carleton, A., & Rodriguez, I. (2020). SARS-CoV-2 receptors and entry genes are expressed in the human olfactory neuroepithelium and Brain. *iScience*, 23(12), 101839. <https://doi.org/10.1016/j.isci.2020.101839>
- Franke, C., Ferse, C., Kreye, J., Reincke, S. M., Sanchez-Sendin, E., Rocco, A., Steinbrenner, M., Angermair, S., Treskatsch, S., Zickler, D., Eckardt, K.-U., Dersch, R., Hosp, J., Audebert, H. J., Endres, M., Ploner, J. C., & Prüss, H. (2021). High frequency of cerebrospinal fluid autoantibodies in COVID-19 patients with neurological symptoms. *Brain, Behavior, and Immunity*, 93, 415–419.
- Freire-Alvarez, E., Guillen, L., Lambert, K., Baidez, A., Garcia-Quesada, M., Andreo, M., Alom, J., Masia, M., & Gutierrez, F. (2020). COVID-19-associated encephalitis successfully treated with combination therapy. *Clinical Infection in Practice*, 7, 100053.
- Frontera, J. A., Sabadia, S., Lalchan, R., Fang, T., Flusty, B., Millar-Verneti, P., Snyder, T., Berger, S., Yang, D., Granger, A., Morgan, N., Patel, P., Gutman, J., Melmed, K., Agarwal, S., Bokhari, M., Andino, A., Valdes, E., Omari, M., & Galetta, S. (2021). A prospective study of neurological disorders in hospitalized COVID-19 patients in New York City. *Neurology*, 96, e575–e586.
- Fuchs, D., Kramer, A., Reibnegger, G., Werner, E. R., Dierich, M. P., Goedert, J. J., & Wachter, H. (1991). Neopterin and beta 2-microglobulin as prognostic indices in human immunodeficiency virus type 1 infection. *Infection*, 19(Suppl 2), S98–102.
- Gendron, T. F., Badi, M. K., Heckman, M. G., Jansen-West, K. R., Vilanilam, G. K., Johnson, P. W., Burch, A. R., Walton, R. L., Ross, O. A., Brott, T. G., Miller, T. M., Berry, J. D., Nicholson, K. A., Wszolek, Z. K., Oskarsson, B. E., Sheth, K. N., Sansing, L. H., Falcone, G. J., Cucchiara, B. L., ... Petrucelli, L. (2020). Plasma neurofilament light predicts mortality in patients with stroke. *Science Translational Medicine*, 12, eaay1913. <https://doi.org/10.1126/scitranslmed.aay1913>
- Gerkin, R. C., Ohla, K., Veldhuizen, M. G., Joseph, P. V., Kelly, C. E., Bakke, A. J., Steele, K. E., Farruggia, M. C., Pellegrino, R., Pepino, M. Y., Bouysset, C., Soler, G. M., Pereda-Loth, V., Dibattista, M., Cooper, K. W., Croijmans, I., Di Pizio, A., Ozdener, M. H., Fjaeldstad, A. W., ... Baguma, M. (2021). Recent smell loss is the best predictor of COVID-19 among individuals with recent respiratory symptoms. *Chemical Senses*, 46, bja081. <https://doi.org/10.1093/chemse/bjaa081>
- Giacomelli, A., Pezzati, L., Conti, F., Bernacchia, D., Siano, M., Oreni, L., Rusconi, S., Gervasoni, C., Ridolfo, A. L., Rizzardini, G., Antinori, S., & Galli, M. (2020). Self-reported olfactory and taste disorders in patients with severe acute respiratory coronavirus 2 infection: A cross-sectional study. *Clinical Infectious Diseases: An Official Publication of the Infectious Diseases Society of America*, 71, 889–890.
- Gisslén, M., Hagberg, L., Rosengren, L., Brew, B. J., Cinque, P., Spudich, S., & Price, R. W. (2007). Defining and evaluating HIV-related neurodegenerative disease and its treatment targets: A combinatorial approach to use of cerebrospinal fluid molecular biomarkers. *Journal of Neuroimmune Pharmacology: The Official Journal of the Society on NeuroImmune Pharmacology*, 2, 112–119.
- Gisslén, M., Price, R. W., Andreasson, U., Norgren, N., Nilsson, S., Hagberg, L., Fuchs, D., Spudich, S., Blennow, K., & Zetterberg, H. (2016). Plasma concentration of the neurofilament light protein (NFL) is a biomarker of CNS injury in HIV infection: A cross-sectional study. *EBioMedicine*, 3, 135–140.
- Guendouz, C., Quenardelle, V., Riou-Comte, N., Welfringer, P., Wolff, V., Zuily, S., Jager, L., Humbertjean Selton, L., Mione, G., Pop, R., Gory, B., & Richard, S. (2021). Pathogeny of cerebral venous thrombosis in SARS-Cov-2 infection: Case reports. *Medicine (Baltimore)*, 100, e24708.
- Gupta, N., Agrawal, S., Ish, P., Mishra, S., Gaiind, R., Usha, G., Singh, B., Sen, M. K. & Covid Working Group, S. H. (2020) Clinical and epidemiologic profile of the initial COVID-19 patients at a tertiary care centre in India. *Monaldi Archives for Chest Disease*, 90. <https://doi.org/10.4081/monaldi.2020.1294>
- Gust, J., Finney, O. C., Li, D., Brakke, H. M., Hicks, R. M., Futrell, R. B., Gamble, D. N., Rawlings-Rhea, S. D., Khalatbari, H. K., Ishak, G. E., Duncan, V. E., Hevner, R. F., Jensen, M. C., Park, J. R., & Gardner, R. A. (2019). Glial injury in neurotoxicity after pediatric CD19-directed chimeric antigen receptor T cell therapy. *Annals of Neurology*, 86, 42–54. <https://doi.org/10.1002/ana.25502>
- Hagberg, L., Cinque, P., Gisslén, M., Brew, B. J., Spudich, S., Bestetti, A., Price, R. W., & Fuchs, D. (2010). Cerebrospinal fluid neopterin: an informative biomarker of central nervous system immune activation in HIV-1 infection. *AIDS Research and Therapy*, 7, 15.
- Halpin, S. J., Mclvor, C., Whyatt, G., Adams, A., Harvey, O., McLean, L., Walshaw, C., Kemp, S., Corrado, J., Singh, R., Collins, T., O'Connor, R. J., & Sivan, M. (2020). Postdischarge symptoms and rehabilitation needs in survivors of COVID-19 infection: A cross-sectional evaluation. *Journal of Medical Virology*, 93(2), 1013–1022. <https://doi.org/10.1002/jmv.26368>



- Hanley, B., Naresh, K. N., Roufousse, C., Nicholson, A. G., Weir, J., Cooke, G. S., Thursz, M., Manousou, P., Corbett, R., Goldin, R., Al-Sarraj, S., Abdolrasouli, A., Swann, O. C., Baillon, L., Penn, R., Barclay, W. S., Viola, P., & Osborn, M. (2020). Histopathological findings and viral tropism in UK patients with severe fatal COVID-19: A post-mortem study. *The Lancet Microbe*, 1(6), e245–e253. [https://doi.org/10.1016/S2666-5247\(20\)30115-4](https://doi.org/10.1016/S2666-5247(20)30115-4)
- He, L., Mäe, M. A., Muhl, L., Sun, Y., Pietilä, R., Nahar, K., Liébanas, E. V., & Fagerlund, M., Oldner, A., Liu, J., Genové, G., Zhang, L., Xie, Y., Leptidis, S., Mocci, G., Stritt, S., Osman, A., Anisimov, A., Hemanthakumar, K. A., & Räsänen, M., & Betsholtz, C. (2020). Pericyte-specific vascular expression of SARS-CoV-2 receptor ACE2 – implications for microvascular inflammation and hypercoagulopathy in COVID-19. *bioRxiv*, 2020.2005.2011.088500.
- Helms, J., Kremer, S., Merdji, H., Clere-Jehl, R., Schenck, M., Kummerlen, C., Collange, O., Boulay, C., Fafi-Kremer, S., Ohana, M., Anheim, M., & Meziani, F. (2020). Neurologic features in severe SARS-CoV-2 infection. *The New England Journal of Medicine*, 382, 2268–2270. <https://doi.org/10.1056/NEJMc2008597>
- Heming, M., Li, X., Rauber, S., Mausberg, A. K., Borsch, A. L., Hartlehnert, M., Singhal, A., Lu, I. N., Fleischer, M., Szeponowski, F., Witzke, O., Brenner, T., Dittmer, U., Yosef, N., Kleinschnitz, C., Wiendl, H., Stettner, M., & Horste, M. Z. (2021). Neurological manifestations of COVID-19 feature T cell exhaustion and dedifferentiated monocytes in cerebrospinal fluid. *Immunity*, 54(164–175), e166.
- Huber, C., Batchelor, J. R., Fuchs, D., Hausen, A., Lang, A., Niederwieser, D., Reibnegger, G., Swetly, P., Troppmair, J., & Wachter, H. (1984). Immune response-associated production of neopterin. Release from macrophages primarily under control of interferon-gamma. *The Journal of Experimental Medicine*, 160, 310–316. <https://doi.org/10.1084/jem.160.1.310>
- Iqbal, F. M., Lam, K., Sounderajah, V., Clarke, J. M., Ashrafian, H., & Darzi, A. (2021). Characteristics and predictors of acute and chronic post-COVID syndrome: A systematic review and meta-analysis. *EClinicalMedicine*, 36, 100899. <https://doi.org/10.1016/j.eclinm.2021.100899>
- Jensen, M. P., Le Quesne, J., Officer-Jones, L., Teodòsio, A., Thaventhiran, J., Ficken, C., Goddard, M., Smith, C., Menon, D., & Allinson, K. S. J. (2020). Neuropathological findings in two patients with fatal COVID-19. *Neuropathology and Applied Neurobiology*, 47(1), 17–25. <https://doi.org/10.1111/nan.12662>
- Jessen Krut, J., Mellberg, T., Price, R. W., Hagberg, L., Fuchs, D., Rosengren, L., Nilsson, S., Zetterberg, H., & Gisslen, M. (2014). Biomarker evidence of axonal injury in neuroasymptomatic HIV-1 patients. *PLoS One*, 9, e88591.
- Johansen, J. S., Stoltenberg, M., Hansen, M., Florescu, A., Horslev-Petersen, K., Lorenzen, I., & Price, P. A. (1999). Serum YKL-40 concentrations in patients with rheumatoid arthritis: Relation to disease activity. *Rheumatology (Oxford)*, 38, 618–626. <https://doi.org/10.1093/rheumatology/38.7.618>
- Kanberg, N., Ashton, N. J., Andersson, L.-M., Yilmaz, A., Lindh, M., Nilsson, S., Price, R. W., Blennow, K., Zetterberg, H., & Gisslén, M. (2020). Neurochemical evidence of astrocytic and neuronal injury commonly found in COVID-19. *Neurology*, 95(12), e1754–e1759. <https://doi.org/10.1212/WNL.0000000000010111>
- Kandemirli, S. G., Dogan, L., Sarikaya, Z. T., Kara, S., Akinci, C., Kaya, D., Kaya, Y., Yildirim, D., Tuzuner, F., Yildirim, M. S., Ozluk, E., Gucyetmez, B., Karaarslan, E., Koyluoglu, I., Demirel Kaya, H. S., Mammadov, O., Kisa Ozdemir, I., Afsar, N., Citci Yalcinkaya, B., ... Kocer, N. (2020). Brain MRI findings in patients in the intensive care unit with COVID-19 infection. *Radiology*, 297, E232–E235. <https://doi.org/10.1148/radiol.2020201697>
- Katsanos, A. H., Makris, K., Stefani, D., Koniari, K., Gialouri, E., Lelekis, M., Chondrogianni, M., Zompola, C., Dardiotis, E., Rizos, I., Parisis, J., Boutati, E., Voumvourakis, K., & Tsvigoulis, G. (2017). Plasma glial fibrillary acidic protein in the differential diagnosis of intracerebral hemorrhage. *Stroke*, 48, 2586–2588. <https://doi.org/10.1161/STROKEAHA.117.018409>
- Keller, E., Brandi, G., Winklhofer, S., Imbach, L. L., Kirschenbaum, D., Frontzek, K., Steiger, P., Dietler, S., Haeblerlin, M., Willsms, J., Porta, F., Waeckerlin, A., Huber, M., Abela, I. A., Lutterotti, A., Stippich, C., Globas, C., Varga, Z., & Jelcic, I. (2020). Large and small cerebral vessel involvement in severe COVID-19: Detailed clinical workup of a case series. *Stroke*, 51, 3719–3722. <https://doi.org/10.1161/STROKEAHA.120.031224>
- Korinthenberg, R. (2013). Acute polyradiculoneuritis: Guillain-barre syndrome. *Handbook of Clinical Neurology*, 112, 1157–1162.
- Kothur, K., Wienholt, L., Brilot, F., & Dale, R. C. (2016). CSF cytokines/chemokines as biomarkers in neuroinflammatory CNS disorders: A systematic review. *Cytokine*, 77, 227–237.
- Koutroubakis, I. E., Petinaki, E., Dimoulios, P., Vardas, E., Roussomoustakaki, M., Maniatis, A. N., & Kouroumalis, E. A. (2003). Increased serum levels of YKL-40 in patients with inflammatory bowel disease. *International Journal of Colorectal Disease*, 18, 254–259.
- Kremer, S., Lersy, F., Anheim, M., Merdji, H., Schenck, M., Oesterlé, H., Bolognini, F., Messie, J., Khalil, A., Gaudemer, A., Carré, S., Alleg, M., Lecocq, C., Schmitt, E., Anxionnat, R., Zhu, F., Jager, L., Nesser, P., Mba, Y. T., ... Cotton, F. (2020). Neurologic and neuroimaging findings in patients with COVID-19: A retrospective multicenter study. *Neurology*, 95, e1868–e1882.
- Kuhle, J., Barro, C., Andreasson, U., Derfuss, T., Lindberg, R., Sandelius, A., Liman, V., Norgren, N., Blennow, K., & Zetterberg, H. (2016). Comparison of three analytical platforms for quantification of the neurofilament light chain in blood samples: ELISA, electrochemoluminescence immunoassay and Simoa. *Clinical Chemistry and Laboratory Medicine*, 54, 1655–1661.
- Kuhle, J., Kropshofer, H., Haering, D. A., Kundu, U., Meinert, R., Barro, C., Dahlke, F., Tomic, D., Leppert, D., & Kappos, L. (2019). Blood neurofilament light chain as a biomarker of MS disease activity and treatment response. *Neurology*, 92, e1007–e1015.
- Lakeman, F. D., & Whitley, R. J. (1995). Diagnosis of herpes simplex encephalitis: Application of polymerase chain reaction to cerebrospinal fluid from brain-biopsied patients and correlation with disease. National Institute of Allergy and Infectious Diseases Collaborative Antiviral Study Group. *The Journal of Infectious Diseases*, 171, 857–863.
- Lallana, S., Chen, A., Requena, M., Rubiera, M., Sanchez, A., Siegler, J. E., & Muchada, M. (2021). Posterior reversible encephalopathy syndrome (PRES) associated with COVID-19. *Journal of Clinical Neuroscience*, 88, 108–112.
- Laverse, E., Guo, T., Zimmerman, K., Foiani, M. S., Velani, B., Morrow, P., Adejuwon, A., Bamford, R., Underwood, N., George, J., Brooke, D., O'Brien, K., Cross, M. J., Kemp, S. P. T., Heslegrave, A. J., Hardy, J., Sharp, D. J., Zetterberg, H., & Morris, H. R. (2020). Plasma glial fibrillary acidic protein and neurofilament light chain, but not tau, are biomarkers of sports-related mild traumatic brain injury. *Brain Communications*, 2, fcaa137.
- Lechien, J. R., Chiesa-Estomba, C. M., De Siati, D. R., Horoi, M., Le Bon, S. D., Rodriguez, A., Dequanter, D., Blecic, S., El Afia, F., Distinguin, L., Chekkoury-Idrissi, Y., Hans, S., Delgado, I. L., Calvo-Henriquez, C., Lavigne, P., Falanga, C., Barillari, M. R., Cammaroto, G., Khalife, M., ... Saussez, S. (2020). Olfactory and gustatory dysfunctions as a clinical presentation of mild-to-moderate forms of the coronavirus disease (COVID-19): a multicenter European study. *European Archives of Oto-Rhino-Laryngology*, 277, 2251–2261.
- Lee, D. W., Santomaso, B. D., Locke, F. L., Ghabadi, A., Turtle, C. J., Brudno, J. N., Maus, M. V., Park, J. H., Mead, E., Pavletic, S., Go, W. Y., Eldjerou, L., Gardner, R. A., Frey, N., Curran, K. J., Peggs, K., Pasquini, M., DiPersio, J. F., van den Brink, M. R. M., ... Neelapu, S. S. (2019). ASTCT consensus grading for cytokine release syndrome and neurologic toxicity associated with immune effector cells.



- Biology of Blood and Marrow Transplantation*, 25, 625–638. <https://doi.org/10.1016/j.bbmt.2018.12.758>
- Lee, M.-H., Perl, D. P., Nair, G., Li, W., Maric, D., Murray, H., Dodd, S. J., Koretsky, A. P., Watts, J. A., Cheung, V., Masliyah, E., Horkayne-Szakaly, I., Jones, R., Stram, M. N., Moncur, J., Hefti, M., Folkner, R. D., & Nath, A. (2020). Microvascular injury in the brains of patients with Covid-19. *The New England Journal of Medicine*, 384(5), 481–483. <https://doi.org/10.1056/NEJMc2033369>
- Leist, S. R., Dinnon, K. H. 3rd, Schafer, A., Tse, L. V., Okuda, K., Hou, Y. J., West, A., Edwards, C. E., Sanders, W., Fritch, E. J., Gully, K. L., Scobey, T., Brown, A. J., Sheahan, T. P., Moorman, N. J., Boucher, R. C., Gralinski, L. E., Montgomery, S. A., & Baric, R. S. (2020). A mouse-adapted SARS-CoV-2 induces acute lung injury and mortality in standard laboratory mice. *Cell*, 183(1070–1085), e1012.
- Lersy, F., Benotmane, I., Helms, J., Collange, O., Schenck, M., Brisset, J.-C., Chammas, A., Willaume, T., Lefebvre, N., Solis, M., Hansmann, Y., Fabacher, T., Caillard, S., Mertes, P. M., Pottecher, J., Schneider, F., Meziani, F., Fafi-Kremer, S., & Kremer, S. (2021). Cerebrospinal fluid features in patients with coronavirus disease 2019 and neurological manifestations: correlation with brain magnetic resonance imaging findings in 58 patients. *The Journal of Infectious Diseases*, 223, 600–609.
- Lindahl, P., Johansson, B. R., Leveen, P., & Betsholtz, C. (1997). Pericyte loss and microaneurysm formation in PDGF-B-deficient mice. *Science*, 277, 242–245. <https://doi.org/10.1126/science.277.5323.242>
- Liotta, E. M., Batra, A., Clark, J. R., Shlobin, N. A., Hoffman, S. C., Orban, Z. S., & Koralnik, I. J. (2020). Frequent neurologic manifestations and encephalopathy-associated morbidity in Covid-19 patients. *Annals of Clinical and Translational Neurology*, 7, 2221–2230.
- Lu, Y., Li, X., Geng, D., Mei, N., Wu, P.-Y., Huang, C.-C., Jia, T., Zhao, Y., Wang, D., Xiao, A., & Yin, B. O. (2020). Cerebral micro-structural changes in COVID-19 patients - an MRI-based 3-month follow-up study. *EClinicalMedicine*, 25, 100484. <https://doi.org/10.1016/j.eclinm.2020.100484>
- Malmstrom, C., Axelsson, M., Lycke, J., Zetterberg, H., Blennow, K., & Olsson, B. (2014). CSF levels of YKL-40 are increased in MS and replaces with immunosuppressive treatment. *Journal of Neuroimmunology*, 269, 87–89.
- Mao, L., Jin, H., Wang, M., Hu, Y. U., Chen, S., He, Q., Chang, J., Hong, C., Zhou, Y., Wang, D., Miao, X., Li, Y., & Hu, B. O. (2020). Neurologic manifestations of hospitalized patients with coronavirus disease 2019 in Wuhan, China. *JAMA Neurology*, 77(6), 683. <https://doi.org/10.1001/jamaneurol.2020.1127>
- Martin-Aguilar, L., Camps-Renom, P., Lleixa, C., Pascual-Goni, E., Diaz-Manera, J., Rojas-Garcia, R., De Luna, N., Gallardo, E., Cortes-Vicente, E., Munoz, L., Alcolea, D., Lleo, A., Casasnovas, C., Hamedes, C., Gutierrez-Gutierrez, G., Jimeno-Montero, M. C., Berciano, J., Sedano-Tous, M. J., Garcia-Sobrinho, T., & Querol, L. (2020). Serum neurofilament light chain predicts long-term prognosis in Guillain-Barre syndrome patients. *Journal of Neurology, Neurosurgery and Psychiatry*. [jnnp-2020-323899](https://doi.org/10.1136/jnnp-2020-323899). <https://doi.org/10.1136/jnnp-2020-323899>
- Matschke, J., Lütgehetmann, M., Hagel, C., Spherhake, J. P., Schröder, A. S., Edler, C., Mushumba, H., Fitzek, A., Allweiss, L., Dandri, M., Dottermusch, M., Heinemann, A., Pfefferle, S., Schwabenland, M., Sumner Magruder, D., Bonn, S., Prinz, M., Gerloff, C., Püschel, K., ... Glatzel, M. (2020). Neuropathology of patients with COVID-19 in Germany: A post-mortem case series. *The Lancet Neurology*, 19, 919–929. [https://doi.org/10.1016/S1474-4422\(20\)30308-2](https://doi.org/10.1016/S1474-4422(20)30308-2)
- Mazza, M. G., Palladini, M., Lorenzo, R. D., Magnaghi, C., Poletti, S., Furlan, R., Ciceri, F., COVID-19 BioB Outpatient Clinic Study group; Rovere-Querini, P., & Benedetti, F. (2021). Persistent psychopathology and neurocognitive impairment in COVID-19 survivors: Effect of inflammatory biomarkers at three-month follow-up. *Brain, Behavior, and Immunity*, 94, 138–147.
- McCracken, I. R., Saginc, G., He, L., Huseynov, A., Daniels, A., Fletcher, S., Peghaire, C., Kalna, V., Andaloussi-Mäe, M., Muhl, L., Craig, N. M., Griffiths, S. J., Haas, J. G., Tait-Burkard, C., Lendahl, U., Birdsey, G. M., Betsholtz, C., Nosedá, M., Baker, A. H., & Randi, A. M. (2021). Lack of evidence of angiotensin-converting enzyme 2 expression and replicative infection by SARS-CoV-2 in human endothelial cells. *Circulation*, 143, 865–868. <https://doi.org/10.1161/CIRCULATIONAHA.120.052824>
- McMahon, P. J., Panczykowski, D. M., Yue, J. K., Puccio, A. M., Inoue, T., Sorani, M. D., Lingsma, H. F., Maas, A. I. R., Valadka, A. B., Yuh, E. L., Mukherjee, P., Manley, G. T., Okonkwo, D. O., Casey, S. S., Cheong, M., Cooper, S. R., Dams-O'Connor, K., Gordon, W. A., Hricik, A. J., ... Vassar, M. J. (2015). Measurement of the glial fibrillary acidic protein and its breakdown products GFAP-BDP biomarker for the detection of traumatic brain injury compared to computed tomography and magnetic resonance imaging. *Journal of Neurotrauma*, 32, 527–533.
- Meinhardt, J., Radke, J., Dittmayer, C., Franz, J., Thomas, C., Mothes, R., Laue, M., Schneider, J., Brünink, S., Greuel, S., Lehmann, M., Hassan, O., Aschman, T., Schumann, E., Chua, R. L., Conrad, C., Eils, R., Stenzel, W., Windgassen, M., ... Heppner, F. L. (2021). Olfactory transmucosal SARS-CoV-2 invasion as a port of central nervous system entry in individuals with COVID-19. *Nature Neuroscience*, 24, 168–175.
- Meppiel, E., Peiffer-Smadja, N., Maury, A., Bekri, I., Delorme, C., Desestret, V., Gorza, L., Hauteclouque-Raysz, G., Landre, S., Lannuzel, A., Moulin, S., Perrin, P., Petitgas, P., Sellal, F., Wang, A., Tattevin, P., & de Broucker, T. (2021). Neurological manifestations associated with COVID-19: A multicentric registry. *Clinical Microbiology & Infection*, 27, 458–466.
- Miller, E. H., Namale, V. S., Kim, C., Dugue, R., Waldrop, G., Ciryam, P., Chong, A. M., Zucker, J., Miller, E. C., Bain, J. M., Willey, J. Z., Doyle, K., Boehme, A., Claassen, J., Uhlemann, A.-C., & Thakur, K. T. (2020). Cerebrospinal analysis in patients with COVID-19. *Open Forum Infectious Diseases*, 7, ofaa501.
- Miners, J. S., Kehoe, P. G., Love, S., Zetterberg, H., & Blennow, K. (2019). CSF evidence of pericyte damage in Alzheimer's disease is associated with markers of blood-brain barrier dysfunction and disease pathology. *Alzheimer's Research & Therapy*, 11, 81. <https://doi.org/10.1186/s13195-019-0534-8>
- Molero-Luis, M., Casas-Alba, D., Orellana, G., Ormazabal, A., Sierra, C., Oliva, C., Valls, A., Velasco, J., Launes, C., Cuadras, D., Pérez-Dueñas, B., Jordan, I., Cambra, F. J., Ortigoza-Escobar, J. D., Muñoz-Almagro, C., Garcia-Cazorla, A., Armangué, T., & Artuch, R. (2020). Cerebrospinal fluid neopterin as a biomarker of neuroinflammatory diseases. *Scientific Reports*, 10, 18291.
- Moriguchi, T., Harii, N., Goto, J., Harada, D., Sugawara, H., Takamino, J., Ueno, M., Sakata, H., Kondo, K., Myose, N., Nakao, A., Takeda, M., Haro, H., Inoue, O., Suzuki-Inoue, K., Kubokawa, K., Ogihara, S., Sasaki, T., Kinouchi, H., ... Shimada, S. (2020). A first case of meningitis/encephalitis associated with SARS-Coronavirus-2. *International Journal of Infectious Diseases*, 94, 55–58. <https://doi.org/10.1016/j.ijid.2020.03.062>
- Murr, C., Widner, B., Wirleitner, B., & Fuchs, D. (2002). Neopterin as a marker for immune system activation. *Current Drug Metabolism*, 3, 175–187.
- Nation, D. A., Sweeney, M. D., Montagne, A., Sagare, A. P., D'Orazio, L. M., Pachicano, M., Seppehrband, F., Nelson, A. R., Buennagel, D. P., Harrington, M. G., Benzinger, T. L. S., Fagan, A. M., Ringman, J. M., Schneider, L. S., Morris, J. C., Chui, H. C., Law, M., Toga, A. W., & Zlokovic, B. V. (2019). Blood-brain barrier breakdown is an early biomarker of human cognitive dysfunction. *Nature Medicine*, 25, 270–276. <https://doi.org/10.1038/s41591-018-0297-y>
- Neselius, S., Brisby, H., Theodorsson, A., Blennow, K., Zetterberg, H., & Marcusson, J. (2012). CSF-biomarkers in Olympic boxing: diagnosis and effects of repetitive head trauma. *PLoS One*, 7, e33606.



- Neumann, B., Schmidbauer, M. L., Dimitriadis, K., Otto, S., Knier, B., Niesen, W.-D., Hosp, J. A., Günther, A., Lindemann, S., Nagy, G., Steinberg, T., Linker, R. A., Hemmer, B., & Bösel, J. (2020). Cerebrospinal fluid findings in COVID-19 patients with neurological symptoms. *Journal of the Neurological Sciences*, 418, 117090. <https://doi.org/10.1016/j.jns.2020.117090>
- Ohrfelt, A., Axelsson, M., Malmstrom, C., Novakova, L., Heslegrave, A., Blennow, K., Lycke, J., & Zetterberg, H. (2016). Soluble TREM-2 in cerebrospinal fluid from patients with multiple sclerosis treated with natalizumab or mitoxantrone. *Multiple Sclerosis Journal*, 22, 1587–1595. <https://doi.org/10.1177/1352458515624558>
- Olsson, B., Alberg, L., Cullen, N. C., Michael, E., Wahlgren, L., Krokmark, A. K., Rostasy, K., Blennow, K., Zetterberg, H., & Tulinius, M. (2019). NFL is a marker of treatment response in children with SMA treated with nusinersen. *Journal of Neurology*, 266, 2129–2136.
- Olsson, B., Zetterberg, H., Hampel, H., & Blennow, K. (2011). Biomarker-based dissection of neurodegenerative diseases. *Progress in Neurobiology*, 95, 520–534.
- Oxley, T. J., Mocco, J., Majidi, S., Kellner, C. P., Shoirah, H., Singh, I. P., De Leacy, R. A., Shigematsu, T., Ladner, T. R., Yaeger, K. A., Skliut, M., Weinberger, J., Dangayach, N. S., Bederson, J. B., Tuhim, S., & Fifi, J. T. (2020). Large-vessel stroke as a presenting feature of covid-19 in the young. *The New England Journal of Medicine*, 382, e60. <https://doi.org/10.1056/NEJMc2009787>
- Ozger, H. S., Dizbay, M., Corbacioglu, S. K., Aysert, P., Demirbas, Z., Tunccan, O. G., Hizel, K., Bozdayi, G., & Caglar, K. (2020). The prognostic role of neopterin in COVID-19 patients. *Journal of Medical Virology*, 93(3), 1520–1525. <https://doi.org/10.1002/jmv.26472>
- Paniz-Mondolfi, A., Bryce, C., Grimes, Z., Gordon, R. E., Reidy, J., Lednický, J., Sordillo, E. M., & Fowkes, M. (2020). Central nervous system involvement by severe acute respiratory syndrome coronavirus-2 (SARS-CoV-2). *Journal of Medical Virology*, 92, 699–702. <https://doi.org/10.1002/jmv.25915>
- Paterson, R. W., Brown, R. L., Benjamin, L., Nortley, R., Wiethoff, S., Bharucha, T., Jayaseelan, D. L., Kumar, G., Raftopoulos, R. E., Zambreau, L., Vivekanandam, V., Khoo, A., Gerald, R., Chinthapalli, K., Boyd, E., Tuzlali, H., Price, G., Christofi, G., Morrow, J., ... Zandi, M. S. (2020). The emerging spectrum of COVID-19 neurology: Clinical, radiological and laboratory findings. *Brain*, 143, 3104–3120.
- Perrin, P., Collongues, N., Baloglu, S., Bedo, D., Bassand, X., Lavaux, T., Gautier-Vargas, G., Keller, N., Kremer, S., Fafi-Kremer, S., Moulin, B., Benotmane, I., & Caillard, S. (2021). Cytokine release syndrome-associated encephalopathy in patients with COVID-19. *European Journal of Neurology*, 28, 248–258. <https://doi.org/10.1111/ene.14491>
- Pilotto, A., Benussi, A., Libri, I., Masciocchi, S., Poli, L., Premi, E., Alberici, A., Baldelli, E., Bonacina, S., Brambilla, L., Benini, M., Caratozzolo, S., Cortinovis, M., Costa, A., Cotti Piccinelli, S., Cottini, E., Cristillo, V., Delrio, I., Filosto, M., ... Padovani, A. (2020). COVID-19 impact on consecutive neurological patients admitted to the emergency department. *Journal of Neurology Neurosurgery and Psychiatry*.
- Pilotto, A., Masciocchi, S., Volonghi, I., Crabbio, M., Magni, E., De Giuli, V., Caprioli, F., Rifino, N., Sessa, M., Gennuso, M., Cotelli, M. S., Turla, M., Balducci, U., Mariotto, S., Ferrari, S., Ciccone, A., Fiacco, F., Imarisio, A., Risi, B., ... Padovani, A. (2021). Clinical presentation and outcomes of severe acute respiratory syndrome coronavirus 2-related encephalitis: The ENCOVID multicenter study. *The Journal of Infectious Diseases*, 223, 28–37.
- Pilotto, A., Masciocchi, S., Volonghi, I., De Giuli, V., Caprioli, F., Mariotto, S., Ferrari, S., Bozzetti, S., Imarisio, A., Risi, B., Premi, E., Benussi, A., Focà, E., Castelli, F., Zanusso, G., Monaco, S., Stefanelli, P., Gasparotti, R., Zekeridou, A., ... Padovani, A. (2021). SARS-CoV-2 encephalitis is a cytokine release syndrome: Evidences from cerebrospinal fluid analyses. *Clinical Infectious Diseases*. <https://doi.org/10.1093/cid/ciaa1933>
- Pilotto, A., Odolini, S., Masciocchi, S., Comelli, A., Volonghi, I., Gazzina, S., Nocivelli, S., Pezzini, A., Focà, E., Caruso, A., Leonardi, M., Pasolini, M. P., Gasparotti, R., Castelli, F., Ashton, N. J., Blennow, K., Zetterberg, H., & Padovani, A. (2020). Steroid-responsive encephalitis in coronavirus disease 2019. *Annals of Neurology*, 88(2), 423–427. <https://doi.org/10.1002/ana.25783>
- Pohl, D., Alper, G., Van Haren, K., Kornberg, A. J., Lucchinetti, C. F., Tenembaum, S., & Belman, A. L. (2016). Acute disseminated encephalomyelitis: Updates on an inflammatory CNS syndrome. *Neurology*, 87, S38–45. <https://doi.org/10.1212/WNL.0000000000002825>
- Poillon, G., Obadia, M., Perrin, M., Savatovsky, J., & Lecler, A. (2020). Cerebral venous thrombosis associated with COVID-19 infection: Causality or coincidence? *Journal of Neuroradiology*. *Journal De Neuroradiologie*, 48(2), 121–124. <https://doi.org/10.1016/j.neurad.2020.05.003>
- Poyiadji, N., Shahin, G., Noujaim, D., Stone, M., Patel, S., & Griffith, B. (2020). COVID-19-associated acute hemorrhagic necrotizing encephalopathy: CT and MRI features. *Radiology*, 296, E119–E120.
- Presslauer, S., Milosavljevic, D., Brucke, T., Bayer, P., & Hubl, W. (2008). Elevated levels of kappa free light chains in CSF support the diagnosis of multiple sclerosis. *Journal of Neurology*, 255, 1508–1514. <https://doi.org/10.1007/s00415-008-0954-z>
- Price, R. W., Peterson, J., Fuchs, D., Angel, T. E., Zetterberg, H., Hagberg, L., Spudich, S., Smith, R. D., Jacobs, J. M., Brown, J. N., & Gisslen, M. (2013). Approach to cerebrospinal fluid (CSF) biomarker discovery and evaluation in HIV infection. *Journal of Neuroimmune Pharmacology: The Official Journal of the Society on NeuroImmune Pharmacology*, 8, 1147–1158. <https://doi.org/10.1007/s11481-013-9491-3>
- Rehli, M., Niller, H. H., Ammon, C., Langmann, S., Schwarzfischer, L., Andreesen, R., & Krause, S. W. (2003). Transcriptional regulation of CHI3L1, a marker gene for late stages of macrophage differentiation. *Journal of Biological Chemistry*, 278, 44058–44067. <https://doi.org/10.1074/jbc.M306792200>
- Reiber, H., & Peter, J. B. (2001). Cerebrospinal fluid analysis: Disease-related data patterns and evaluation programs. *Journal of the Neurological Sciences*, 184, 101–122. [https://doi.org/10.1016/S0022-510X\(00\)00501-3](https://doi.org/10.1016/S0022-510X(00)00501-3)
- Remmelink, M., De Mendonça, R., D'Haene, N., De Clercq, S., Verocq, C., Lebrun, L., Lavis, P., Racu, M.-L., Trépant, A.-L., Maris, C., Rorive, S., Goffard, J.-C., De Witte, O., Peluso, L., Vincent, J.-L., Decaestecker, C., Taccone, F. S., & Salmon, I. (2020). Unspecific post-mortem findings despite multiorgan viral spread in COVID-19 patients. *Critical Care*, 24, 495. <https://doi.org/10.1186/s13054-020-03218-5>
- Remsik, J., Wilcox, J. A., Babady, N. E., McMillen, T., Vachha, B. A., Halpern, N. A., Dhawan, V., Rosenblum, M., Iacobuzio-Donahue, C. A., Avila, E. K., Santomaso, B., & Boire, A. (2020). Inflammatory leptomeningeal cytokines mediate delayed COVID-19 encephalopathy. *medRxiv*.
- Robertson, J., Gostner, J. M., Nilsson, S., Andersson, L. M., Fuchs, D., & Gisslen, M. (2020). Serum neopterin levels in relation to mild and severe COVID-19. *BMC Infectious Diseases*, 20, 942. <https://doi.org/10.1186/s12879-020-05671-7>
- Romero-Sánchez, C. M., Díaz-Maroto, I., Fernández-Díaz, E., Sánchez-Larsen, Á., Layos-Romero, A., García-García, J., González, E., Redondo-Peñas, I., Perona-Moratalla, A. B., Del Valle-Pérez, J. A., Gracia-Gil, J., Rojas-Bartolomé, L., Feria-Vilar, I., Monteagudo, M., Palao, M., Palazón-García, E., Alcahut-Rodríguez, C., Sopelana-Garay, D., Moreno, Y., ... Segura, T. (2020). Neurologic manifestations in hospitalized patients with COVID-19: The ALBACOV registry. *Neurology*, 95, e1060–e1070. <https://doi.org/10.1212/WNL.0000000000009937>
- Sagare, A. P., Sweeney, M. D., Makshano, J., & Zlokovic, B. V. (2015). Shedding of soluble platelet-derived growth factor receptor-beta from human brain pericytes. *Neuroscience Letters*, 607, 97–101.
- Saitta, L., Molin, A., Villani, F., Insoresi, A., Roccatagliata, L., Inglese, M., Bassetti, M., Pelosi, P., Castellan, L., Gerevini, S., Robba, C.,

- & Patroniti, N. (2020). Brain microvascular occlusive disorder in COVID-19: A case report. *Neurological Sciences*, 41(12), 3401–3404. <https://doi.org/10.1007/s10072-020-04795-7>
- Santomasso, B. D., Park, J. H., Salloum, D., Riviere, I., Flynn, J., Mead, E., Halton, E., Wang, X., Senechal, B., Purdon, T., Cross, J. R., Liu, H., Vachha, B., Chen, X. I., DeAngelis, L. M., Li, D., Bernal, Y., Gonen, M., Wendel, H.-G., ... Brentjens, R. J. (2018). Clinical and biological correlates of neurotoxicity associated with CAR T-cell therapy in patients with B-cell acute lymphoblastic leukemia. *Cancer Discovery*, 8, 958–971. <https://doi.org/10.1158/2159-8290.CD-17-1319>
- Schurink, B., Roos, E., Radonic, T., Barbe, E., Bouman, C. S. C., de Boer, H. H., de Bree, G. J., Bulle, E. B., Aronica, E. M., Florquin, S., Fronczek, J., Heunks, L. M. A., de Jong, M. D., Guo, L., du Long, R., Lutter, R., Molenaar, P. C. G., Neefjes-Borst, E. A., Niessen, H. W. M., ... Bugiani, M. (2020). Viral presence and immunopathology in patients with lethal COVID-19: A prospective autopsy cohort study. *Lancet Microbe*, 1, e290–e299.
- Schwarz, R., Bruno, J. P., Muchowski, P. J., & Wu, H. Q. (2012). Kynurenines in the mammalian brain: When physiology meets pathology. *Nature Reviews Neuroscience*, 13, 465–477.
- Shahim, P., Gren, M., Liman, V., Andreasson, U., Norgren, N., Tegner, Y., Mattsson, N., Andreassen, N., Ost, M., Zetterberg, H., Nellgard, B., & Blennow, K. (2016). Serum neurofilament light protein predicts clinical outcome in traumatic brain injury. *Scientific Reports*, 6, 36791.
- Silva, M. T. T., Lima, M. A., Torezani, G., Soares, C. N., Dantas, C., Brandao, C. O., Espindola, O., Siqueira, M. M., & Araujo, A. Q. (2020). Isolated intracranial hypertension associated with COVID-19. *Cephalalgia*, 40, 1452–1458. <https://doi.org/10.1177/0333102420965963>
- Skok, K., Stelzl, E., Trauner, M., Kessler, H. H., & Lax, S. F. (2020). Post-mortem viral dynamics and tropism in COVID-19 patients in correlation with organ damage. *Virchows Archiv*, 478(2), 343–353. <https://doi.org/10.1007/s00428-020-02903-8>
- Solomon, I. H., Normandin, E., Bhattacharyya, S., Mukerji, S. S., Keller, K., Ali, A. S., Adams, G., Hornick, J. L., Padera, R. F., & Sabeti, P. (2020). Neuropathological features of covid-19. *The New England Journal of Medicine*, 383, 989–992. <https://doi.org/10.1056/NEJMc2019373>
- Studahl, M. (2003). Influenza virus and CNS manifestations. *Journal of Clinical Virology*, 28, 225–232. [https://doi.org/10.1016/S1386-6532\(03\)00119-7](https://doi.org/10.1016/S1386-6532(03)00119-7)
- Susse, M., Feistner, F., Holbe, C., Grothe, M., Nauck, M., Dressel, A., & Hannich, M. J. (2020). Diagnostic value of kappa free light chains in patients with one isolated band in isoelectric focusing. *Clinica Chimica Acta*, 507, 205–209. <https://doi.org/10.1016/j.cca.2020.04.029>
- Sutter, R., Hert, L., De Marchis, G. M., Twerenbold, R., Kappos, L., Naegelin, Y., Kuster, G. M., Benkert, P., Jost, J., Maceski, A. M., Rüegg, S., Siegemund, M., Leppert, D., Tschudin-Sutter, S., & Kuhle, J. (2020). Serum neurofilament light chain levels in the intensive care unit: Comparison between severely ill patients with and without coronavirus disease 2019. *Annals of Neurology*, 89(3), 610–616. <https://doi.org/10.1002/ana.26004>
- Tang, N., Li, D., Wang, X., & Sun, Z. (2020). Abnormal coagulation parameters are associated with poor prognosis in patients with novel coronavirus pneumonia. *Journal of Thrombosis and Haemostasis*, 18, 844–847. <https://doi.org/10.1111/jth.14768>
- Toklu, H., Ganti, L., Crimi, E., Cintron, C., Hagan, J., & Serrano, E. (2020). Cerebrospinal fluid findings and hypernatremia in COVID-19 patients with altered mental status. *International Journal of Emergency Medicine*, 13, 63. <https://doi.org/10.1186/s12245-020-00327-4>
- Tom, M. R., & Mina, M. J. (2020). To interpret the SARS-CoV-2 test, consider the cycle threshold value. *Clinical Infectious Diseases*, 71(16), 2252–2254. <https://doi.org/10.1093/cid/ciaa619>
- Toscano, G., Palmerini, F., Ravaglia, S., Ruiz, L., Invernizzi, P., Cuzzoni, M. G., Franciotta, D., Baldanti, F., Daturi, R., Postorino, P., Cavallini, A., & Miceli, G. (2020). Guillain-Barre syndrome associated with SARS-CoV-2. *The New England Journal of Medicine*, 382, 2574–2576.
- Tumani, H., Nolker, G., & Reiber, H. (1995). Relevance of cerebrospinal fluid variables for early diagnosis of neuroborreliosis. *Neurology*, 45, 1663–1670. <https://doi.org/10.1212/WNL.45.9.1663>
- Ulland, T. K., & Colonna, M. (2018). TREM2 - a key player in microglial biology and Alzheimer disease. *Nature Reviews. Neurology*, 14, 667–675. <https://doi.org/10.1038/s41582-018-0072-1>
- Vabret, N., Britton, G. J., Gruber, C., Hegde, S., Kim, J., Kuksin, M., Levantovsky, R., Malle, L., Moreira, A., Park, M. D., Pia, L., Risson, E., Saffern, M., Salomé, B., Esai Selvan, M., Spindler, M. P., Tan, J., van der Heide, V., Gregory, J. K., ... Laserson, U. (2020). Immunology of COVID-19: Current state of the science. *Immunity*, 52, 910–941. <https://doi.org/10.1016/j.immuni.2020.05.002>
- Varatharaj, A., Thomas, N., Ellul, M. A., Davies, N. W. S., Pollak, T. A., Tenorio, E. L., Sultan, M., Easton, A., Breen, G., Zandi, M., Coles, J. P., Manji, H., Al-Shahi Salman, R., Menon, D. K., Nicholson, T. R., Benjamin, L. A., Carson, A., Smith, C., Turner, M. R., ... Plant, G. (2020). Neurological and neuropsychiatric complications of COVID-19 in 153 patients: A UK-wide surveillance study. *Lancet Psychiatry*, 7, 875–882. [https://doi.org/10.1016/S2215-0366\(20\)30287-X](https://doi.org/10.1016/S2215-0366(20)30287-X)
- Varga, Z., Flammer, A. J., Steiger, P., Haberecker, M., Andermatt, R., Zinkernagel, A. S., Mehra, M. R., Schuepbach, R. A., Ruschitzka, F., & Moch, H. (2020). Endothelial cell infection and endotheliitis in COVID-19. *Lancet*, 395, 1417–1418. [https://doi.org/10.1016/S0140-6736\(20\)30937-5](https://doi.org/10.1016/S0140-6736(20)30937-5)
- Veje, M., Studahl, M., Johansson, M., Johansson, P., Nolskog, P., & Bergstrom, T. (2018). Diagnosing tick-borne encephalitis: A re-evaluation of notified cases. *European Journal of Clinical Microbiology and Infectious Diseases*, 37, 339–344. <https://doi.org/10.1007/s10096-017-3139-9>
- Virhammar, J., Kumlien, E., Fällmar, D., Frithiof, R., Jackmann, S., Sköld, M. K., Kadir, M., Frick, J., Lindeberg, J., Olivero-Reinius, H., Ryttefors, M., Cunningham, J. L., Wikström, J., Grabowska, A., Bondeson, K., Bergquist, J., Zetterberg, H., & Rostami, E. (2020). Acute necrotizing encephalopathy with SARS-CoV-2 RNA confirmed in cerebrospinal fluid. *Neurology*, 95, 445–449. <https://doi.org/10.1212/WNL.0000000000010250>
- Virhammar, J., Naas, A., Fallmar, D., Cunningham, J. L., Klang, A., Ashton, N. J., Jackmann, S., Westman, G., Frithiof, R., Blennow, K., Zetterberg, H., Kumlien, E., & Rostami, E. (2020). Biomarkers for CNS injury in CSF are elevated in COVID-19 and associated with neurological symptoms and disease severity. *European Journal of Neurology*. <https://doi.org/10.1111/ene.14703>
- Wakerley, B. R., & Yuki, N. (2013). Infectious and noninfectious triggers in Guillain-Barre syndrome. *Expert Review of Clinical Immunology*, 9, 627–639.
- Wang, M., Li, T., Qiao, F., Wang, L., Li, C., & Gong, Y. (2020). Coronavirus disease 2019 associated with aggressive neurological and mental abnormalities confirmed based on cerebrospinal fluid antibodies: A case report. *Medicine (Baltimore)*, 99, e21428. <https://doi.org/10.1097/MD.00000000000021428>
- Wijdicks, E. F., & Klein, C. J. (2017). Guillain-Barre syndrome. *Mayo Clinic Proceedings*, 92, 467–479.
- Williamson, E. M. L., & Berger, J. R. (2017). Diagnosis and treatment of progressive multifocal leukoencephalopathy associated with multiple sclerosis therapies. *Neurotherapeutics: The Journal of the American Society for Experimental Neurotherapeutics*, 14, 961–973. <https://doi.org/10.1007/s13311-017-0570-7>
- Willison, H. J., Jacobs, B. C., & van Doorn, P. A. (2016). Guillain-Barre syndrome. *Lancet*, 388, 717–727.
- Wu, F., Zhao, S., Yu, B., Chen, Y. M., Wang, W., Song, Z. G., Hu, Y., Tao, Z. W., Tian, J. H., Pei, Y. Y., Yuan, M. L., Zhang, Y. L., Dai, F. H., Liu, Y., Wang, Q. M., Zheng, J. J., Xu, L., Holmes, E. C., & Zhang, Y. Z. (2020). A new coronavirus associated with human respiratory disease in China. *Nature*, 579, 265–269.
- Yaghi, S., Ishida, K., Torres, J., Mac Grory, B., Raz, E., Humbert, K., Henninger, N., Trivedi, T., Lillemo, K., Alam, S., Sanger, M., Kim,



- S., Scher, E., Dehkharghani, S., Wachs, M., Tanweer, O., Volpicelli, F., Bosworth, B., Lord, A., & Frontera, J. (2020). SARS-CoV-2 and stroke in a New York healthcare system. *Stroke*, 51, 2002–2011.
- Yilmaz, A., Blennow, K., Hagberg, L., Nilsson, S., Price, R. W., Schouten, J., Spudich, S., Underwood, J., Zetterberg, H., & Gisslén, M. (2017). Neurofilament light chain protein as a marker of neuronal injury: Review of its use in HIV-1 infection and reference values for HIV-negative controls. *Expert Review of Molecular Diagnostics*, 17(8), 761–770. <https://doi.org/10.1080/14737159.2017.1341313>
- Yilmaz, A., Mellgren, A., Fuchs, D., Nilsson, S., Blennow, K., Zetterberg, H., & Gisslén, M. (2019). Switching from a regimen containing abacavir/lamivudine or emtricitabine/tenofovir disoproxil fumarate to emtricitabine/tenofovir alafenamide fumarate does not affect central nervous system HIV-1 infection. *Infect Dis (Lond)*, 51, 838–846. <https://doi.org/10.1080/23744235.2019.1670352>
- Zetterberg, H., & Blennow, K. (2016). Fluid biomarkers for mild traumatic brain injury and related conditions. *Nature Reviews. Neurology*, 12, 563–574. <https://doi.org/10.1038/nrneurol.2016.127>
- Zetterberg, H., Hietala, M. A., Jonsson, M., Andreasen, N., Styrud, E., Karlsson, I., Edman, Å., Popa, C., Rasulzada, A., Wahlund, L.-O., Mehta, P. D., Rosengren, L., Blennow, K., & Wallin, A. (2006). Neurochemical aftermath of amateur boxing. *Archives of Neurology*, 63, 1277–1280.
- Zubair, A. S., McAlpine, L. S., Gardin, T., Farhadian, S., Kuruvilla, D. E., & Spudich, S. (2020). Neuropathogenesis and neurologic manifestations of the coronaviruses in the age of coronavirus disease 2019: A review. *JAMA Neurology*, 77, 1018–1027. <https://doi.org/10.1001/jamaneurol.2020.2065>

How to cite this article: Edén, A., Simrén, J., Price, R. W., Zetterberg, H., & Gisslén, M. (2021). Neurochemical biomarkers to study CNS effects of COVID-19: A narrative review and synthesis. *J Neurochem*, 159, 61–77. <https://doi.org/10.1111/jnc.15459>