

Response to mitogen-activated protein kinase inhibition of neurodegeneration in Langerhans cell histiocytosis monitored by cerebrospinal fluid neurofilament light as a biomarker: a pilot study

Langerhans cell histiocytosis (LCH) is an inflammatory myeloid neoplasia with highly variable clinical presentation.¹ Granulomatous lesions of bone, skin, and lungs (particularly in adults) are most common, but the liver, spleen, bone marrow, and central nervous system (CNS) may also be affected.¹ CNS involvement (CNS LCH) often causes endocrinopathies, most commonly diabetes insipidus (DI), but may also cause a debilitating slowly-progressive neurodegeneration.^{1,2} Notably, a population-based study reported that at least 24% of all children with LCH develop signs of neurodegenerative CNS LCH (ND-CNS-LCH) on magnetic resonance imaging (MRI).³ Thus, a strategy for early detection, treatment, and monitoring of ND-CNS-LCH is imperative.

In the current international treatment protocol (LCH-IV), one-year monotherapy with low-dose cytarabine or intravenous immunoglobulin is suggested for patients with clinically manifest ND-CNS-LCH.^{4,5} However, these treatment attempts have only had limited effects. Importantly, LCH has been associated with oncogenic somatic mutations, predominantly in *BRAF* and *MAP2K1*, resulting in constitutive activation of the mitogen-activated protein kinase (MAPK) pathway in LCH lesions.⁶ This has led to successful treatment with targeted MAPK pathway inhibition in LCH.^{7,8} However, the evidence for therapeutic efficacy of MAPK inhibition (MAPKi) in established ND-CNS-LCH is limited.⁹

Neurofilament light-chain protein (NFL) in the cerebrospinal fluid (CSF) is a sensitive and well-established biomarker of neuroaxonal damage, irrespective of cause or clinical diagnosis.¹⁰ We have previously reported on elevated CSF NFL levels and monitoring in ND-CNS-LCH.^{11,12}

In our endeavour to reduce progressive neurodegeneration in LCH, we initiated treatment with MAPKi, between January 1, 2020, and June 30, 2020, in five children affected by CNS LCH. In parallel we monitored NFL and other biomarkers [tau, phospho-tau, and glial fibrillary acidic protein (GFAP)] in CSF. Clinical, laboratory and neuroradiological findings as well as treatments and outcome are presented in Table I,¹³ and more detailed clinical information in the Supplementary Material. Four patients, aged 2–17 years, had further developed ND-CNS-LCH with clinical and neuroradiological abnormalities; all had cognitive difficulties and two had additional neurological symptoms. Prior to treatment

with MAPKi, three children had each received at least seven different LCH-directed drugs each (Table I), with no or limited clinical, neuroradiological, or CSF NFL regression.

Patients 1, 2, 4, and 5 had LCH with *BRAF*^{V600E} mutation and were treated with dabrafenib 5.25 mg/kg/day. In patient 3, treated with trametinib 0.025 mg/kg/day, no *BRAF*^{V600E} mutation was identified but staining for phosphorylated extracellular-signal-regulated kinase (ERK) was positive indicating an activated MAPK signaling pathway (Table I).¹⁴ We also report routine CSF NFL levels in 12 additional children with LCH without evidence of ND-CNS-LCH (patient 6–17, Supporting Table SII). The study was approved by the Ethics Review Board of Sweden (2019-03956). Written informed consent was obtained for all five MAPKi-treated patients.

CSF NFL levels, typically monitored three-monthly after initiation of MAPKi, decreased markedly in all five children with CNS LCH (Fig 1). Within six months, CSF NFL had normalized (<380 ng/l) in four children and within nine months in all five (Fig 1, Supporting Table SI). In contrast, CSF NFL levels in patients 1 and 3 did not normalize on any other LCH-directed chemotherapy prior to MAPKi (Supporting Tables SI and SII).

Notably, CSF NFL levels increased again to abnormal levels within four months in the two patients whose MAPKi was discontinued (Fig 1, Supporting Table SI); in patient 1 due to an unclear inflammatory reaction and in patient 4 due to good response (see Supporting Text for details).

Among 16 CSF NFL samples from 11 additional children with LCH without known CNS LCH at sampling (patients 6–16, Supporting Table SII), only one was slightly elevated (440 ng/l). Of the three CSF samples from children with confirmed CNS LCH but without evidence of ND-CNS-LCH (patient 17 and patient 2 at DI diagnosis), only patient 2 had slightly elevated NFL (420 ng/l), which had been normal before DI. In contrast, CSF NFL levels were elevated in all 11 samples from the children with ND-CNS-LCH (Supporting Table SIII).

No remarkable differences were observed for tau, phospho-tau and GFAP in association with MAPKi or other therapies (Supporting Tables SI, SII). We did not encounter any severe complications in the 47 lumbar punctures performed.

MAPKi therapy was associated with perceivable neuroradiological and clinical improvement in three and two children,

Table 1. Clinical and laboratory findings in five children with CNS LCH.

| | Patient 1 | Patient 2 | Patient 3 | Patient 4 | Patient 5 |
|---|--|-------------------------------------|--|---|---|
| LCH prior to CNS LCH | | | | | |
| Sex | Male | Male | Male | Male | Female |
| Age at LCH diagnosis | 6 mo | 32 mo | 3-5 year | 15 mo | 23 mo |
| Craniofacial bones involved at diagnosis | Orbita, temporal, sphenoid | Temporal | None (parental report) | Temporal, sphenoid, orbita, maxilla, zygomaticus ^a | Orbita |
| All organs involved since diagnosis (prior to MAPKi) | Bone, CNS, probably skin | Bone, skin, CNS, possibly lungs | LN, lungs, CNS | Bone, skin, LN, liver, spleen, CNS, bone marrow ^{w,ab} | Bone, skin, CNS, bone marrow ^b |
| Maximal extent of disease | MS RO— | MS RO— | MS RO— | MS RO+ | MS RO— |
| Disease Activity Score at maximal extent ^c | 1 | 1 | N/A | 7 | 3 |
| Therapy before CNS LCH diagnosis | VBL, Pred, VCR, Ara-C, MTX, 6-MP, Dexa | VBL, Pred | VBL, Pred, VCR, Ara-C, MTX | VBL, Pred, MTX, 6-MP, HD-MTX, CsA, 2-Cda | VBL, Pred |
| Treatment effect | After reactivations finally NAD in bone but ND-LCH | Bone: AD better; CNS: AD worse (DI) | AD better | After multiple reactivations, finally NAD except ND-LCH | Skin and bone: NAD; CNS (pituitary stalk): AD better. |
| CNS LCH prior to MAPK inhibition | | | | | |
| Age at CNS LCH diagnosis | 14 mo | 37 mo | 7 year | 13 year | 23 mo |
| Endocrinopathies at CNS LCH diagnosis | DI | DI | DI, hypothyroidism. Later also GH deficiency | None | DI. Later also GH deficiency. |
| Cognitive affection | Yes | No | Yes | Yes | Yes |
| Neurological symptoms | Balance problems | None | None | None | Subtle leg weakness |
| Disease Activity Score prior to MAPK ^c | 0 | 0 | 1 | 0 | 1 |
| Elevated sedimentation rate (mm/h) | 24 | 6 | 19 | 2 | 7 |

Table 1. (Continued)

| | Patient 1 | Patient 2 | Patient 3 | Patient 4 | Patient 5 |
|---|--|---|--|--|---|
| GNS LCH MRI findings prior to MAPKi | Absent 'bright spot' ^d , normal pituitary stalk ^e Increased T2/FLAIR signal in dentate nuclei | Thickened pituitary stalk, absent 'bright spot' ^d Enlarged bilocular pineal cysts (present at diagnosis). No known ND ^g | Enlarged pons, adjacent medulla oblongata and mesencephalon with diffusely increased signal. Increased T2/FLAIR signal in globi pallidi and amygdala. Thickened pituitary stalk ^f . Partial improvement after 2-CdA. | Increased T2 signal in dentate nuclei and thalamus. | Thickened pituitary stalk, absent 'bright spot' ^d Increased T2/FLAIR signal in dentate nuclei. Reduced white-matter volume. Multiloculated pineal cysts. |
| Treatments given for CNS LCH prior to MAPKi | Ara-C | None | Pred, VCR, Ara-C, 2-CdA, MTX, 6-MP | None | None |
| Treatment effect; NFL before-after therapy | MRI unchanged; NFL 890-710 ng/l | – | CNS initially AD better/stable, then AD worse; NFL 1210-810 ng/l | – | – |
| CNS LCH on MAPK inhibition | | | | | |
| Age at start of MAPKi | 6.5 year | 39 mo | 12.5 year | 18 year | 42 mo |
| MAPK pathway status/mutation | BRAFV600E(PCR) | BRAFV600E(PCR) | pERK pos(IHC) | BRAFV600E(PCR) | BRAFV600E(PCR) |
| Treatment administered | Dabrafenib | Dabrafenib | Trametinib | Dabrafenib | Dabrafenib |
| Treatment duration | 5.25 mg/kg/day | 5.25 mg/kg/day | 0.025 mg/kg/day | 5.25 mg/kg/day | 5.25mg/kg/day |
| Comments | 4 mo (terminated) MAPKi stopped after 4 mo due to unclear inflammatory reaction | 6 mo (ongoing) | 8 mo (ongoing) | 6 mo (terminated) MAPKi stopped after 6 mo due to good therapy response | 7 mo (ongoing) |
| MRI changes on MAPKi | Unchanged ND findings, but new findings consistent with left mastoiditis ^h | Pituitary stalk and pineal cyst normalized | Pituitary stalk normalized. Enhanced signal in globi pallidi reduced. Increased cerebellar atrophy. | Unchanged | Pituitary stalk and pineal gland normalized. Regression of enhanced T2 signal in dentate nuclei. |
| Clinical changes on MAPKi | Stable/unchanged | Stable/unchanged | Stable/unchanged | Marked improvement of behavioral problems. Neuropsychological tests improved. | More physically active. Neuropsychological evaluation unchanged. |

Table 1. (Continued)

| | Patient 1 | Patient 2 | Patient 3 | Patient 4 | Patient 5 |
|---|-------------------------------|-------------------------------|------------------------------------|---|---|
| Changes in academic level on MAPKi | Continues in normal schooling | Continues in normal schooling | Remains in special needs education | Academic difficulties were reduced. Now following regular schooling | Individualized plan in kindergarten. Improvement of delayed language and motor skills |
| Disease Activity Score at last follow-up ^c | 0 | 0 | NA | 0 | 0 |
| Follow-up time after initiation of MAPKi | 11 mo | 11 mo | 11 mo | 10 mo | 9 mo |

AD, active disease; Ara-C, arabinoside cytosine; CNS, central nervous system; CsA, ciclosporin A; Dexa, dexamethasone; DI, diabetes insipidus; FLAIR, fluid-attenuated inversion-recovery; GH, growth hormone; HD, high-dose; LCH, Langerhans cell histiocytosis; LN, lymph nodes; MAPKi, mitogen-activated protein kinase inhibitor; MRI, magnetic resonance imaging; MS, multisystem; MTX, methotrexate; NA, not analyzed; N/A, not available; NAD, no active disease, ND, neurodegeneration; NFL, neurofilament light protein in CSF; PCR, polymerase chain reaction; pERK, phosphorylated extracellular-signal-regulated kinase; Pred, prednisolone; RO, risk organ; VBL, vinblastine; VCR, vincristine; 2-CdA, cladribine; 6-MP, 6-mercaptopurine.

^aDiagnosed in another country, data refer to available information.

^bBone marrow involvement (CD1a-pos cells) without haematopoietic involvement.

^cDisease Activity Score (DAS) according to Donadieu *et al.*, 2004 (ref 13).

^dPosterior pituitary bright spot.

^eMRI one year after DI diagnosis.

^fEarliest available MRI at nine years of age.

^gNo signs of clinical or neuroradiological neurodegeneration according to current definitions.

^hIn addition fever, anaemia and elevated inflammatory parameters, but unclear if these were side effects or due to an infection.

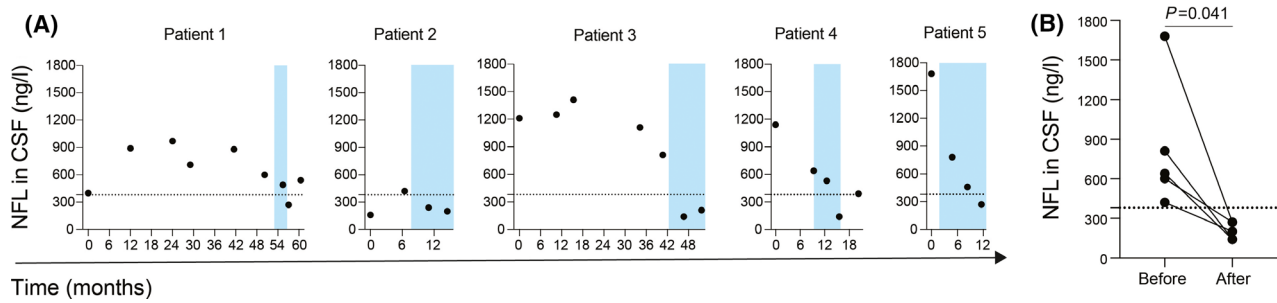


Fig 1. Neurofilament (NFL) levels in the cerebrospinal fluid (CSF) in the five children with central nervous system (CNS) affection of Langerhans cell histiocytosis (LCH) before and after initiation of treatment with mitogen-activated protein kinase pathway inhibitors (MAPKi). (A) Sequential neurofilament (NFL) levels in the CSF in patients 1–5. Duration of MAPKi therapy is indicated by the shaded area. The reference level (380 ng/l) is depicted as a dotted line. CSF NFL levels decreased markedly after initiation of treatment with MAPKi in all five children with CNS LCH. Within six months after treatment initiation, CSF NFL had normalized (<380 ng/l) in four children and within nine months in all five (see also Supporting Table SI). CSF NFL levels increased again after therapy cessation in patient 1 and 4. (B) The last CSF NFL value before initiation of MAPKi treatment is compared to the lowest CSF NFL value within nine months after initiation of MAPKi ($P = 0.041$, paired t -test). The reference level (380 ng/l) is depicted as a dotted line.

respectively (Table I). In patients 2, 3 and 5, a thickened pituitary stalk normalized and enlargement of the pineal cyst regressed. In patients 3 and 5, the enhanced signal in globi pallidi and dentate nuclei, respectively, was reduced (Supporting Figure S1). Patient 4 experienced impressive clinical improvement, behavioural problems disappeared, and neuropsychological tests improved, and patient 5 became more physically active. Limited adverse events were seen (fever, fatigue, myalgia in patient 1 and skin rash in patient 4).

Since clinical deterioration and the development of neuro-radiological abnormalities are slow processes in CNS LCH, a surrogate marker to monitor CNS LCH neurodegeneration and therapy response is most valuable. We have previously reported an association between elevated CSF NFL levels and neurodegeneration in CNS LCH.^{11,12} Based on the substantial amount of data on NFL in other neurodegenerative conditions,¹⁰ as well as our data on CSF NFL levels in patients with and without ND-CNS-LCH (Supporting Tables SI, SII), it seems likely that CSF NFL actually reflects the extent of ongoing neurodegeneration also in LCH.

Principal limitations to our study are the small patient number and short follow-up time. Nevertheless, with MAPKi treatment we noticed a remarkable normalization of CSF NFL levels not previously observed with other LCH-directed therapies (Supporting Table SII).¹² Similarly, CSF NFL levels were reduced in other diseases with specific disease-modifying treatments (natalizumab in relapsing/remitting multiple sclerosis; nusinersen in spinal muscular atrophy).^{10,15} One obvious drawback with MAPKi in CNS LCH is that the treatment likely has to be continued as long as clones with the disease-causing oncogenic mutations remain, as illustrated by increasing CSF NFL levels in the two patients that discontinued dabrafenib therapy (Fig 1A, Supporting Table SI).^{8,9}

To conclude, we suggest prospective clinical trials in patients with or at risk of developing ND-CNS-LCH, with

CSF NFL monitoring and, when appropriate, treatment with MAPKi and/or other relevant therapies, initiated early, preferably even before development of clinical or radiological signs of neurodegeneration. Relevant patients could be those with “CNS risk lesions”, multisystem disease, and known CNS involvement including endocrine deficiencies.¹ The aim would be to reduce, prevent and ideally eliminate clinical neurodegeneration in LCH.

Acknowledgements

The study was supported by grants from the Swedish Children’s Cancer Foundation (JIH, ML), the Swedish Cancer Foundation (JIH), the Cancer and Allergy Foundation of Sweden (JIH), and Region Stockholm (ALF-grant; JIH). The sponsors had no role in the design of the study, the collection and analysis of the data, or the preparation of the manuscript. HZ is a Wallenberg Scholar.


Author contributions

JIH conceived the study, consulted on patients, interpreted data, and drafted the manuscript. EK interpreted data, made figures, and assisted in drafting the manuscript. DMM reviewed MRIs and created figures. MCMK, BZ, TAN, CB, and IB treated patients and provided data. ML performed experiments and interpreted data. HZ and KB were responsible for analyses of neurodegenerative markers in patients 3–5. NH and DG interpreted data, assisted in drafting the manuscript, and DG also drafted Table SI. TvBG helped conceive the study, treated patients, consulted on patients, provided data, interpreted data, created Table I, and assisted in drafting the manuscript. JIH, EK, DG and TvBG verified the underlying data. All authors revised the manuscript critically for important intellectual content, had access to all the data in the study, and accept responsibility to submit for publication.

Conflict of interests


HZ has served at scientific advisory boards for Denali, Roche Diagnostics, Wave, Samumed, Siemens Healthineers, Pinteon Therapeutics and CogRx, has given lectures in symposia sponsored by Fujirebio, Alzecure and Biogen, and is a co-founder of Brain Biomarker Solutions in Gothenburg AB (BBS), which is a part of the GU Ventures Incubator Program (outside submitted work). KB has served as a consultant, at advisory boards and at data monitoring committees for Abcam, Axon, Biogen, JOMDD/Shimadzu, Julius Clinical, Lilly, MagQu, Novartis, Roche Diagnostics, and Siemens Healthineers, and is a co-founder of Brain Biomarker Solutions in Gothenburg AB (BBS), which is a part of the GU Ventures Incubator Program, all outside the submitted work. JIH has served as a consultant for Sobi, outside the submitted work. The other authors have no conflicts of interest to declare.

Jan-Inge Henter^{1,2} 

Egle Kvedaraitė^{1,3,4} 

Daniel Martín Muñoz^{5,6}


Monica Cheng Munthe-Kaas⁷

Bernward Zeller⁷ 

Tove A. Nystad⁸

Caroline Björklund⁹

Isabella Donner¹⁰

Magda Lourda^{1,3} 

Henrik Zetterberg^{11,12,13,14}

Kaj Blennow^{11,12}

Nikolas Herold^{1,2}

Désirée Gavhed^{1,2}

Tatiana von Bahr Greenwood^{1,2} 

¹Childhood Cancer Research Unit, Department of Women's and Children's Health, Karolinska Institutet, ²Pediatric Oncology, Astrid Lindgrens Children's Hospital, Karolinska University Hospital, ³Center for Infectious Medicine, Department of Medicine Huddinge, Karolinska Institutet, ⁴Department of Clinical Pathology, Karolinska University Laboratory, ⁵Department of Clinical Neuroscience, Karolinska Institutet, ⁶Department of Neuroradiology, Karolinska University Hospital, Stockholm, Sweden, ⁷Department of Pediatric Hematology and Oncology, Oslo University Hospital, Oslo, ⁸Department of Pediatrics, Division of Child and Adolescent Health, University Hospital of North-Norway, Tromsø, Norway, ⁹Department of Pediatric Hematology and Oncology, Umeå University Hospital, Umeå, ¹⁰Hallands Hospital, Halmstad, ¹¹Clinical Neurochemistry Laboratory, Sahlgrenska University Hospital, ¹²Department of Psychiatry and Neurochemistry, Institute of Neuroscience and Physiology the Sahlgrenska Academy at the University of Gothenburg, Mölndal, Sweden, ¹³UK Dementia Research Institute at UCL and ¹⁴Department of Neurodegenerative Disease, UCL Institute of Neurology, London, UK.

E-mail: Jan-Inge.Henter@ki.se

Keywords: Langerhans cell histiocytosis, central nervous system, neurodegeneration, mitogen-activated protein kinase inhibition, neurofilament light chain protein

Supporting Information

Additional supporting information may be found online in the Supporting Information section at the end of the article.

Table SI. Neurodegenerative biomarkers in the CSF in five children with CNS-LCH in relation to MAPKi treatment.

Table SII. Neurodegenerative biomarkers in the CSF of 15 children with LCH without or prior to MAPKi treatment.

Table SIII. Description of analysis methods for the CSF biomarkers.

Fig S1. Neuroradiological findings prior to and after MAPKi therapy.

References

- Rodriguez-Galindo C, Allen CE. Langerhans cell histiocytosis. *Blood*. 2020;**135**(16):1319–31.
- Grois N, Fahrner B, Arceci RJ, Henter JI, McClain K, Lassmann H, et al. Central nervous system disease in Langerhans cell histiocytosis. *J Pediatr*. 2010;**156**(6):873–81e1.
- Laurencikas E, Gavhed D, Stålemark H, Hooft IV, Prayer D, Grois N, et al. Incidence and pattern of radiological central nervous system Langerhans cell histiocytosis in children: a population based study. *Pediatr Blood Cancer*. 2011;**56**(2):250–7.
- Dhall G, Finlay JL, Dunkel IJ, Ettinger LJ, Kellie SJ, Allen JC, et al. Analysis of outcome for patients with mass lesions of the central nervous system due to Langerhans cell histiocytosis treated with 2-chlorodeoxyadenosine. *Pediatr Blood Cancer*. 2008;**50**(1):72–9.
- Imashuku S. High dose immunoglobulin (IVIG) may reduce the incidence of Langerhans cell histiocytosis (LCH)-associated central nervous system involvement. *CNS Neurol Disord Drug Targets*. 2009;**8**(5):380–6.
- Badalian-Very G, Vergilio J-A, Degar BA, MacConaill LE, Brandner B, Calicchio ML, et al. Recurrent BRAF mutations in Langerhans cell histiocytosis. *Blood*. 2010;**116**(11):1919–23.
- Kolenová A, Schwentner R, Jug G, Simonitsch-Klupp I, Kornauth C, Plank L, et al. Targeted inhibition of the MAPK pathway: emerging salvage option for progressive life-threatening multisystem LCH. *Blood Adv*. 2017;**1**(6):352–6.
- Donadieu J, Larabi IA, Tardieu M, Visser J, Hutter C, Sieni E, et al. Vemurafenib for refractory multisystem Langerhans cell histiocytosis in children: an international observational study. *J Clin Oncol*. 2019;**37**(31):2857–65.
- Eckstein OS, Visser J, Rodriguez-Galindo C, Allen CE, NACHO-LIBRE Study Group. Clinical responses and persistent BRAF V600E+ blood cells in children with LCH treated with MAPK pathway inhibition. *Blood*. 2019;**133**(15):1691–4. <https://doi.org/10.1182/blood-2018-10-878363>
- Khalil M, Teunissen CE, Otto M, Piehl F, Sormani MP, Gattringer T, et al. Neurofilaments as biomarkers in neurological disorders. *Nat Rev Neurol*. 2018;**14**(10):577–89.
- Gavhed D, Åkefeldt SO, Österlundh G, Laurencikas E, Hjorth L, Blennow K, et al. Biomarkers in the cerebrospinal fluid and neurodegeneration in Langerhans cell histiocytosis. *Pediatr Blood Cancer*. 2009;**53**(7):1264–70.
- Lourda M, Olsson-Åkefeldt S, Gavhed D, Axdorph Nygell U, Berlin G, Laurencikas E, et al. Adsorptive depletion of blood monocytes reduces the levels of circulating interleukin-17A in Langerhans cell histiocytosis. *Blood*. 2016;**128**(9):1302–5.

13. Donadieu J, Piguet C, Bernard F, Barkaoui M, Ouache M, Bertrand Y, et al. A new clinical score for disease activity in Langerhans cell histiocytosis. *Pediatr Blood Cancer*. 2004;**43**(7):770–6.
14. Diamond EL, Durham BH, Ulaner GA, Drill E, Buthorn J, Ki M, et al. Efficacy of MEK inhibition in patients with histiocytic neoplasms. *Nature*. 2019;**567**(7749):521–4.
15. Olsson B, Alberg L, Cullen NC, Michael E, Wahlgren L, Kroksmark A-K, et al. NFL is a marker of treatment response in children with SMA treated with nusinersen. *J Neurol*. 2019;**266**(9):2129–36.