

CLINICAL REVIEW

Frontotemporal dementia

 OPEN ACCESS

Jason D Warren *Wellcome Trust senior clinical fellow and reader in neurology*, Jonathan D Rohrer *clinical lecturer*, Martin N Rossor *senior investigator and director*

Dementia Research Centre, UCL Institute of Neurology, University College London, London WC1N 3BG, UK

Frontotemporal dementia (FTD) is a clinically and pathologically heterogeneous group of non-Alzheimer dementias characterised collectively by relatively selective, progressive atrophy involving the frontal or temporal lobes, or both.¹⁻⁴ Cases of FTD have been described since the late 19th century, initially most comprehensively by Arnold Pick, who lent his name to the historical designation of the entire FTD spectrum as Pick's disease. Only in the past three decades, however, has the clinical and pathological complexity of these diseases and their unique status as examples of selective brain degeneration been fully appreciated. FTD is substantially less common than Alzheimer's disease, with estimates of population prevalence ranging from four to 15 per 100 000 before age 65 years in European and US epidemiological studies.¹ However, this disease group is of disproportionate importance as a cause of young onset dementia and all the attendant socioeconomic and human costs that entails. Although onset is typically in the sixth decade of life, it may begin as early as the third or as late as the ninth decade, and the prevalence of FTD in older age groups has almost certainly been underestimated.

Here we provide a general overview of FTD, emphasising clinical aspects and highlighting recent progress and prospects. Figure 1 provides a schematic overview of FTD showing major clinical and neuroanatomical syndromes and diseases, and the relations between them.

What are the different syndromes of frontotemporal dementia?

There are three main clinical syndromes of FTD, defined on the basis of leading features at presentation. About half of cases present with behavioural change (behavioural variant frontotemporal dementia), and the remainder present with language decline (primary progressive aphasia) characterised either by impaired speech production (progressive non-fluent aphasia) or by impaired word comprehension and semantic memory (that is, memory for meaning) (semantic dementia). There is variable overlap clinically between the syndromes and atypical parkinsonism and motor neurone disease. New consensus diagnostic criteria for FTD⁵ and the progressive aphasias⁶ have recently been formulated, but they are likely to

be refined as more specific information about disease pathophysiology arises and neuroimaging and other techniques that can capture pathophysiological changes become available.

Methods for bedside assessment of behavioural variant frontotemporal dementia and the progressive aphasias are presented in the table and figure 2, respectively. It is particularly important for the non-specialist to have a workable framework for suspecting FTD, as diagnosis, particularly early in the course of the disease, is often challenging. In contrast to Alzheimer's disease (the most common cause of dementia in later life), FTD often presents in middle life, and memory and navigational skills and other aspects of general intellect are often well maintained initially. Behavioural or personality changes may at first suggest a primary psychiatric disorder, particularly if accompanied by psychotic features: clues that such features are harbingers of FTD may include a lack of any prior psychiatric history and emergence of certain specific symptoms such as changes in eating behaviour or social faux pas. Isolated language disturbances may also be misattributed to psychological factors: early features of primary progressive aphasia may include stumbling over longer words, emergence (or re-emergence) of a stutter, grammatical slips or problems using more specialised vocabulary associated with a profession or hobby (for example, a keen gardener may lose the names for flowers). Brain imaging (ideally with magnetic resonance imaging) is mandatory in all suspected cases of FTD to rule out mimic conditions such as brain tumours and to demonstrate signature atrophy patterns that may confirm the diagnosis or identify a non-degenerative "phenocopy."⁷

We now discuss symptoms and clinical findings in the major syndromes of FTD.

Behavioural variant frontotemporal dementia

This syndrome is characterised by progressive decline in interpersonal and executive skills, with altered emotional responsiveness and emergence of a variety of abnormal behaviours including apathy, disinhibition, obsessions, rituals, and stereotypies (see table 1).⁵ Behavioural variant FTD can develop indolently, and early detection may depend on subtle changes of social circumstances (such as switching jobs or

Summary points

- Frontotemporal dementia refers to a diverse group of conditions that collectively are a major cause of young onset dementia
- Frontotemporal dementia produces selective brain atrophy involving the frontal and temporal lobes, requiring brain magnetic resonance imaging for accurate diagnosis
- Clinically, these diseases present chiefly as progressive aphasia or as disintegration of personality and behaviour that may be misdiagnosed as a psychiatric disorder
- Up to around a quarter of cases arise from dominant mutations in one of three major causative genes
- Frontotemporal dementia is commonly associated with other neurological impairment, in particular parkinsonism or motor neurone disease
- Treatment remains supportive, but patients and families need extensive counselling, future planning, and involvement of social and mental health services

Sources and selection criteria

We examined recent literature on frontotemporal dementia, targeting full text English language studies published since 1990. We selected articles on the basis of our personal knowledge and searches of the Medline database using the terms "frontotemporal dementia," "frontotemporal lobar degeneration," "progressive nonfluent aphasia," "semantic dementia," and "logopenic aphasia," and each of these terms in conjunction with "diagnosis," "treatment," and "therapy." The final selection of references was based on our judgment of relevance, completeness, and compatibility with recent clinical, pathological, and genetic criteria.

partners), idiosyncratic lapses of taste or social awareness, reduced libido, altered dietary or musical preferences, or more childlike amusements. The relevant history has to be actively sought by speaking with the caregiver alone; forgetfulness may be volunteered as the presenting complaint, even though careful questioning often suggests that the patient's memory for everyday events is well maintained. To probe for a history of subtle behavioural change, we find it useful to ask the caregiver if the patient has said or done anything in public that has embarrassed other parties; if they seem less warm or affectionate (especially toward grandchildren or pets); if their food preferences have altered or narrowed or their table manners have declined; if they seem more concerned with timekeeping or tend to watch the clock; if there has been a change in their sense of humour; or if they have developed new hobbies or interests, especially with a religious or spiritual bent, and if these are pursued obsessively.

During the consultation, patients' spontaneous behaviours and interactions with others are often more revealing than formal neuropsychological testing: they may be impulsive or distractible, inert or impassive, disinhibited (picking up items unbidden from the examiner's desk) or socially unaware (fixing the examiner with a baleful stare). Cognitive assessment may reveal deficits of executive functions requiring formulation of a strategy, response inhibition, or abstraction: widely used bedside executive tests include verbal fluency (list as many words as possible in one minute, according to a nominated criterion such as starting letter or semantic category), cognitive estimates (make an educated guess about some arbitrary property or quantity, for example, the number of lions in Belgium), and proverb interpretation (summarise the abstract meaning behind a familiar saying). Memory and posterior cortical functions are often relatively spared, and indeed performance on standard psychometric tests is sometimes remarkably preserved. There is often a paucity of associated neurological signs, though primitive reflexes (forced grasping or rooting) may emerge later in the course, and behavioural variant FTD may be associated with extrapyramidal or motor neurone signs as part of an overlap syndrome.

Magnetic resonance imaging (MRI) findings in behavioural variant FTD are variable: there is often frontal and anterior temporal lobe atrophy (fig 1↓), which tends to be asymmetric between hemispheres and to spare more posterior cortical areas, but the degree and extent of atrophy vary widely among individuals. Altered white matter signal may be prominent,

usually in close proximity to areas of cortical atrophy, where it may reflect gliosis. Involvement of orbitofrontal cortex is an early harbinger of FTD⁸ but can be difficult to detect reliably, and brain atrophy may be detected only on serial studies. Metabolic brain imaging with single photon emission computed tomography (SPECT) or fluorodeoxyglucose positron emission tomography (FDG-PET) may be diagnostically useful in detecting regional dysfunction when structural imaging seems normal.⁹ Phenocopies of behavioural variant FTD with normal structural and metabolic brain imaging and lack of clear progression on serial neuropsychological assessment are increasingly recognised⁷: the nature of the underlying disease in these cases remains unclear.

Semantic dementia

This is a highly characteristic syndrome led by progressive breakdown of semantic memory—the memory system that stores knowledge about objects and concepts based on the individual's accumulated experience of the world. Typically, semantic dementia initially affects the highly elaborate brain knowledge system that mediates vocabulary—that is, knowledge of the meaning of words.¹⁰ Asking the meaning of familiar words, encountered, for example, in a menu ("What is asparagus?"), is pathognomonic of semantic dementia. Patients commonly present with fluent (or even garrulous) but empty, circumlocutory speech with early prominent difficulty retrieving names, use of less precise terms, and impaired comprehension of word meanings, accounting for the "semantic variant of progressive aphasia" in the current classification (see fig 2↓).⁶ Early in the course of the disease, the semantic deficit may be well compensated and may emerge only on testing more specialised knowledge previously at the patient's command. A more pervasive semantic impairment also affecting visual information (impaired recognition of familiar faces (prosopagnosia) or of visual objects (visual agnosia)) and other non-verbal domains such as odours and flavours generally develops later in the disease course, as do behavioural disturbances broadly similar to those in behavioural variant FTD.¹⁰ The general neurological examination is usually normal.

Semantic dementia shows a highly consistent and characteristic neuroanatomical (MRI) profile with selective, asymmetric anteroinferior temporal lobe cortical atrophy and hypometabolism (fig 1↓),¹¹ the gyral glia at the temporal poles often persisting only as a residual "knife blade" skeleton. Atrophy is predominantly left sided but may be right sided in

cases led by non-verbal semantic deficits,¹² with spread between the cerebral hemispheres and into more posterior temporal and inferior frontal cortices over time.

Progressive non-fluent aphasia

This syndrome is led by a progressive breakdown in language output with effortful non-fluent speech. Several more or less distinct neurolinguistic syndromes are subsumed under the general category of progressive non-fluent aphasia.¹³ In some patients, speech sound (phonemic) or articulatory (phonetic, speech apraxic) errors are the dominant feature; whereas in others the syndrome is dominated by expressive agrammatism with terse telegraphic phrases (see fig 2⇓). These features commonly coexist as the disease evolves. Apraxia of other orofacial movements or swallowing often accompanies speech apraxia and is tested by asking the patient to yawn or cough, which they are unable to do to command, although they can as a reflex. Impaired sentence comprehension can generally be demonstrated on neuropsychological assessment, and literacy skills become affected in most cases. Progressive non-fluent aphasia may herald the onset of a neurological overlap syndrome with atypical parkinsonism or less commonly motor neurone features.

Brain atrophy and hypometabolism in progressive non-fluent aphasia often affects perisylvian cortices in the dominant hemisphere mediating speech production (fig 1⇓).¹⁴ However, the profile of atrophy varies widely in extent and severity between patients.

A third clinical syndrome of progressive aphasia, logopenic (Greek “few words”) aphasia, presents with hesitant but grammatically correct speech marred by word-finding pauses, anomia, and impaired phonological working memory manifesting as disproportionate difficulty repeating spoken phrases versus single words (fig 2⇓). Most cases will have underlying Alzheimer pathology,⁶ and more widespread cognitive deficits similar to those accompanying other Alzheimer phenotypes emerge later in the disease course. Brain MRI often shows predominantly left sided temporoparietal atrophy,¹⁴ though with substantial individual variation that overlaps with the neuroanatomical profile of progressive non-fluent aphasia.

Overlap syndromes

The FTD spectrum overlaps with the syndromes of progressive supranuclear palsy, corticobasal syndrome, and FTD with motor neurone disease. The progressive supranuclear palsy syndrome is characterised by impairment of vertical gaze, early postural instability with falls, and frontal behavioural changes with marked cognitive slowing (fronto-subcortical).¹⁵ Features of corticobasal syndrome include asymmetric apraxia accompanied by rigidity and myoclonus and classically non-volitional or “alien” actions of the affected limb.¹⁵ The phenotype may include prominent behavioural or language deficits.¹⁶

In the syndrome of FTD with motor neurone disease, behavioural or language dysfunction may evolve in tandem with motor neurone disease. However, all patients with FTD presentations should be assessed for the appearance of motor neurone signs (often initially deltoid or triceps fasciculations), while cognitive and behavioural involvement in patients presenting with motor neurone disease is almost certainly under-recognised. Neurophysiological studies may confirm widespread denervation, but for uncertain reasons this is often normal earlier in the course of FTD with motor neurone disease.

As the genetic and pathological spectrum of FTD has become better defined, it has been recognised that molecular pathologies in this spectrum can alternatively present with clinical syndromes more typical of other neurodegenerative diseases, in particular Alzheimer’s disease.

How is frontotemporal dementia distinguished from other diseases?

FTD syndromes must be distinguished from non-degenerative processes that present with prominent behavioural, executive, and language disturbance (such as primary psychiatric illness, tumours, and cerebrovascular disease) and from other neurodegenerative diseases (notably atypical variants of Alzheimer’s disease).⁶ Although cerebrovascular changes are common on brain MRI in older patients, primary progressive aphasia can usually be distinguished from vascular aphasic syndromes based on a history of insidious deterioration; the distinction between behavioural variant FTD and cerebrovascular behavioural syndromes is more challenging, but may rest on the relative extent of vascular and regional atrophic changes. Neuropsychological assessment is valuable in substantiating the bedside impression—particularly for detecting “subclinical” involvement of cognitive domains that help to define the phenotype, for quantifying impairment in domains that may be difficult to assess at the bedside (such as semantic memory or sentence comprehension), and for tracking deterioration over time. On MRI, lack of the focal brain atrophy profiles that characterise FTD or prominent white matter change are important clues to an alternative disease.

Because of the wide phenotypic variation within the spectra of Alzheimer’s disease and FTD, it can be difficult to differentiate FTD from Alzheimer’s disease in an individual case based on clinical and imaging features.¹⁷ Clinical “red flags” that a patient has FTD rather than Alzheimer’s disease include early prominent behavioural features, especially if the social façade breaks down or insight is lost and if episodic and topographical memory remain relatively intact. Profiling of neurodegeneration marker proteins in cerebrospinal fluid is increasingly used in clinical diagnosis: a raised ratio of total tau protein to beta amyloid1 42 peptide sensitively predicts Alzheimer’s pathology,¹⁸ and incorporation of other amyloid and phosphorylated tau species may further enhance diagnosis.¹⁹ Cerebrospinal fluid profiling is likely in future to be supplemented by molecular neuroimaging (for example, for amyloid) and by more specialised structural MRI analysis tools. One large study found that cerebrospinal fluid profiling and analysis of brain MRI data with a specialised classifier algorithm could distinguish pathologically proven FTD from Alzheimer’s disease with around 75% accuracy.²⁰ However, such techniques remain to be widely translated beyond specialist centres.

What causes frontotemporal dementia?

The common pathological theme underpinning FTD is tissue deposition of abnormally aggregated proteins (see fig 1⇓).¹ 2 Three major pathogenic proteins have been implicated in FTD: cases with cellular inclusions containing predominantly phosphorylated tau or transactive response DNA-binding protein 43 (TDP-43) are approximately equally represented in autopsy series, while a substantial minority have inclusions containing fused in sarcoma (FUS) protein. These have been further classified into distinct subtypes, with only a dwindling minority of FTD cases having inclusions in which the pathogenic protein is unclear (see fig 1⇓).

FTD has a substantial genetic component, with an autosomal dominant inheritance pattern or identifiable disease-causing mutations in around 10-20% of cases across large published series,^{3,4} and some family history in a higher proportion. Most familial cases of FTD have mutations in the microtubule associated protein tau (MAPT) or progranulin (GRN) genes or the recently identified hexanucleotide repeat expansion in the C9ORF72 gene (see fig 1).⁴ Less often, mutations in the gene encoding valosin containing protein (VCP) cause FTD in association with inclusion body myositis and Paget's disease of bone.⁴

Can we predict molecular pathologies in frontotemporal dementia?

Despite recent histopathological and genetic advances,^{2,4} accurate prediction of underlying molecular pathologies within the FTD spectrum remains problematic (fig 1). This has important implications for targeting future disease modifying therapies and, more immediately, for counselling of patients and family members. While phenotypic variation and overlap are substantial, certain clinico-anatomical profiles are consistently associated with particular molecular pathologies (see fig 1).²¹ These include FTD with motor neurone disease associated with TDP-43 pathology; the semantic dementia syndrome and focal, asymmetric temporal lobe atrophy with TDP-43 type C pathology; behavioural variant FTD of very young onset and prominent caudate atrophy with FUS pathology; and the progressive supranuclear palsy syndrome with a specific tauopathy. Non-fluent speech breakdown and the development of parkinsonism are more commonly associated with tau than non-tau pathologies. The heritability of particular FTD syndromes varies substantially:³ semantic dementia is generally sporadic, whereas behavioural variant FTD and corticobasal syndrome are highly genetically as well as pathologically heterogeneous. Useful neuroanatomical associations which may help guide genetic testing include relatively symmetric anteromedial temporal lobe atrophy with MAPT mutations and striking asymmetric hemispheric atrophy with GRN mutations (see fig 1).⁴

What is the prognosis in frontotemporal dementia?

The clinical course of all FTD syndromes is steadily progressive, with declining function in everyday life and accumulation of social, cognitive, and neurological disabilities leading to complete dependency requiring institutional care. However, survival duration based on meta-analyses is highly variable across the FTD spectrum²²: the most aggressive course is associated with FTD with motor neurone disease, leading to death typically within three to five years of symptom onset, whereas a substantial proportion of patients (particularly those with semantic dementia) survive for well over a decade. There tends to be convergence of syndromes over time,²³ with emergence of non-cognitive neurological features in many cases, and the precise clinical trajectory is difficult to predict in individual cases. Wandering and intrusive behaviours, apathy, incontinence, mutism, and dysphagia are common issues toward the end of life and important sources of caregiver distress. The burden placed on those who care for patients with FTD is great, even in comparison with other neurodegenerative diseases.²⁴

What are the management options in frontotemporal dementia?

There are no therapies currently shown to alter the evolution of any of the diseases in the FTD spectrum. Management is therefore directed to controlling symptoms and otherwise helping patients and their caregivers cope with the impact of their illness, including engagement of community mental health, social services, day centres, and other support networks. Patients and families need clear and specific advice as they face a future of increasing dependency, often including occupational and financial planning. This is particularly urgent where (as is often the case in FTD) patients lack insight into the true extent of their difficulties. Early, accurate diagnosis and mobilisation of appropriate support services at present offer the best prospect of effective management for patients with FTD.

Non-pharmacological management strategies are based largely on anecdote and clinical experience rather than controlled evidence.²⁴ Safety and risk management are important considerations that may entail environmental or other modifications affecting diverse aspects of the patient's daily life: depending on the disease stage, these may include occupational and social activities, children or other vulnerable dependents, driving, swallowing, and mobility. Decisions about safety and competence may be particularly challenging earlier in the course of behavioural variant FTD, but the desire to preserve autonomy must be weighed against the potential for occupational, financial, social, or forensic hazards.

Simple interventions (puzzles, music, and other structured activities, controlled access to food and drink) may help govern troublesome behaviours and contribute to a stable routine. Motor and gait symptoms should be anticipated as the disease evolves. Speech and language therapy can provide simple communication aids, as well as assessment of swallowing and advice on dietary modification, and mobility and continence aids often become necessary later in the course. Programmed respite, counselling, and psychological support for caregivers should not be overlooked: in contrast to other neurodegenerative diseases (notably Alzheimer's disease), FTD tends to strike early at the core of personal identity, and the sense of living with a stranger is often a source of profound distress for families and caregivers. Genetic counselling of at-risk family members adds a further challenge and should always be undertaken in collaboration with a clinical genetics service.

Options for pharmacotherapy are limited. The available evidence is derived largely from small, open label studies or case reports.²⁴ Open label studies have shown no clear symptomatic benefit for cholinesterase inhibitors or memantine,²⁴ and one randomised, double blind trial of memantine in behavioural variant FTD was also negative²⁵; these agents may aggravate behavioural disturbance. Small, double blind, controlled trials have provided some evidence for modest improvement of behavioural symptoms with trazodone²⁶ though not paroxetine.²⁷ Clinical experience suggests that selective serotonin reuptake inhibitors may be useful in modulating intrusive or compulsive behaviours in some patients. Neuroleptic drugs are potentially associated with substantial risk of extrapyramidal and cognitive side effects,²⁸ but adequate controlled studies to estimate the risk-benefit balance of these agents in FTD are lacking.²⁴ For the moment, it seems pragmatic to reserve use of neuroleptics to newer generation agents at low doses when required for agitation that threatens the patient's wellbeing and cannot be managed by other means. Limited data from a single randomised controlled trial suggest a transient benefit of intranasal oxytocin on emotion processing in behavioural variant FTD.²⁹

What are the future prospects for therapy?

Translation of recent molecular progress into targeted therapies of the proteinopathies underpinning FTD seems likely to depend on earlier and more accurate disease detection and tracking as much as on animal and cellular models for drug development. More information is required about the clinical course of FTD syndromes, the early and presymptomatic manifestations of disease, and functional landmarks that subsequently affect patients' daily lives. There is a particularly urgent need for new in vivo markers of specific pathological proteins (for example, tau binding ligands) and novel metrics of brain network disintegration and pathophysiology and complex behavioural symptoms in order to capitalise on recent insights from systems neuroscience.

Genetic forms of FTD may be particularly attractive candidates for targeted therapies, as there is potential for presymptomatic disease detection. One promising example is progranulin, which can be measured in plasma and for which there is considerable information concerning disease biology.³⁰

Collaboration among specialist centres, such as the Genetic Frontotemporal Dementia Initiative,³¹ with access to well characterised cohorts of patients with FTD will be essential to mount large scale trials of rationally targeted therapies that may finally allow us to treat these devastating diseases.

Contributors: JDW and MNR had the idea for the article. JDW and JDR performed the literature review. All authors were involved in writing and critically revising the article. JDW and MNR jointly accept full responsibility for the work and controlled the decision to publish.

Funding: This research was supported by the National Institute for Health Research (NIHR) Queen Square Dementia Biomedical Research Unit, the Medical Research Council, and the Wellcome Trust. The views expressed are those of the author(s) and not necessarily those of the NHS, the NIHR, or the Department of Health.

Competing interests: We have read and understood the BMJ Group policy on declaration of interests and declare the following interests: financial support for the submitted work from Wellcome Trust and the Medical Research Council. JDW has received research grants from the Wellcome Trust, Medical Research Council, and Alzheimer's Research UK. JDR has previously received research grants from the Wellcome Trust. MNR receives a consultancy fee as a member of the Safety Monitoring Committees for Janssen AI/Pfizer and Servier (paid into departmental funds not to MNR personally) and his department receives a grant from Pfizer for phase III imaging analysis; he is a director of the NIHR Dementia and Neurodegenerative Diseases Research Network, president of the Association of British Neurologists, a member of Neurology Scientific Advisory Group, EMA and Neurology and Psychiatry Group MHRA, and a vice president of the Alzheimer's Society.

Provenance and peer review: Commissioned; externally peer reviewed.

- Rabinovici GD, Miller BL. Frontotemporal lobar degeneration: epidemiology, pathophysiology, diagnosis and management. *CNS Drugs* 2010;24:375-98.
- Mackenzie IR, Neumann M, Baborie A. A harmonized classification system for FTD-TDP pathology. *Acta Neuropathol* 2011;122:111-3.
- Rohrer JD, Guerreiro R, Vandrovicova J, Uphill J, Reiman D, Beck J, et al. The heritability and genetics of frontotemporal lobar degeneration. *Neurology* 2009;73:1451-6.
- Rohrer JD, Warren JD. Phenotypic signatures of genetic frontotemporal dementia. *Curr Opin Neurol* 2011;24:542-9.

- Rascovsky K, Hodges JR, Knopman D, Mendez MF, Kramer JH, Neuhaus J, et al. Sensitivity of revised diagnostic criteria for the behavioural variant of frontotemporal dementia. *Brain* 2011;134:2456-77.
- Gorno-Tempini ML, Hillis AE, Weintraub S, Kertesz A, Mendez M, Cappa SF, et al. Classification of primary progressive aphasia and its variants. *Neurology* 2011;76:1006-14.
- Kipps CM, Hodges JR, Fryer TD, Nestor PJ. Combined magnetic resonance imaging and positron emission tomography brain imaging in behavioural variant frontotemporal degeneration: refining the clinical phenotype. *Brain* 2009;132:2566-78.
- Perry RJ, Graham A, Williams G, Rosen H, Erzinçoglu S, Weiner M, et al. Patterns of frontal lobe atrophy in frontotemporal dementia: a volumetric MRI study. *Dement Geriatr Cogn Disord* 2006;22:278-87.
- Mendez MF, Shapira JS, McMurtry A, Licht E, Miller BL. Accuracy of the clinical evaluation for frontotemporal dementia. *Arch Neurol* 2007;64:830-5.
- Hodges JR, Patterson K. Semantic dementia: a unique clinicopathological syndrome. *Lancet Neurol* 2007;6:1004-14.
- Rohrer JD, Warren JD, Modat M, Ridgway GR, Douiri A, Rossor MN, et al. Patterns of cortical thinning in the language variants of frontotemporal lobar degeneration. *Neurology* 2009;72:1562-9.
- Seeley WW, Bauer AM, Miller BL, Gorno-Tempini ML, Kramer JH, Weiner M, et al. The natural history of temporal variant frontotemporal dementia. *Neurology* 2005;64:1384-90.
- Rohrer JD, Rossor MN, Warren JD. Syndromes of nonfluent primary progressive aphasia: a clinical and neurolinguistic analysis. *Neurology* 2010;75:603-10.
- Rohrer JD, Ridgway GR, Crutch SJ, Hailstone J, Goll JC, Clarkson MJ, et al. Progressive logopenic/phonological aphasia: erosion of the language network. *Neuroimage* 2010;49:984-93.
- Litvan I, Bhatia KP, Burn DJ, Goetz CG, Lang AE, McKeith I, et al. Movement Disorders Society Scientific Issues Committee. Movement Disorders Society Scientific Issues Committee report: SIC Task Force appraisal of clinical diagnostic criteria for Parkinsonian disorders. *Mov Disord* 2003;18:467-86.
- Kertesz A, McMonagle P. Behavior and cognition in corticobasal degeneration and progressive supranuclear palsy. *J Neurol Sci* 2010;15:138-43.
- Xiong L, Xuereb JH, Spillantini MG, Patterson K, Hodges JR, Nestor PJ. Clinical comparison of progressive aphasia associated with Alzheimer versus FTD-spectrum pathology. *J Neurol Neurosurg Psychiatry* 2011;82:254-60.
- Bian H, Van Swieten JC, Leigh S, Massimo L, Wood E, Forman M, et al. CSF biomarkers in frontotemporal lobar degeneration with known pathology. *Neurology* 2008;70:1827-35.
- Verwey NA, Kester MI, van der Flier WM, Veerhuis R, Berkhof H, Twaalfhoven H, et al. Additional value of CSF amyloid beta 40 levels in the differentiation between FTD and control subjects. *J Alzheimers Dis* 2010;20:445-52.
- McMillan CT, Avants B, Irwin DJ, Toledo JB, Wolk DA, Van Deerlin VM, et al. Can MRI screen for CSF biomarkers in neurodegenerative disease? *Neurology* 2013;80:132-8.
- Rohrer JD, Lashley T, Schott JM, Warren JE, Mead S, Isaacs AM, et al. Clinical and neuroanatomical signatures of tissue pathology in frontotemporal lobar degeneration. *Brain* 2011;134:2565-81.
- Brodzky H, Seeher K, Gibson L. Dementia time to death: a systematic literature review on survival time and years of life lost in people with dementia. *Int Psychogeriatr* 2012;24:1034-45.
- Kertesz A, McMonagle P, Blair M, Davidson W, Munoz DG. The evolution and pathology of frontotemporal dementia. *Brain* 2005;128:1996-2005.
- Seltman RE, Matthews BR. Frontotemporal lobar degeneration: epidemiology, pathology, diagnosis and management. *CNS Drugs* 2012;26:841-70.
- Vercelletto M, Boutoulet-Bretonnière C, Volteau C, Puel M, Auriacombe S, Sarazin M, et al. Memantine in behavioral variant frontotemporal dementia: negative results. *J Alzheimers Dis* 2011;23:749-59.
- Lebert F, Stekke W, Hasenbroeck C, Pasquier F. Frontotemporal dementia: a randomised, controlled trial with trazodone. *Dement Geriatr Cogn Disord* 2004;17:355-9.
- Deakin JB, Rahman S, Nestor PJ, Hodges JR, Sahakian BJ. Paroxetine does not improve symptoms and impairs cognition in frontotemporal dementia: a double-blind randomized controlled trial. *Psychopharmacol* 2004;172:400-8.
- Czarnecki K, Kumar N, Josephs KA. Parkinsonism and tardive antecollis in frontotemporal dementia—increased sensitivity to newer antipsychotics? *Eur J Neurol* 2008;15:199-201.
- Jesso S, Morlog D, Ross S, Pell MD, Pasternak SH, Mitchell DG, et al. The effects of oxytocin on social cognition and behaviour in frontotemporal dementia. *Brain* 2011;134:2493-501.
- Gass J, Prudencio M, Stetler C, Petrucelli L. Progranulin: an emerging target for FTLT therapies. *Brain Res* 2012;1462:118-28.
- Rohrer JD, Frisoni GB, Galimberti D, Masellis M, Rowe JB, Borroni B, et al. GENFI—The GENetic Frontotemporal Dementia Initiative. *Dement Geriatr Cogn Disord* 2012;34(suppl 1):1-289.
- Seeley WW, Crawford RK, Zhou J, Miller BL, Greicius MD. Neurodegenerative diseases target large-scale human brain networks. *Neuron* 2009;62:42-52.
- Mahoney CJ, Malone IB, Ridgway GR, Buckley AH, Downey LE, Golden HL, et al. White matter tract signatures of the progressive aphasias. *Neurobiol Aging* 2013. doi:10.1016/j.neurobiolaging.2012.12.002. [epub ahead of print].
- Warren JD, Rohrer JD, Schott JM, Fox NC, Hardy J, Rossor MN. Molecular nexopathies: a new paradigm of neurodegenerative disease. *Trends Neurosci* (forthcoming).

Cite this as: *BMJ* 2013;347:f4827

This is an Open Access article distributed in accordance with the Creative Commons Attribution Non Commercial (CC BY-NC 3.0) license, which permits others to distribute, remix, adapt, build upon this work non-commercially, and license their derivative works on different terms, provided the original work is properly cited and the use is non-commercial. See: <http://creativecommons.org/licenses/by-nc/3.0/>.

Questions for further research

- Can tissue pathology be predicted reliably in frontotemporal dementia (FTD)? Identification of clinical, brain imaging, laboratory, and other markers of underlying pathology may allow targeting of disease modifying treatments in FTD
- What are the earliest features of disease onset in FTD? Identification of early—ideally, presymptomatic—markers of disease onset may allow intervention while structural brain damage is minimal, especially in genetic cases
- How can the evolution of FTD be tracked reliably? More detailed information about the clinical course of FTD would allow treatments to be evaluated and monitored
- What are the markers of prognosis and survival in individual patients with FTD? Identification of reliable prognostic markers would allow more specific advice to be given to patients and caregivers

Tips for non-specialists

- In contrast to Alzheimer's disease (the most common cause of dementia in later life), frontotemporal dementia (FTD) often presents in middle life, and memory and navigational skills are often well maintained initially
- Behavioural or personality change first developing in later life may signal the onset of FTD rather than a primary psychiatric disorder, even if there are psychotic features, and particularly if heralded by changes in eating behaviour or social faux pas
- Problems articulating longer words, emergence of a stutter, grammatical slips, searching for words, or loss of comprehension of words (asking the meaning of words) may herald the onset of progressive aphasia
- Brain imaging (ideally with MRI) is mandatory in all suspected cases of FTD to rule out mimics such as brain tumours and to confirm the diagnosis

Additional educational resources

- Association for Frontotemporal Degeneration (www.theaftd.org/about/our-mission)—Free resource
- e-Brain e-learning initiative (www.ebrainjnc.com/)—Interactive online learning for professionals in the neurosciences. Registration required

Resources for patients and caregivers

- Alzheimer's Society frontotemporal dementia fact sheet (www.alzheimers.org.uk/site/scripts/documents_info.php?documentID=167)—Freely available factsheet "What is fronto-temporal dementia (including Pick's disease)?"
- Frontotemporal Dementia Support Group (www.ftdsg.org/)—Free resource including web links to many other useful lay resources
- Support groups based at the Dementia Research Centre (www.ucl.ac.uk/drc/support-groups)—Free resource from Dementia Research Centre, UCL Institute of Neurology, London

Table**Table 1 | Bedside assessment of behavioural variant frontotemporal dementia (adapted from Rascovsky et al⁵)**

Main behavioural features and subtypes*	Examples†
Disinhibition:	
Socially inappropriate behaviour	Inappropriately approaching, touching, or kissing strangers, verbal or physical aggression, fatuity, staring
Loss of manners or decorum	Inappropriate laughter, jokes, or opinions that may be offensive to others, faux pas, lack of etiquette, altered dress sense
Impulsive, rash, or careless actions	Reckless driving, new onset gambling, buying or selling objects without regard for consequences
Apathy and inertia:	
Apathy	Lacking initiative, ceasing to engage in former activities or hobbies, poor personal hygiene
Inertia	Needs prompting to initiate or continue routine activities, less likely to initiate or sustain a conversation
Reduced autonomy	Environmental dependency, utilisation behaviours (such as handling or using items or reading signs aloud when not required or appropriate to social context)
Loss of sympathy and empathy:	
Diminished response to other people's needs and feelings	Making hurtful comments or disregarding other people's pain or distress, less warmth or interest toward others (such as grandchildren, pets), hypoemotionality, failure to appreciate ambiguous social signals (such as sarcasm)
Diminished social interest, interrelatedness, or personal warmth	Decrease in social engagement, emotional detachment, distant from friends and relatives, reduced libido, altered sense of humour
Perseverative, stereotyped, and compulsive or ritualistic behaviour:	

(continued)

Main behavioural features and subtypes*	Examples†
Simple repetitive movements	Tapping, clapping, rubbing, scratching, picking at self, humming, rocking
Complex, compulsive, or ritualistic behaviours	Counting and cleaning rituals, collecting or hoarding, checking, ordering objects, walking fixed routes, clock watching, new obsessional interests or preoccupations (such as religiosity, musicophilia)
Stereotypy of speech	Habitual repetition of words, phrases, or themes
Hyperorality and dietary changes:	
Altered food preferences	Carbohydrate cravings (particularly sweets), food fads
Binge eating, increased consumption of alcohol or cigarettes	Consuming excessive amounts of food, gluttony, rapid, messy eating, overfilling mouth, compulsive use of alcohol or smoking
Oral exploration or consumption of inedible objects	Pica, features of Kluver-Bucy syndrome
Loss of insight	Unaware of or unconcerned by difficulties
Others:	
Psychotic features‡	Hallucinations (especially somatic or visual), delusions (especially somatic or paranoid)‡
Altered sensitivity to pain	Hypochondriasis, heightened distress with innocuous stimuli, lack of distress in response to painful stimuli
Altered temperature sensibility	Dressing inappropriate to climate

*Within the broad phenotype of behavioural variant frontotemporal dementia; clinical features in individual patients are highly variable.

†Early features are often loss of warmth and empathy, social faux pas, and altered eating behaviour or food preferences.

‡Especially in association with expansions in the C9ORF72 gene.

Figures

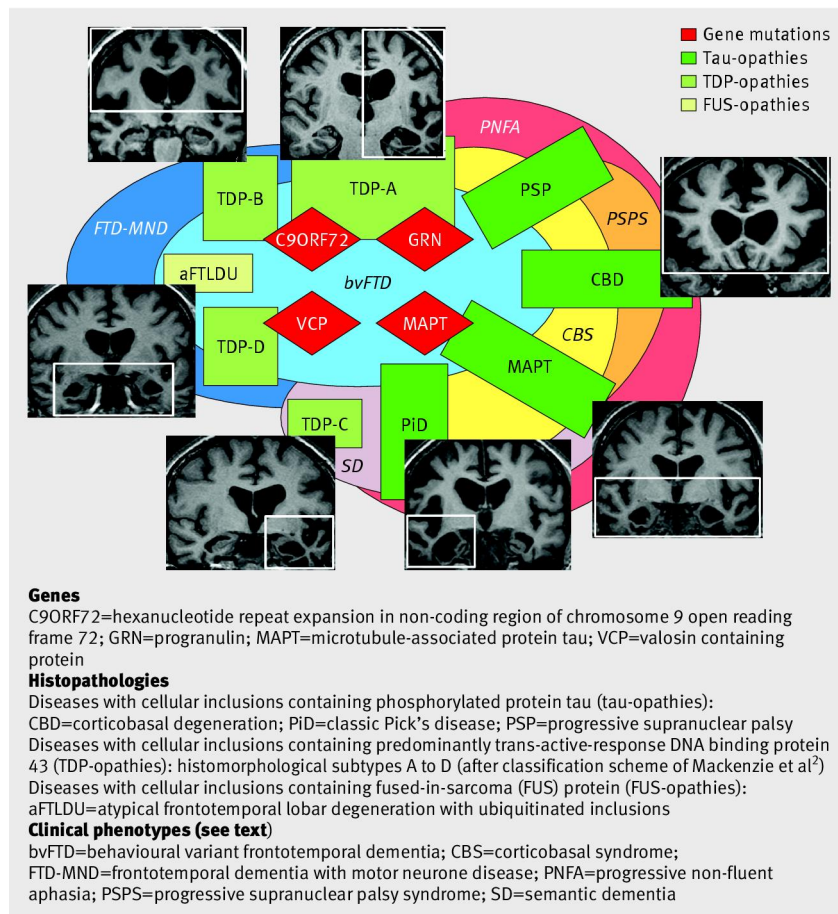


Fig 1 Molecular pathologies and phenotypic correlations in frontotemporal dementia. The schematic shows major genes causing frontotemporal dementia, histopathological substrates, and clinical phenotypes. Neuroanatomical profiles are shown as coronal magnetic resonance imaging sections (left hemisphere displayed on the right) abutting the corresponding pathological substrates, with regions of predominant regional atrophy demarcated by white rectangles. Genetic bases for pathological substrates and phenotypic associations of tissue pathologies are shown as intersecting (for example, mutations in the progranulin gene (GRN) are associated with TDP-43 type A (TDP-A) pathology, which may be associated with clinical syndromes of behavioural variant frontotemporal dementia (bvFTD), progressive non-fluent aphasia (PNFA), corticobasal syndrome (CBS), and frontotemporal dementia with motor neurone disease (FTD-MND)). Group functional neuroimaging studies have demonstrated involvement of intrinsic, large scale brain networks in FTD syndromes: a medial paralimbic network (including anterior cingulate, orbital frontal, and frontoinsula cortices) in bvFTD³²; an anterior temporal and inferior frontal network in semantic dementia^{32,33}; and dorsally directed dominant hemisphere language networks in PNFA.^{32,33} However, the network correlates of particular molecular pathologies are less well established.³⁴ This scheme arranges diseases according to whether they produce damage that is relatively more restricted to anterior (toward left of figure) areas or extends posteriorly (toward right of figure) within each cerebral hemisphere; whether damage within a hemisphere is more focally restricted to the temporal lobes (toward bottom of figure) or more distributed (toward top of figure); and according to the degree of asymmetry of involvement between the two hemispheres (more asymmetrical diseases shown more centrally)^{21,34}

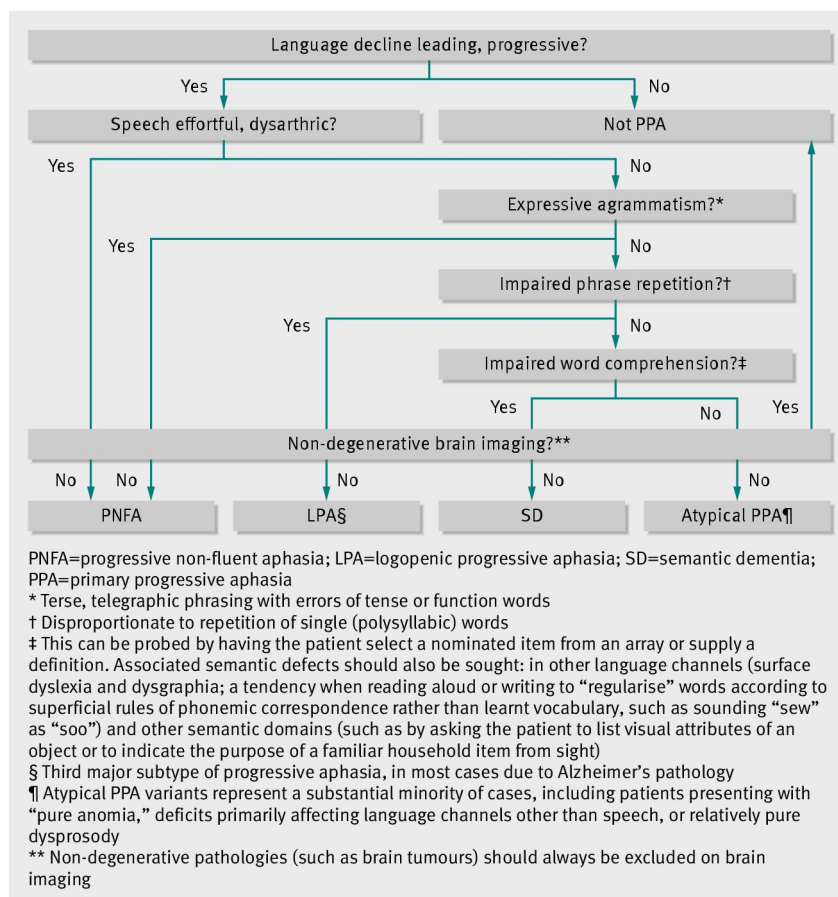


Fig 2 Bedside clinical assessment of the progressive aphasias: a simple algorithm (informed by current consensus criteria for progressive aphasia⁶) for syndromic diagnosis of patients presenting with progressive language decline. The clinical syndromic diagnosis should be supplemented by neuropsychological assessment, brain magnetic resonance imaging, and ancillary investigations including cerebrospinal fluid examination (see text)