



Lesions impairing regular versus irregular past tense production



Lotte Meteyard^{a,*}, Cathy J. Price^b, Anna M. Woollams^c, Jennifer Aydelott^d

^a School of Psychology & Clinical Language Sciences, University of Reading, UK

^b Wellcome Trust Centre for Neuroimaging, Institute of Neurology, London, UK

^c Neuroscience and Aphasia Research Unit, School of Psychological Sciences, University of Manchester, UK

^d Department of Psychological Sciences, Birkbeck, University of London, UK

ARTICLE INFO

Article history:

Received 30 April 2013

Received in revised form 2 October 2013

Accepted 3 October 2013

Available online 14 October 2013

Keywords:

Anterior temporal pole

Supramarginal gyrus

Morphology

Pars opercularis

Phonology

Regularity

Inflection

ABSTRACT

We investigated selective impairments in the production of regular and irregular past tense by examining language performance and lesion sites in a sample of twelve stroke patients. A disadvantage in regular past tense production was observed in six patients when phonological complexity was greater for regular than irregular verbs, and in three patients when phonological complexity was closely matched across regularity. These deficits were not consistently related to grammatical difficulties or phonological errors but were consistently related to lesion site. All six patients with a regular past tense disadvantage had damage to the left ventral pars opercularis (in the inferior frontal cortex), an area associated with articulatory sequencing in prior functional imaging studies. In addition, those that maintained a disadvantage for regular verbs when phonological complexity was controlled had damage to the left ventral supramarginal gyrus (in the inferior parietal lobe), an area associated with phonological short-term memory. When these frontal and parietal regions were spared in patients who had damage to subcortical ($n = 2$) or posterior temporo-parietal regions ($n = 3$), past tense production was relatively unimpaired for both regular and irregular forms. The remaining (12th) patient was impaired in producing regular past tense but was significantly less accurate when producing irregular past tense. This patient had frontal, parietal, subcortical and posterior temporo-parietal damage, but was distinguished from the other patients by damage to the left anterior temporal cortex, an area associated with semantic processing. We consider how our lesion site and behavioral observations have implications for theoretical accounts of past tense production.

© 2013 The Authors. Published by Elsevier Inc. Open access under [CC BY-NC-ND license](https://creativecommons.org/licenses/by-nc-nd/4.0/).

1. Introduction

The aim of this paper was to investigate lesion characteristics of patients who have selective difficulties producing the past tense of English verbs. In English, past-tense forms are predictable (regular: walk–walked) or idiosyncratic (irregular: teach–taught) forms. The interpretation of such data has been the subject of an enduring debate which has implications for our theoretical understanding of the structure of the language processing system. Existing approaches differ in terms of their claims about the respective roles of morpho-syntactic, lexical, phonological, and semantic processes in the

production of past-tense forms, and the relative contribution of these processes to regularity effects in aphasic past tense production. Explanations of selective past tense production impairments are developed from studies of the behavior and lesion sites of the affected patients.

According to one account of past tense production deficits, a disadvantage for regular verbs arises from a breakdown in the application of grammatical (morpho-syntactic) rules whereas a disadvantage for irregular verbs arises from a breakdown in the retrieval of whole lexical forms (Clahsen, 1999; Pinker, 1997; Pinker and Ullman, 2002; Prasada et al., 1990; Ullman, 2001a; Ullman et al., 1997). At the behavioral level, this dual-mechanism account predicts that a disadvantage for regular verbs will be associated with impairments in producing grammatical speech (agrammatism) whereas a disadvantage for irregular verbs will be associated with word-finding difficulties (anomia) (Miozzo, 2003; Ullman, 2001b; Ullman et al., 2005). However, according to an extensive review of the literature (Faroqi-Shah, 2007), there is limited evidence for this explanation of the currently reported patient data. A recent alternative to this account, which also attributes

* Corresponding author at: School of Psychology & Clinical Language Sciences, University of Reading, Reading RG6 6AL, UK. Tel.: +44 118 378 8142; fax: +44 118 975 3365.

E-mail address: l.meteyard@reading.ac.uk (L. Meteyard).

past tense production deficits to grammatical processes, argues that impairment to the morpho-syntactic system should affect both regular and irregular forms, as both have to be marked for tense during production (de Diego Balaguer et al., 2004; Faroqi-Shah and Thompson, 2004).

In contrast, a connectionist, single-mechanism account proposes that damage to the speech output system produces a disadvantage for regular verbs due to their relatively greater phonological complexity. A disadvantage for irregular verbs arises from a breakdown in the generation of divergent transformations that rely more heavily on a semantic network to overcome the pre-potent regular transformation (Daugherty and Seidenberg, 1992; Hoeffner, 1992; Joanisse and Seidenberg, 1999; McClelland and Patterson, 2002a,b; Plunkett and Marchman, n.d.; Rumelhart and McClelland, 1986; Woollams et al., 2009). From the connectionist perspective, selective difficulty with regular or irregular past tense production is expected to result from deficits in phonological or semantic processing respectively. Regular verbs are thought to place increased demands on phonological processing because regular past-tense forms tend to be more phonologically complex with more phonemes and/or offset consonant clusters than irregular forms (Bird et al., 2003; Braber et al., 2005; Lambon Ralph et al., 2005). Evidence for this perspective is also limited because there have been inconsistent reports of the degree to which selective difficulties in regular past tense production depend on phonological complexity (Bird et al., 2003) or not (Ullman et al., 2005). In addition, deficits in semantic processing have not always been found to produce selective impairments with irregular past tense production (Tyler et al., 2004) but see Patterson et al. (2006, p. 179).

In sum, whereas some accounts of past tense production focus on the importance of morpho-syntax and lexical retrieval, others focus on morpho-phonology and its interaction with semantics, although in both cases the evidence for an association between disturbances in more general language processes and specific past tense deficits has been mixed. To explore whether certain profiles of language difficulty were associated with selective impairments in past tense production in our patients, we considered: (i) lexical retrieval ability when producing the name of a single object in a picture; (ii) grammaticality of speech when describing a scene in a picture; (iii) the presence of phonological errors or dyspraxia during auditory word repetition; and (iv) semantic difficulties in auditory and written comprehension tests. The impact of phonological complexity was also assessed by considering how performance changed for a subset of regular and irregular verbs matched on this dimension.

With respect to the lesion sites associated with selective impairments in regular or irregular past tense production, the dual-mechanism account predicts that a disadvantage in producing regular verbs will be associated with damage to areas in the left inferior frontal cortex associated with syntactic processing (Grodzinsky, 2000; Pinker and Ullman, 2002; Tyler et al., 2002; Ullman et al., 2005) or procedural memory systems that subserve syntactic processes (e.g., in the basal ganglia (Ullman et al., 1997)). The same account predicts that patients with a disadvantage for irregular verbs will have lesions in temporal lobe areas associated with the retrieval of lexical representations from declarative memory (Jaeger et al., n.d.; Miozzo, 2003; Ullman, 2001b). Notably, however, the lesion sites expected on the basis of the dual-mechanism account (above) are similar to those considered to be important for the alternative connectionist account: i.e., a disadvantage for regular verbs will be associated with damage in phonological processing areas (e.g., left inferior frontal cortex) while a disadvantage for irregular verbs will be associated with damage in semantic processing areas (e.g., the left temporal lobe). It is therefore essential to consider which parts of the frontal or temporal lobes have been damaged. This requires an understanding of the functional anatomy of the language system that is emerging from functional imaging studies. For example, posterior middle temporal and temporo-parietal regions are associated

with lexical retrieval and word recognition (Binder et al., 2009; Price, 2010) which are predicted to affect the retrieval of irregular verb forms under a dual-mechanism account (Jaeger et al., n.d.; Miozzo, 2003; Ullman, 2001a). The anterior temporal lobe is more specifically involved in semantic associations (Binney et al., 2010; Visser et al., 2010) that may support the production of irregular verbs under a connectionist account (Holland and Lambon Ralph, 2010; Patterson et al., 2001). This more precise functional-anatomical perspective has been considered in the functional imaging of past tense production in healthy individuals (Desai et al., 2006; Joanisse and Seidenberg, 2005; Oh et al., 2011) but is much more challenging when applied to the lesion literature because patients with selective past tense production impairments often have extensive frontal and/or temporal lobe damage (Bird et al., 2003; Braber et al., 2005; de Diego Balaguer et al., 2004; Laiacina and Caramazza, 2004; Lambon Ralph et al., 2005; Shapiro and Caramazza, 2003; Tsapkini et al., 2002). For example, despite the importance of inferior frontal regions in both the single- and dual-mechanism accounts of the data, there is only inconsistent evidence that a disadvantage with regular past tense production is associated with left frontal lobe lesions (Faroqi-Shah, 2007).

Naturally occurring brain damage, from stroke or degenerative disease, tends to include many different functionally distinct areas, not all of which will be related to the function of interest. One way around this challenge is to search for brain regions that are consistently damaged across a population of patients with the same type of selective past tense production impairment; and then to consider whether the common lesion sites are (a) not damaged in patients without the same impairment; and (b) located in areas of the brain associated with phonological, semantic or syntactic processing in functional imaging studies of language.

There are challenges to such lesion studies that might prevent us drawing useful conclusions. For example, there would be no consistency in lesion sites if the same selective deficit were caused by damage to different areas within a larger network in different patients. Moreover, a lesion site that was consistent for patients with the same selective deficit might also be observed in patients without the same selective deficit, if the latter had recovered their ability to produce past-tense forms following functional re-organization of the language networks. Critically, however, the impact of these challenges is to increase false negative results. They would not explain observations that there were lesion sites that were (a) consistently associated with selective past tense production deficits; (b) not observed in patients who did not have impaired past tense production; and (c) located in well-known sites of activation in functional imaging studies of language.

The robustness of any conclusions regarding the relationship between lesion site and behavior depends on whether the same findings can be replicated across multiple patients. Confidence in the conclusions is proportional to the number of patients whose lesion sites and behavioral profile are in accord with the proposed interpretation. In reality, it is difficult to systematically control for the location of brain damage that naturally varies from patient to patient; and it is time-consuming to conduct extensive behavioral assessments on each patient in order to understand specific lesion-symptom associations. We took a pragmatic approach by selecting a sample of 12 patients who had aphasic speech following a left hemisphere stroke. Although lesion site was not a selection criteria, our aphasic sample had a heterogeneous assortment of damage to frontal, temporal and subcortical structures. By mapping their lesions in standard space, we were able to test hypotheses about the importance of frontal and temporal lesion sites for regular and irregular past-tense impairments. When considered alongside the functional imaging literature, we were also able to generate new hypotheses that best explained all of our behavioral and lesion site data.

2. Material and methods

2.1. Participants

Twelve patients were recruited from the PLORAS database (<http://www.ucl.ac.uk/ploras>) held at the Wellcome Trust Centre for Neuroimaging. All had existing structural MRI scans. Each received £20 for his or her time. The average age was 61 years (range 36–82), with six male and six female participants. Patients are referred to using participant identifiers from the PLORAS database so that the inclusion of the same patients in future studies can be monitored. No other data from our 12 participants has previously been reported. Table 1 provides demographic information and the stroke history for all participants.

2.1.1. Selection criteria

- More than 1 year post-stroke;
- Aphasia at time of assessment with the Comprehensive Aphasia Test (Swinburn et al., 2004), see Table 1;
- Left hemisphere cerebral vascular accident (CVA);
- Native speaker of British English with English as their first language;
- Right-handed (pre-morbidly);
- Normal or corrected-to-normal vision.

2.1.2. Lesion sites

The patients provided a representative sample with a variety of damage to the left hemisphere lesion sites of interest: three had extensive damage to *frontal*, *subcortical*, *temporal* and *parietal* areas; one had *frontal* and *parietal* damage; three had *frontal* and *subcortical* damage; three had *temporal* and *parietal* damage; and two had *subcortical* damage (see Table 1 and Fig. 1).

2.2. Stimuli and design

To ensure adequate detection of regularity effects, patients were tested using two measures of past tense production that have both been used in previous studies of past tense production in aphasia: a

sentence frame task and single word stem task. The sentence frame task differs from the single word task by including intervening material (“Yesterday, I...”) after the presentation of the verb stem. This sentence frame may facilitate past tense production in some patients by providing a syntactic context and an explicit semantic cue for tense (“Yesterday”) but the intervening words may increase processing load, particularly for those with short term phonological memory difficulties. Given the potential impact of context that might differ across patients, we therefore considered regularity effects in each task separately rather than aggregate data over the two.

In order to minimize repetition effects, different lists of items were used in the stem and sentence frame tasks. All items were monosyllabic in their present and past-tense forms. Verb item set 1 (stem task) consisted of 28 regular and 28 irregular verb stimuli from Woollams et al. (Miozzo, 2003). Verb item set 2 (sentence frame task) consisted of 27 regular and 27 irregular verbs. Fifty-three of the 55 irregular verbs in sets 1 and 2 were stem change forms. For both sets, regular and irregular verb stem forms were balanced for CELEX lemma frequency in print and spoken form, and stem and inflected forms were balanced for CELEX token frequency in print and spoken form (all $p > 0.05$). Regular and irregular verbs were balanced for the number of phonemes of the stem form. The past-tense forms of the regular items contained more phonemes than the irregular items (both $p < 0.05$), had higher present-past consistency (both $p < 0.05$) and a higher percentage of consonant clusters at offset, see Table 2 for details. Item lists are provided in Appendix 1. Randomized lists for presentation were created for the item sets, and task order and presentation list were counter-balanced across patients.

In addition, for each task, we selected a subset of regular and irregular past tense items that were matched for phonological complexity (see Table 2 for details). This allowed us to investigate whether a disadvantage with regular past tense could be explained by inherent phonological processing difficulties that increase with phonological complexity. In other words, if poorer performance on regular forms is associated with phonological impairments, this disadvantage should be reduced when items are matched on phonological variables (Braber et al., 2005).

Table 1
Summary of each patients' demographic information and language abilities.

ID	Age	Sex	TPS	Comprehensive aphasia test ^a						
				Fluency	Comprehension			Spoken output		
					Spoken	Written	Repetition	Picture description	Naming	Naming errors ^b
<i>Frontal & subcortical & temporal & parietal</i>										
PS012	60.7	M	12.2	50	46	46	48	48	47	Sem
PS198	54.4	M	15.7	66	61	60	47	54	56	Phon
PS231	61.8	F	9.9	57	57	60	56	49	59	Slow
<i>Frontal & parietal</i>										
PS062	81.4	F	9.4	53	63	63	45	58	54	Phon
<i>Frontal & subcortical</i>										
PS194	71.4	F	7.9	64	60	63	62	64	64	NAD
PS223	42.6	F	4.0	64	62	66	72	61	63	NAD
PS230	76.5	M	17.9	52	63	68	54	53	59	Phon
<i>Temporal & parietal</i>										
PS166	36.1	M	4.9	73	55	58	55	68	70	NAD
PS225	62.5	M	4.6	54	58	59	59	Not avail	59	Phon
PS248	57.0	M	3.0	60	65	63	57	53	62	NAD
<i>Subcortical only</i>										
PS082	56.1	F	2.11	62	61	76	57	59	63	NAD
PS104	82.0	F	4.10	70	59	66	58	60	70	NAD

^a T-scores (mean = 50, standard deviation = 10) standardized against a large sample of individuals with aphasia (n = 226). T-score of 60 = 68th percentile, 70 = 96th percentile. For details see Swinburn et al. (2004). TPS = time post stroke at test (years, months).

^b Sem = semantic errors; Phon = phonological errors; NAD = nil adverse detected.

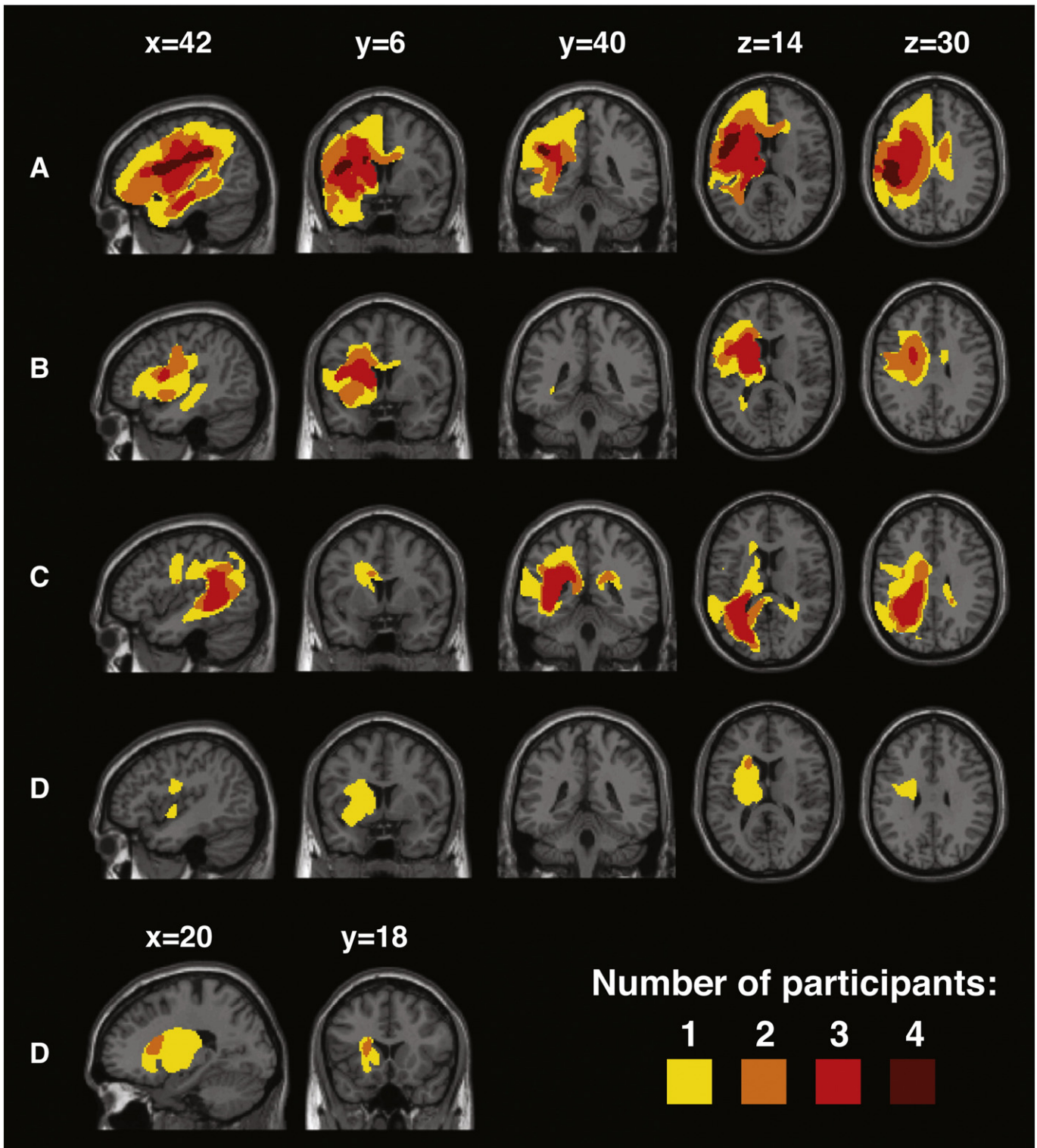


Fig. 1. Lesion overlap maps for patients grouped by lesion site and size. The color code indicates the number of patients with a lesion at every voxel across the brain. A: Patients with frontal and parietal damage (PS012, PS198, PS231, PS062). B: Patients with frontal and subcortical damage but sparing parietal cortex (PS194, PS223, PS230). C: Patients with temporal and parietal damage that spares the frontal cortex. (PS166, PS225, PS248). D: Patients with subcortical damage only (PS082, PS104), additional slices are presented to show the extent of the lesion more clearly.

As a consequence of having two sets of regular and irregular items (one set of regular and irregular for each task), and matching the items on critical phonological and lexical variables including phonological complexity, the final stimulus sets included only 15 regular and 15 irregular stimuli per task. This resulted in a total of 30 trials in each

task, with 30 regular and 30 irregular forms elicited over both tasks. Other similar and influential studies have also relied on small sample sets of 18–25 items (Holland and Lambon Ralph, 2010; Ullman et al., 2005). The small stimulus sets are unavoidable because of the distribution of items within the language, but any decline in sensitivity

Table 2
Lexical and phonological variables full & matched item sets.

	Full item set 1		Full item set 2	
	Regular	Irregular	Regular	Irregular
CELEX lemma frequency in print (stem)	3095 (4683)	3188 (4504)	2396 (4294)	2997 (2480)
CELEX lemma frequency spoken form (stem)	179 (397)	157 (320)	162 (369)	150 (160)
CELEX token frequency in print (stem)	258 (406)	250 (408)	204 (367)	228 (214)
CELEX token frequency spoken form (stem)	21 (46)	17 (39)	17 (37)	16 (19)
CELEX token frequency in print (inflected)	239 (345)	236 (288)	197 (387)	242 (240)
CELEX token frequency spoken form (inflected)	6 (9)	6 (10)	10 (28)	8 (13)
Number phonemes (stem)	3.2 (0.6)	3.6 (0.7)	3.2 (0.6)	3.5 (0.6)
Number phonemes (inflected)*	4.2 (0.6)	3.6 (0.7)	4.2 (0.7)	3.5 (0.6)
Past-present consistency*	0.98 (0.1)	0.3 (0.2)	0.8 (0.1)	0.2 (0.0)
Phonetic complexity (stem)	3.3 (1.2)	3.5 (1.1)	3.6 (1.5)	3.4 (1.5)
Phonetic complexity (inflected)**	4.2 (1.4)	3.6 (1.3)	4.7 (1.7)	3.5 (1.5)
Percentage forms with cc offsets (inflected)	82%	25%	62%	11%
	Matched item set 1		Matched item set 2	
	Regular	Irregular	Regular	Irregular
Log CELEX token frequency spoken form	1.87 (2.32)	2.13 (2.36)	4.10 (7.34)	3.73 (6.45)
Cluster at offset	11/15	6/15	5/15	3/15
Stressed phonological neighborhood	13.00 (11.76)	14.28 (13.76)	14.62 (13.32)	16.53 (13.49)
Number phonemes	4.13 (0.63)	4.07 (0.70)	4.00 (0.53)	3.80 (0.68)
Past-present consistency*	0.97 (0.06)	0.38 (0.17)	0.80 (0.13)	0.16 (0.08)
Phonetic complexity (stem)	3.33 (1.59)	4.07 (0.80)	2.87 (1.36)	3.80 (1.47)
Phonetic complexity (inflected)	4.20 (1.70)	4.33 (1.05)	4.07 (1.44)	3.93 (1.49)

* $p < 0.05$.

** $p < 0.05$ item set 2 only.

due to limited numbers of items should be countered by greater sensitivity obtained when using stimuli closely matched along a number of relevant psycholinguistic dimensions.

All stimulus items were produced by a male native speaker of Southern British English. The waveform was edited at zero crossings to begin at onset and end at offset, and was saved in its own mono audio file in WAV format. For sentence elicitation, a short period of silence (50 ms) was added to the end of the “Every day I...” and the beginning of the “Yesterday I...” sound file, to make the sentence sound more natural when played alongside the target stem.

2.3. Procedure

Patients gave full informed consent in line with the Declaration of Helsinki (Anon., 1991) via aphasia-friendly information and consent forms on the day of testing. The study was approved by the Ethics Committees at Birkbeck College and University College London. The experiment was conducted on a Macintosh PowerPC G4 eMac computer using SuperLab software. All auditory stimuli were presented through Sennheiser HD 25-1 headphones in an Industrial Acoustics Corporation 403-A audiometric chamber. An Olympus WS 650S digital voice recorder was used to record their spoken output.

2.3.1. Single word task

Verb item set 1 was used. There were six practice and 56 experimental trials (28 regular and 28 irregular). Participants were given verbal and written instructions (Arial, black, font size 24): “You will hear a single word that is a verb, e.g., ‘Walk’. Please say this verb out loud, in the PAST TENSE: ‘walked.’” Another example (with the irregular verb ‘Write’-‘Wrote’) was provided verbally by the experimenter. A picture of a reverse arrow was displayed at the end of each trial, as a visual prompt to generate the past-tense form. Practice trials were terminated once the patient was comfortable with the task. During each trial, a fixation cross appeared on the screen for 1500 ms, followed by a blank screen for an inter-stimulus interval (ISI) of 500 ms. The stem was then played binaurally over headphones, followed immediately by the reverse arrow prompt. If the patient requested it, the experimenter repeated the verb stem. There was no

time limit for a response and the patient pressed any button to continue.

2.3.2. Sentence elicitation task

Verb item set 2 was used. There were six practice trials and 54 experimental trials (27 regular and 27 irregular). The procedure was the same as for the single word task except that sentence frame cues were presented. Participants received the following written and verbal instructions: “You will hear a sentence like ‘Every day I walk, yesterday I...’. Please complete the sentence by saying the verb out loud, in the PAST TENSE. Every day I walk, yesterday I: ‘walked’”. A verbal example was provided with the irregular verb ‘Write’-‘Wrote’. During each trial, a fixation cross appeared on the screen for 1500 ms, followed by a blank screen for an ISI of 500 ms. The frame “Every day I...” was then played, followed by the target stem, and the final frame section “Yesterday I...,” followed immediately by the reverse arrow prompt.

2.4. Scoring of production data

A stringent criterion was adopted so that only the first attempt was scored and categorized as correct or incorrect, based on Ullman et al. (McClelland and Patterson, 2002b). Trials on which patients did not provide a response (accidentally or volitionally) were subtracted from the total trial count, hence errors considered here were only those of commission (in contrast to some previous studies).

2.4.1. Error classification

Production errors can be informative about the underlying causes of deficits. Production errors were classified using a system based on Ullman et al. (McClelland and Patterson, 2002b), with the following categories: *no inflection* (e.g., draw–draw); *analogical inflection* (regular past-tense suffix on an irregular stem, e.g., seek–seeked, or irregular stem change on a regular form, e.g., sneeze–snoze); *other incorrect inflection* (s/ing/en suffix; e.g., shake–shakes/shaking/shaken); *morphological–phonological error* (phonologically related stem, with other incorrect inflection; e.g., fill–feeling); *morphological–semantic error* (semantically related stem, with other incorrect inflection; e.g., carve–sculpts); *phonologically*

related stem with correct past-tense inflection (e.g., leak–licked); other phonological error (nonword distortion, e.g., cook–“stirt”), unmarked phonologically related substitution, (e.g., cut–cat); *semantically related stem with correct past-tense inflection* (e.g., tie–laced); and *other semantic error* (semantic substitution unmarked/semantically related word non-verb; e.g., tie–knot). As some errors were relatively infrequent, we collapsed categories for ease of exposition: morphological–phonological, phonologically related stem with correct past-tense inflection, and other phonological errors were combined to yield an overall phonological error score; and morphological–semantic error, semantically related stem with correct past-tense inflection, and other semantic errors were combined to yield an overall semantic error score.

2.5. Language profiles

The language performance of all patients was assessed using the Comprehensive Aphasia Test (CAT (Swinburn et al., 2004)), see Table 1. To determine the lexical, semantic and syntactic abilities of our patients, we focused on performance on four tasks. Lexical retrieval was assessed by comparing performance on the picture naming task to the auditory repetition task; grammatical (syntactic) production was assessed by comparing performance on the picture description task to the picture naming task; lexico-semantic processing was assessed with picture–word matching; and phonological processing was assessed by considering the types of errors produced during picture naming.

2.6. Lesion analysis

2.6.1. MRI data acquisition

For all patients, a T1 weighted anatomical whole brain image was acquired with a Siemens 1.5 T Sonata MRI scanner (Siemens Medical Systems, Erlangen, Germany). A T1 weighted 3D modified driven equilibrium Fourier transform sequence was used to acquire 176 sagittal slices with an image matrix of 256×224 yielding a final resolution of 1 mm^3 : repetition time/echo time/inversion time, 12.24/3.56/530 ms (Deichmann et al., 2004).

2.6.2. Lesion identification in each individual patient

Structural images were pre-processed with Statistical Parametric Mapping software (SPM5: Wellcome Trust Centre for Neuroimaging: <http://www.fil.ion.ucl.ac.uk/spm>) running under MATLAB (MathWorks, Natick, MA, USA). The images were spatially normalized into standard Montreal Neurological Institute (MNI) space using a unified segmentation algorithm optimized for use in patients with focal brain lesions (Ashburner and Friston, 2005).

The unified segmentation algorithm is a generative model that combines tissue segmentation, bias correction and spatial normalization in the inversion of a single unified model (Seghier et al., 2008). We used a modified version of the tissue segmentation component that has been developed to further improve identification and spatial normalization of “brain” as opposed to “nonbrain” components in lesioned brains. It works by adding in an extra tissue class, “lesion”, into which outlier voxels can be classified (Seghier et al., 2008).

The resulting gray and white matter images were smoothed with an isotropic kernel of 8 mm at full width half maximum to increase the chance that regional effects are expressed at a spatial scale in which homologies in structural anatomy are shared over subjects. After smoothing, the value in each voxel represents the probability that the tissue belongs to the gray or white matter class and is not non-brain or lesion. The lesion of each patient was automatically identified using an outlier detection algorithm based on fuzzy clustering (Seghier et al., 2007) with default parameter settings (see procedure in Seghier et al., 2008). An outlier image was thus generated that coded the degree of abnormality of each voxel (i.e. how far the value at a given voxel is from the normal range of 64 healthy controls) as a continuous measure

varying from 0 for an intact voxel to 1 for a completely damaged voxel. We refer to these images as fuzzy lesion images (the word “fuzzy” is borrowed from the fuzzy clustering algorithm cited above). The advantages of using the fuzzy lesion images rather than gray or white matter images is that the fuzzy lesions combine gray and white matter into one image; and reduce error variance in the estimation of abnormality because they are based on a prior comparison to 64 healthy controls (see Seghier et al., 2008).

Each fuzzy lesion image was then thresholded to create a single binary image of gray and white matter tissue loss (i.e. the lesion site) in standard MNI space. All images were generated in MNI space to allow for group analyses and to enable us to compare lesion locations to functional imaging activations of healthy individuals. Binary images were used to generate lesion overlap maps (in SPM) by summing binary images across patients (Frank et al., 1997). The lesion overlap maps therefore indicate the number of patients who have a lesion at each voxel across the entire brain.

2.6.3. All and none lesion sites

To find lesion sites that were uniquely associated with one patient group relative to another (i.e., damaged in all patients with the symptom of interest and not damaged in any other patient), we summed the binary images from all the patients of interest, subtracted the binary images of all other patients, and thresholded the resulting map at the number of patients included in the group of interest.

3. Results

3.1. Selective impairments with regular or irregular past tense production

On the full item set, six out of 12 patients made significantly more errors in the production of regular past-tense forms than irregular forms in the single word and/or sentence frame tasks. One patient was severely impaired on both regular and irregular forms, but made significantly more errors in the production of irregular past tense; see Table 3a. The remaining five patients made relatively few errors producing regular or irregular past tense (a maximum of six errors on sentence trials and five errors on the single word task), and showed no significant regularity effects; see Table 3a.

On the subset of regular and irregular trials that were matched for phonological complexity, the regularity effect was reduced in all six patients and no longer reached significance for either task in three of the six patients (see Table 3b). Although the reduced significance could be a consequence of the reduced stimulus set when phonological complexity was controlled, the disadvantage for regular past tense remained significant in three patients (PS062, PS198, PS231) during the sentence frame task. This finding suggests that phonological complexity differences cannot fully explain regular past tense difficulties.

Finally, we note that the enhanced regularity effect during the sentence frame task (see PS062, PS198, PS231 in Table 3B) arose because, compared to the single word stem task, the sentence frame task facilitated past tense production for irregular words (4, 6 and 5 points) more than regular words (2, 1 and 2). The semantic and syntactic cues provided by the sentence frame task therefore appeared to be more facilitatory for irregular than regular forms, at least in these three patients.

3.2. Error classification

Our seven patients with regular past tense difficulties made a high proportion of *no inflection* errors, i.e., only producing the bare stem (“walk” rather than “walked”) and these were more common for regular than irregular verbs. They also produced more progressive “ing” inflections. This is the next most frequent inflection after “ed” (see Table 1 in Faroqi-Shah and Thompson, 2007), it has a simpler CV structure, and its articulatory features are not determined by the stem

Table 3
Accuracy of regular and irregular past-tense production full item set.

A) Full item set							
Patient (arranged by performance pattern)		Task					
		Sentence frame			Single word		
		Reg	Irreg	z-Score	Reg	Irreg	z-Score
<i>Irregulars > regulars</i>							
Frontal & parietal	PS062	7/25	20/27	−3.29**	4/28	12/28	−2.34*
Extensive damage	PS198	2/26	17/27	−4.16**	1/28	6/27	−2.06*
Extensive damage	PS231	3/22	16/26	−3.50**	1/28	11/28	−3.23**
Frontal & subcortical	PS194	12/27	21/27	−2.49*	18/28	24/28	−1.84
Frontal & subcortical	PS223	17/27	21/27	−1.18	3/28	22/28	−5.06**
Frontal & subcortical	PS230	14/21	21/23	−2.20*	13/27	17/28	−1.06
<i>Regulars > irregulars</i>							
Extensive damage	PS012	9/26	1/24	−2.66*	2/26	0/26	−1.43
<i>No difference</i>							
Temporo-parietal	PS166	26/27	25/27	−0.59	28/28	26/28	−1.43
Temporo-parietal	PS225	24/27	21/27	−1.09	27/28	23/28	−1.71
Temporo-parietal	PS248	25/27	22/27	−1.20	28/28	26/28	−1.43
Subcortical	PS082	23/26	23/27	−0.35	27/28	26/28	−0.59
Subcortical	PS104	21/25	26/27	−1.49	24/28	25/28	−0.40
B) Matched item set							
Patient (arranged by performance pattern for full item set)		Task					
		Sentence frame			Single word		
		Reg	Irreg	z-Score	Reg	Irreg	z-Score
<i>Irregulars > regulars</i>							
Frontal & parietal	PS062	4/15	11/15	−2.51*	2/15	7/15	−1.959
Extensive damage	PS198	1/15	10/15	−3.35**	0/15	4/14	−2.191
Extensive damage	PS231	2/15	10/15	−2.93*	0/15	5/15	−2.408
Frontal & subcortical	PS194	8/15	12/15	−1.52	8/15	12/15	−1.523
Frontal & subcortical	PS223	12/15	11/15	−0.42	3/15	9/15	−2.198
Frontal & subcortical	PS230	7/15	10/14	−1.33	6/15	9/15	−1.077
<i>Regulars > irregulars</i>							
Extensive damage	PS012	4/14	0/14	−2.12	1/14	0/14	−1.00
<i>No difference</i>							
Temporo-parietal	PS166	15/15	14/15	−1.00	15/15	13/15	−1.439
Temporo-parietal	PS225	13/15	14/15	−0.60	14/15	12/15	−1.056
Temporo-parietal	PS248	13/15	15/15	−1.44	15/15	14/15	−1.00
Subcortical	PS082	13/15	13/15	0.00	14/15	14/15	0.00
Subcortical	PS104	12/14	15/15	−1.49	12/15	12/15	0.00

* $p < 0.05$ and ** $p < 0.005$ for the comparison of the number of correct items on regular and irregular trials using Mann–Whitney U tests. Trials on which patients did not provide a response (accidentally or volitionally) were subtracted from the total trial count.

rime. Both the “no inflection” and “ing” inflections therefore indicate a tendency to simplify phonologically complex items. A summary of the results of the error analysis can be found in Table 4A and 4B.

3.3. Language profiles

The ability to produce regular past-tense forms (Table 3) was not consistently associated with measurements of lexical retrieval, grammatical speech or phonological processing (see Table 1). None of the patients had selective difficulties with lexical retrieval (more difficulty with picture naming than auditory repetition). Three patients had difficulty producing grammatical content in the context of relatively good picture naming (PS231; PS230; PS248), four patients made phonological errors during picture naming and four patients (PS012, PS166, PS225, PS248) had aphasic scores on the digit span test (administered as part of the CAT) indicating difficulties with phonological short term memory. Critically, grammatical, phonological and digit span scores did not predict the ability to produce past-tense forms.

The most relevant finding was that the patient who had more difficulty with irregular past tense than regular past tense (PS012) was the only patient who was severely impaired on lexico-semantic word–picture matching tasks and semantic matching of pictures in the absence of word processing (t-score = 51 in PS012 and 60 in all other patients). PS012 was also the only patient to make semantic errors during picture naming (e.g. “pear” in response to a picture of a pineapple; “fish” for frog; “fence” for gate).

3.4. All and none lesion sites associated with regularity effects

Three patients who had selective difficulty with regular past-tense production in the full set of items, but not when phonological complexity was controlled, had damage to the left ventral pars opercularis (vPOp). Three patients who had selective difficulty with regular past-tense production in the full set of items and when phonological complexity was controlled had frontal damage to the same left vPOp area but were distinguished by additional damage that extended back into the left ventral supramarginal gyrus (vSMG) (see Fig. 2). None of the five patients with preserved past-tense production performance had damage to either vPOp or vSMG. Finally, the patient who had semantic processing difficulties and severe difficulty producing both regular and irregular past tense (which was significantly worse for irregular when the stimulus items were not matched for phonological complexity) had very extensive damage that included both vPOp and vSMG but also extended into a left anterior temporal lobe (ATL) area that was not damaged in any of the other 11 patients (see Fig. 2). In MNI space, vPOp damage was located around [x, y, z: −42, 8, 16], vSMG damage was located around [x, y, z: −50, −30, 30] and ATL damage was located around [x, y, z = −40, +12, −30].

4. Discussion

In this study of 12 patients who had suffered left hemisphere strokes more than two years previously, we identified seven patients who had difficulty producing past tense and five patients with relatively spared past tense production. In six of the seven impaired patients, the past tense production difficulty was more pronounced for regular (walk–walked) than irregular (teach–taught) forms. The seventh patient had the reverse dissociation, i.e. a relative disadvantage for irregular past tense forms. To investigate the cause of these dissociations, we examined each patient’s language performance and lesion site. At the behavioral level, we looked for evidence that: (1) a disadvantage for regular verbs was associated with impaired grammatical or phonological processing; (2) a disadvantage for irregular verbs was associated with impaired lexical retrieval or semantic processing; and (3) a general morpho-syntactic deficit could explain deficits in both regular and irregular past tense. At the lesion level, we looked for sites of damage that were associated with a disadvantage for regular or irregular verbs before and after phonological complexity was controlled, and we considered the aspects of language processing that we would expect to be impaired following each type of lesion, based on prior functional imaging studies in healthy participants.

The behavioral profile revealed no clear evidence that a disadvantage for regular past tense production was consistently related to grammatical difficulties (the dual-mechanism account (Miozzo, 2003; Ullman, 2001b; Ullman et al., 2005)) or to phonological processing difficulty (the connectionist account (Daugherty and Seidenberg, 1992; Hoeffner, 1992; Joanisse and Seidenberg, 1999; McClelland and Patterson, 2002a,b; Plunkett and Marchman, n.d.; Rumelhart and McClelland, 1986; Woollams et al., 2009)). The lesion analysis, in contrast, produced several new conclusions. First, we localized the lesion site that was most consistently associated with difficulties producing regular past tense to the left ventral pars opercularis (vPOp), which is part of Broca’s area in the left posterior inferior frontal

Table 4A

Raw error counts by sentence and stem regular and irregular production tasks.

	Sentence elicitation task												Stem elicitation task											
	PS	None		Anl		Other		Ph.		Sem.			None		Anl		Other		Ph.		Sem.			
		R	I	R	I	R	I	R	I	R	I	T	R	I	R	I	R	I	R	I	R	I	T	
<i>Irregular > regular</i>																								
F&P	062	13	5	1	1	2	0	2	1	0	0	25	5	3	0	0	16	11	3	2	0	0	40	
Ext	198	10	5	5	2	2	1	7	2	0	0	34	15	9	0	0	12	12	0	0	0	0	48	
Ext	231	11	3	0	0	5	2	2	3	0	1	27	11	9	0	0	15	7	1	1	0	0	44	
F&S	194	2	1	3	0	4	2	6	3	0	0	21	4	1	0	3	1	0	4	0	0	0	13	
F&S	223	6	2	2	1	0	0	2	3	0	0	16	23	6	0	0	0	0	1	0	1	0	31	
F&S	230	5	2	0	0	0	0	2	0	0	0	9	9	6	0	0	5	3	0	1	0	1	25	
<i>Regular > irregular</i>																								
Ext	012	4	6	0	8	4	5	8	2	0	0	37	10	9	0	0	11	16	2	1	0	0	49	
<i>No difference</i>																								
T&P	166	1	0	0	1	0	0	0	0	0	0	2	0	2	0	0	0	0	0	0	0	0	2	
T&P	225	2	2	0	2	0	0	1	2	0	0	9	0	2	0	1	0	0	0	3	0	0	6	
T&P	248	2	1	0	3	0	0	0	1	0	0	7	0	1	0	1	0	0	0	0	0	0	2	
S	082	1	2	0	2	1	0	1	0	0	0	7	0	2	0	0	0	0	1	0	0	0	3	
S	104	0	0	0	1	0	0	3	0	1	0	5	0	0	1	0	1	2	1	1	0	1	7	

Key to abbreviations: PS = patient identification number, R = regular verb forms, I = irregular verb forms, T = total errors (sum) for that task, Ext = extensive lesion, F&S = frontal and subcortical lesion, T&P = temporo-parietal lesion, S = subcortical lesion, None = no inflection error, Anl = analogical inflection error, Other = other inflection error, Ph. = phonological error, Sem. = semantic error.

cortex. Specifically, we found that all seven patients who had difficulty producing regular past tense had damage to left vPOp; and all patients with left vPOp damage had difficulty producing regular past tense. Three of the patients with left vPOp lesions and regular past tense production difficulties also had left subcortical damage (PS194; PS223; PS230) but two other patients with left subcortical damage that spared left vPOp did not have past tense production difficulties (i.e. PS082 and PS104). We therefore propose that the impact of subcortical damage on regular past tense production may depend on whether left vPOp and its underlying connections are damaged or spared.

Second, we found that the severity of the disadvantage with regular past tense depended on the extent of the lesion. In three patients who had damage that extended posteriorly into the ventral part of the left supramarginal gyrus (henceforth vSMG which is in the left inferior parietal cortex), the disadvantage with regular past tense remained significant during the sentence frame task, even when phonological complexity was matched for regular and irregular items. In contrast, in the remaining three patients who did not have damage to left vSMG, the regular past tense disadvantage did not reach significance when phonological complexity was controlled. This result contradicts previous claims that a disadvantage for regular past tense forms in aphasic speech production can be explained by phonological complexity differences (Bird et al., 2003; Oh et al., 2011). Inter-study differences might have been the consequence of the stimulus sets used. However, the distinction we found between those who did and did not have a significant regular past tense disadvantage when phonological complexity was controlled led us to discover consistent

differences in lesion sites (left vPOp & vSMG versus left vPOp but not vSMG). In other words, the lesion results validated the distinction found in the behavioral results. We therefore tentatively suggest that prior reports showing that a disadvantage in regular past tense production is not observed when phonological complexity is controlled (Bird et al., 2003; Oh et al., 2011) may have been observed in patients whose lesions spared left vSMG, left vPOp or both. Thus, we are claiming that it is the combination of damage to both left vPOp and left vSMG that impairs regular past tense more than irregular past tense when phonological complexity is controlled.

Our third finding was that, although left vPOp and vSMG damage consistently impaired regular past tense production in our sample of patients, damage to these regions did not always result in a disadvantage for regular past tense forms relative to irregular forms. To the contrary, one of the seven patients with left vPOp damage (PS012) had more difficulty producing irregular than regular past tense. This was observed in the context of a very extensive lesion that included left temporal lobe areas that were not damaged in the six patients who had greater difficulty producing regular than irregular past tense forms. The effect of left vPOp and left vSMG damage could therefore be associated with a disadvantage for irregular past tense forms (in PS012) or a disadvantage for regular past tense forms (in PS062, PS198, PS231). The determining factor appears to be the presence or absence of concurrent damage to anterior and/or posterior temporal lobe regions.

A fourth finding was that damage to the posterior temporal lobe was not sufficient to cause a disadvantage for irregular past tense production, as our sample included three patients with left posterior temporal damage who had unimpaired past tense production (PS166, PS225, PS248). Nevertheless, as the left posterior temporal region was one of the many areas damaged in PS012, who had the most profound difficulty with irregular past tense production, we cannot exclude the possibility that left posterior temporal lobe damage contributes to difficulties producing irregular past tense, in combination with damage to other areas (e.g. left anterior temporal, vPOp, vSMG).

In summary, our findings are consistent with prior reports of regular past tense production difficulties after left inferior frontal (Grodzinsky, 2000; Ullman, 2001a) and subcortical (Ullman et al., 1997) damage, but, in our sample, we localize the critical lesion site to left vPOp, irrespective of the involvement of subcortical damage. We also note that the pervasiveness of the effect depends on whether left vSMG is

Table 4B

Other inflection errors by task.

Other inflection	Task	
	Sentence Frame	Single Word
ing/progressive	14	76
en/past participle	0	8
s/present	8	0
er/est/stressed schwa ^a	6	28
Total	30	112

^a Syllabic schwa: one participant (PS012) frequently produced forms such as 'walk-a', inserting a stressed schwa at the end of verb stems.

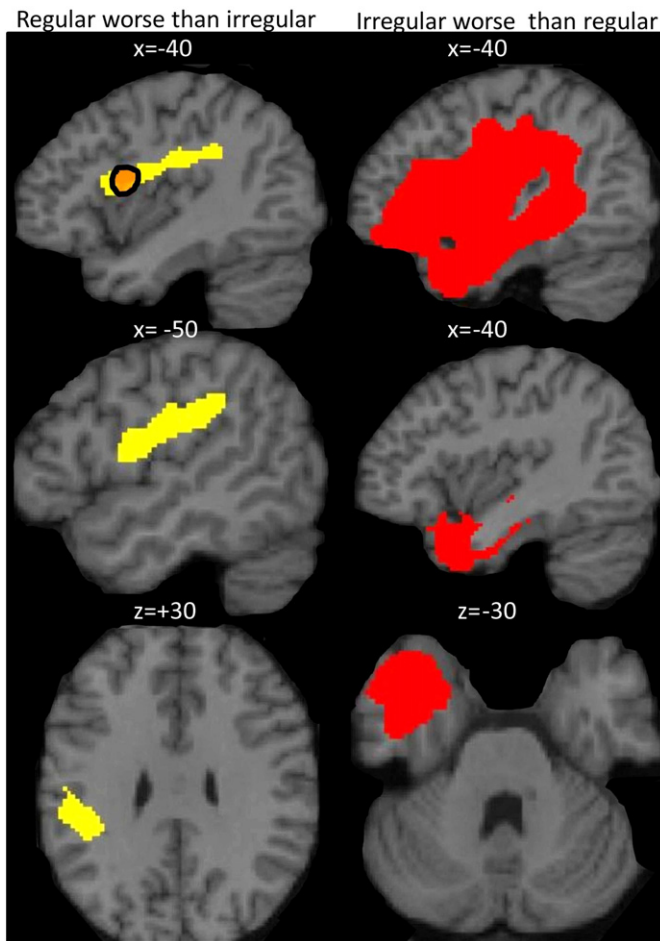


Fig. 2. Lesion sites consistently observed in patients with more difficulty producing regular or irregular past tense. Yellow (left top, middle, and bottom) shows areas consistently damaged in the 3 patients (PS198, PS231, PS062) who were less accurate in producing regular than irregular past tense, even when phonological complexity was controlled. Orange (top left) shows frontal operculum area that was damaged in all 6 patients who were less accurate for regular than irregular verbs when phonological complexity was not controlled. Red (top right) shows the extent of the damage in the only patient (PS012) who had more difficulty with irregular than regular past tense. The images below (middle right and lower right) show the part of this lesion that was not damaged in any of the other 11 patients.

concurrently damaged or not, and we suggest that the relative difficulty with regular versus irregular past tense depends on the presence or absence of anterior and/or posterior temporal lobe damage. Although further studies are required to test these hypotheses, all of our findings converge to reinforce the conclusion that selective difficulties in past tense production cannot be attributed to a specific, unique lesion site associated with the production of regular or irregular past tense forms, respectively. Instead, regularity effects in past tense production appear to arise from damage to a combination of regions (Friston and Price, 2011; Price et al., 2010).

By examining our patients' lesions in standard MNI space, we can now consider the type of language processing associated with left vPOp and left vSMG in functional imaging studies of healthy individuals, and then assess how the type of processing identified contributes to past tense production. A role for the left vPOp in syntactic processing has been reported during the comprehension of grammatically correct sentences with implausible meanings (Obleser and Kotz, 2010), semantically unexpected completions (Indefrey et al., 1997), or non-canonical word order (i.e., nested subject relative structures) (Makuuchi et al., 2009). In this context, one might argue that past tense production difficulties after lesions to left vPOp might

be the consequence of a morpho-syntactic processing impairment. However, this would not explain why left vPOp damage did not result in a disadvantage with regular past tense when (a) phonological complexity was controlled and (b) vSMG was not damaged. An alternative explanation is that left vPOp supports the segmentation and sequencing of individual phonological elements and the generation of an articulatory plan based on a predictable phonological transformation (Price, 2010). According to this proposal, activation during difficult sentence comprehension (Indefrey et al., 1997; Makuuchi et al., 2009; Obleser and Kotz, 2010) is the consequence of phonological processing because left vPOp activation is observed during phoneme monitoring (Démonet et al., 1992), syllable monitoring (Poldrack et al., 1999), initial phoneme discrimination in non-rhyming words (Burton et al., 2000), phonological similarity judgments based on pictures of objects (Katzir et al., 2005), phonological verbal fluency (Heim et al., 2009), articulatory planning of low-predictability phonological sequences (Papoutsi et al., 2009) and syllabification in speech production (Poldrack et al., 1999), a process characterized as “the building of syllables out of phonemes as a preparation for subsequent articulation” [p.9, 58].

The association of left vPOp with segmentation and sequencing of individual phonological elements and the generation of an articulatory plan based on a predictable phonological transformation are consistent with the type of processing required for producing regular past-tense forms. The sequencing of a verb stem and its inflection (e.g., “walk” and “-ed”) results in predictable variations in the resulting articulatory sequence depending upon the phonological features of the stem rime (devoicing following voiceless segments, resyllabification following alveolar segments). This is in contrast to irregular past tense production, which requires the generation of an unsegmented word (“teach”–“taught”), placing fewer demands on sequencing. Evidence of articulatory sequencing difficulties is apparent in the high proportion of “no inflection” errors that our patients made when producing past-tense forms, which have been argued to reflect articulatory difficulties rather than a more general phonological impairment (Romani and Galluzzi, 2005).

The reduction in the regularity effect when phonological complexity was controlled can be explained in terms of the articulatory sequencing demands being better matched during regular and irregular past tense production. The regularity effect was not, however, completely eliminated when phonological complexity was controlled, particularly in the three patients who had damage that extended from left vPOp into left vSMG. An articulatory sequencing deficit does not therefore provide a sufficient explanation of the persistent deficit in these patients. The extended lesion site in these patients cut through the pre- and post-central gyri in addition to damaging vPOp and vSMG. These areas are associated with generating, maintaining or monitoring sublexical speech (Buchsbaum and D'Esposito, 2008; Kirschen et al., 2010; Paulesu et al., 1993) and the reciprocal connections between PM/vPOp and SMG may form a resonance circuit for temporarily storing representations of internally generated speech (Buchsbaum et al., 2011; Hickok and Poeppel, 2007; Romero et al., 2006). From CAT scores, patient's immediate recall of digit strings was not significantly impaired relative to other aphasic individuals (the group against which CAT scores are standardized), but this does not rule out impaired digit span relative to healthy adults. Digit span may also be less sensitive to the processes of interest, since generation of a different phonological form in response to the stem will introduce greater demands on both maintenance and articulation than straight repetition. We hypothesize that these patients have a phonological short-term memory deficit affecting the maintenance of internally generated speech in addition to a deficit in articulatory sequencing. Such a memory deficit might affect regular more than irregular past tense production if regular verb stems and their inflections (e.g., “walk” and “-ed”) are generated independently prior to being combined when the stem form itself is presented as the stimulus (Woollams et al., 2009). In contrast, irregular past tense forms involve the production of a less componential

phonological form (“taught”). The precise nature of the short-term memory deficit and its relationship to simple memory span performance and morphological production warrants further investigation.

The effect of task on past tense production scores also provides evidence of the type of processing that influences the disadvantage for regular verb forms. The sentence frame task differs from the single word task because it provides syntactic and semantic cues. A facilitatory effect of the sentence frame cue on past tense production was observed in all our patients, except for PS194 whose accuracy was the same in both tasks. In the three patients whose disadvantage with regular words persisted even when phonological complexity was controlled, the facilitation from the sentence frame was greater for irregular words than regular words. For these three patients, semantic and/or syntactic cues were therefore more beneficial for irregular past tense production, consistent with the greater semantic priming observed for irregular than regular verbs in normal inflection (Butler et al., 2012). Regular past tense production may have benefitted less from semantic and/or syntactic cues if both the task (sentence frame) and the stimulus type (regular inflections) imposed greater demands on memory resources. The sentence frame task increases memory demands by presenting intervening material (“Yesterday, I...”) after the verb stem and this may disproportionately affect regular past tense production, for which the short term maintenance of multiple phonological elements is already disrupted in the context of lesions to left vSMG.

Additional research is now needed to establish whether regular past tense difficulties that arise from damage to the left ventral pars opercularis disrupt articulatory sequencing of phonological elements in the absence of grammatical inflection, particularly when novel sequences are not supported by existing semantic knowledge; for example, when the task requires blending or segmenting as opposed to the generation of whole forms. Such tasks are typically used in tests of phonological awareness and require the addition or elision of individual phonological elements, e.g., “add [s] to “lip”” or “say “slip” without the [s]” (Crisp and Lambon Ralph, 2006; Patterson and Marcel, 1992; Wagner et al., 1993).

The unique behavioral and lesion characteristics of PS012 also offer several motivations for further study. This patient was only able to produce irregular past tense in response to 1/55 stimuli. Her regular past tense production was also severely impaired (11/55) and her relative disadvantage with irregular past tense did not reach significance when phonological complexity was controlled. Without further studies that systematically investigate the influence of different lesion sites on past tense production, we cannot exclude the possibility that PS012’s very extensive lesion site resulted in damage to an area (e.g., left anterior temporal lobe) or combination of areas (e.g., left anterior temporal lobe and left vPop) that is critical for the morpho-syntactic processing that underlies the generation of both regular and irregular past tense. An alternative interpretation is that different lesion sites contributed to PS012’s regular and irregular past tense production difficulties. For example, damage to left vPop and left vSMG could explain the difficulty with regular past tense (see conclusion 1 above), while damage to the left anterior temporal lobe that was not observed in any other patient could explain PS012’s inability to produce irregular past tense forms. The association of left anterior temporal lobe damage with irregular past tense production difficulties is consistent with other studies [e.g. 24, 31]. The association of the left anterior temporal lobe with semantic processing (Visser et al., 2010) also offers support to theoretical accounts that explain irregular past tense production difficulties in terms of impaired semantic processing (Daugherty and Seidenberg, 1992; Hoeffner, 1992; Joanisse and Seidenberg, 1999; McClelland and Patterson, 2002a,b; Plunkett and Marchman, n.d.; Rumelhart and McClelland, 1986; Woollams et al., 2009). Indeed, PS012 was the only patient to make semantic errors in her picture naming responses and to have impaired written and spoken word comprehension. However, we cannot conclude with

confidence that left anterior temporal lobe damage produced PS012’s semantic processing deficit, or that the semantic processing deficit impaired irregular past tense production. For example, PS012’s semantic processing and irregular past tense production difficulties could have been caused by different lesion sites, and these critical lesion sites might involve a combination of damage to several different areas.

Finally, with respect to the implications of our study for theoretical models of past tense production, we note that, despite our initial intentions, our results do not allow us to cleanly adjudicate between dual-mechanism and connectionist accounts of past tense production. In line with the predictions of connectionist models (Joanisse and Seidenberg, 1999), we observed patients whose disadvantage in producing regular compared to irregular past tense forms was driven by phonological complexity. However, we also observed patients whose disadvantage in producing regular forms was retained even when phonological complexity was controlled. This latter result suggests that damage to other cognitive processes in addition to phonological output can produce a disadvantage for regular verbs. While it may be argued that patients showing a disadvantage for regular verbs irrespective of phonological complexity supports dual-mechanism accounts, the lesion analyses provided no support for the proposal that this was associated with the inferior frontal gyrus and/or sub-cortical structures (Ullman et al., 1997). Hence the use of lesion mapping revealed novel and unexpected findings that have implications for both types of theoretical account. We found that the distinction between the two patient subgroups is supported by the presence or absence, respectively, of left vSMG damage, in addition to the left vPop damage that was common to all six patients. By localizing the lesion sites in MNI space, we are also able to use prior functional imaging findings to speculate on the level of processing that is affected by different lesion sites. For example, on the basis of lesion sites, we suggest that patients with regular past tense production difficulties are likely to have impairments in sequencing sublexical representations (e.g., stems and inflections) and that patients whose impairments persist when phonological complexity is controlled may have additional impairments at the level of phonological short term memory. Such findings have implications for future theoretical accounts and studies of past tense production.

5. Conclusion

We propose that a persistent disadvantage for regular verb production observed in a subset of our patients can be explained by damage to the left ventral pars opercularis extending back into the left ventral supramarginal gyrus. We have interpreted the data by considering morpho-phonological processes (the focus of single-mechanism accounts) and morpho-syntactic processes (the focus of dual-mechanism accounts) associated with the damaged regions, and the behavioral profiles of the patients. The lesion data suggest that a deficit for regular verbs arises from combined damage to regions associated with morpho-phonological processing and phonological short term memory. This proposal may ultimately provide more explanatory power to current theoretical accounts of past tense production, and highlights the necessity of taking into account the complex pattern of brain injury that best explains selective difficulties with regular or irregular past tense production.

Acknowledgments

This work was funded by the Wellcome Trust and the James S. McDonnell Foundation (conducted as part of the Brain Network Recovery Group initiative). Additional funds were provided by the Department of Psychological Sciences, Birkbeck College, University of London. We would like to thank all the patients for giving up their time to take part. We would also like to thank Sue Ramsden, Susan

Prejawa and Louise Ambridge with their help in analyzing the patient data, and Matthew Whalley for help in creating the figures.

Appendix A. Supplementary data

Supplementary data to this article can be found online at <http://dx.doi.org/10.1016/j.nicl.2013.10.005>.

References

- Anon., 1991. Declaration of Helsinki. *BMJ* 302, 1194.
- Ashburner, J., Friston, K.J., 2005. Unified segmentation. *Neuroimage* 26, 839–851.
- Binder, J.R., Desai, R.H., Graves, W.W., Conant, L.L., 2009. Where is the semantic system? A critical review and meta-analysis of 120 functional neuroimaging studies. *Cereb. Cortex* 19, 2767–2796.
- Binney, R.J., Embleton, K.V., Jefferies, E., Parker, G.J.M., Ralph, M.A.L., 2010. The ventral and inferolateral aspects of the anterior temporal lobe are crucial in semantic memory: evidence from a novel direct comparison of distortion-corrected fMRI, rTMS, and semantic dementia. *Cereb. Cortex* 20, 2728–2738.
- Bird, H., Lambon Ralph, M.A., Seidenberg, M.S., McClelland, J.L., Patterson, K., 2003. Deficits in phonology and past-tense morphology: what's the connection? *J. Mem. Lang.* 48, 502–526.
- Braber, N., Patterson, K., Ellis, K., Lambon Ralph, M.A., 2005. The relationship between phonological and morphological deficits in Broca's aphasia: further evidence from errors in verb inflection. *Brain Lang.* 92, 278–287.
- Buchsbaum, B.R., D'Esposito, M., 2008. The search for the phonological store: from loop to convolution. *J. Cogn. Neurosci.* 20, 762–778.
- Buchsbaum, B.R., Baldo, J., Okada, K., Berman, K.F., Dronkers, N., D'Esposito, M., et al., 2011. Conduction aphasia, sensory-motor integration, and phonological short-term memory – an aggregate analysis of lesion and fMRI data. *Brain Lang.* 119, 119–128.
- Burton, M.W., Small, S.L., Blumstein, S.E., 2000. The role of segmentation in phonological processing: an fMRI investigation. *J. Cogn. Neurosci.* 12, 679–690.
- Butler, R., Patterson, K., Woollams, A.M., 2012. In search of meaning: semantic effects on past-tense inflection. *Q. J. Exp. Psychol.* 65 (8), 1633–1656.
- Clahsen, H., 1999. Lexical entries and rules of language: a multidisciplinary study of German inflection. *Behav. Brain Sci.* 22, 991–1013.
- Crisp, J., Lambon Ralph, M.A., 2006. Unlocking the nature of the phonological-deep dyslexia continuum: the keys to reading aloud are in phonology and semantics. *J. Cogn. Neurosci.* 18, 348–362.
- Daugherty, K., Seidenberg, M.S., 1992. Rules of connections? The past tense revisited. Proceedings of the 14th Annual Meeting of the Cognitive Science Society. Lawrence Erlbaum Associates, pp. 259–264.
- de Diego Balaguer, R., Costa, A., Sebastián-Galles, N., Juncadella, M., Caramazza, A., 2004. Regular and irregular morphology and its relationship with agrammatism: evidence from two Spanish–Catalan bilinguals. *Brain Lang.* 91, 212–222.
- Deichmann, R., Schwarzbauer, C., Turner, R., 2004. Optimisation of the 3D MDEFT sequence for anatomical brain imaging: technical implications at 1.5 and 3 T. *Neuroimage* 21, 757–767.
- Démonet, J.-F., Chollet, F., Ramsay, S., Cardebat, D., Nespoulos, J.-L., Wise, R., et al., 1992. The anatomy of phonological and semantic processing in normal subjects. *Brain* 115, 1753–1768.
- Desai, R., Conant, L.L., Waldron, E., Binder, J.R., 2006. fMRI of past tense processing: the effects of phonological complexity and task difficulty. *J. Cogn. Neurosci.* 18, 278–297.
- Faroqi-Shah, Y., 2007. Are regular and irregular verbs dissociated in non-fluent aphasia? A meta-analysis. *Brain Res. Bull.* 74, 1–13.
- Faroqi-Shah, Y., Thompson, C.L., 2004. Semantic, lexical and phonological influences on the production of verb inflections in agrammatic aphasia. *Brain Lang.* 89, 484–498.
- Faroqi-Shah, Y., Thompson, C.K., 2007. Verb inflections in agrammatic aphasia: encoding of tense features. *J. Mem. Lang.* 56, 129–151.
- Frank, R.J., Damasio, H., Grabowski, T.J., 1997. Brainvox: an interactive, multimodal visualization and analysis system for neuroanatomical imaging. *Neuroimage* 5, 13–30.
- Friston, K.J., Price, C.J., 2011. Modules and brain mapping. *Cogn. Neuropsychol.* 28 (3–4), 241–250.
- Grodzinsky, Y., 2000. The neurology of syntax: language use without Broca's area. *Behav. Brain Sci.* 23, 1–21.
- Heim, S., Eickhoff, S.B., Amunts, K., 2009. Different roles of cytoarchitectonic BA 44 and BA 45 in phonological and semantic verbal fluency as revealed by dynamic causal modelling. *Neuroimage* 48, 616–624.
- Hickok, G., Poeppel, D., 2007. The cortical organisation of speech processing. *Nat. Rev. Neurosci.* 8, 393–402.
- Hoeffner, J., 1992. Are rules a thing of the past? The acquisition of verbal morphology by an attractor network. Proceedings of the 14th Annual Meeting of the Cognitive Science Society, pp. 861–866.
- Holland, R., Lambon Ralph, M.A., 2010. The anterior temporal lobe semantic hub is a part of the language neural network: selective disruption of irregular past tense verbs by rTMS. *Cereb. Cortex* 20, 2771–2775.
- Indefrey, P., Brown, C., Hagoort, P., Herzog, H., Sach, M., Seitz, R., 1997. A PET study of cerebral activation patterns induced by verb inflection. *Neuroimage* 5, S548.
- Jaeger, J.J., Lockwood, A.H., Kemmerer, D.L., Van Valin, R.D., Murphy, B.W., Khalak, H.G., n.d. A positron emission tomographic study of regular and irregular verb morphology in English. *Language* 72, 451–497.
- Joanisse, M.F., Seidenberg, M.S., 1999. Impairments in verb morphology after brain injury: a connectionist model. *Proc. Natl. Acad. Sci. U. S. A.* 96, 7592–7597.
- Joanisse, M.F., Seidenberg, M.S., 2005. Imaging the past: neural activation in frontal and temporal regions during regular and irregular past-tense processing. *Cogn. Affect. Behav. Neurosci.* 5, 282–296.
- Katzir, T., Misra, M., Poldrack, R.A., 2005. Imaging phonology without print: assessing the neural correlates of phonemic awareness using fMRI. *Neuroimage* 27, 106–115.
- Kirschen, M.P., Chen, S.H.A., Desmond, J.E., 2010. Modality specific cerebro-cerebellar activations in verbal working memory: an fMRI study. *Behav. Neurosci.* 23, 51–63.
- Laiacona, M., Caramazza, A., 2004. The noun/verb dissociation in language production: varieties of causes. *Cogn. Neuropsychol.* 21, 103–123.
- Lambon Ralph, M.A., Braber, N., McClelland, J.L., Patterson, K., 2005. What underlies the neuropsychological pattern of irregular > regular past-tense verb production? *Brain Lang.* 93, 106–119.
- Makuuchi, M., Bahmann, J., Anwender, A., Friederici, A.D., 2009. Segregating the core computational faculty of human language from working memory. *Proc. Natl. Acad. Sci. U. S. A.* 106, 8362–8367.
- McClelland, J., Patterson, K., 2002a. Rules or connections in past-tense inflections: what does the evidence rule out? *Trends Cogn. Sci.* 6, 465–472.
- McClelland, J.L., Patterson, K., 2002b. "Words or Rules" cannot exploit the regularity in exceptions. *Trends Cogn. Sci.* 6, 464–465.
- Miozzo, M., 2003. On the processing of regular and irregular forms of verbs and nouns: evidence from neuropsychology. *Cognition* 87, 101–127.
- Obleser, J., Kotz, S.A., 2010. Expectancy constraints in degraded speech modulate the language comprehension network. *Cereb. Cortex* 20, 633–640.
- Oh, T.M., Tan, K.L., Ng, P., Berne, Y.L., Graham, S., 2011. The past tense debate: is phonological complexity the key to the puzzle? *Neuroimage* 57, 271–280.
- Papoutsi, M., de Zwart, J.A., Jansma, J.M., Pickering, M.J., Bednar, J.A., Horwitz, B., 2009. From phonemes to articulatory codes: an fMRI study of the role of Broca's area in speech production. *Cereb. Cortex* 19, 2156–2165.
- Patterson, K., Marcel, A., 1992. Phonological ALEXIA or PHONOLOGICAL alexia? In: Alegria, J., Holender, D., Junca de Moraes, J., Radeau, M. (Eds.), *Analytic Approaches to Human Cognition*, XV, 440, Oxford, England: North-Holland, pp. 259–274.
- Patterson, K., Lambon Ralph, M.A., Hodges, J.R., McClelland, J.L., 2001. Deficits in irregular past-tense verb morphology associated with degraded semantic knowledge. *Neuropsychologia* 39, 709–724.
- Patterson, K., Lambon-Ralph, M.A., Jefferies, E., Woollams, A., Jones, R., Hodges, J.R., Rogers, T.T., 2006. "Presemantic" cognition in semantic dementia: six deficits in search of an explanation. *J. Cogn. Neurosci.* 18 (2), 169–183.
- Paulesu, E., Frith, C.D., Frackowiak, R.S., 1993. The neural correlates of the verbal component of working memory. *Nature* 362, 342–345.
- Pinker, S., 1997. Words and rules in the human brain. *Nature* 387, 547–548.
- Pinker, S., Ullman, M.T., 2002. The past and future of the past tense. *Trends Cogn. Sci.* 6, 456–463.
- Plunkett, K., Marchman, V., n.d. From rote learning to system building: acquiring verb morphology in children and connectionist nets. *Cognition* 48, 21–69.
- Poldrack, R.A., Wagner, A.D., Prull, M.W., Desmond, J.E., Glover, G.H., Gabrieli, J.D., 1999. Functional specialization for semantic and phonological processing in the left inferior prefrontal cortex. *Neuroimage* 10, 15–35.
- Prasada, S., Pinker, S., Snyder, W., 1990. Some evidence that irregular forms are retrieved from memory but regular forms are rule generated. 31st Annual Meeting of the Psychonomic Society, Chicago, IL.
- Price, C.J., 2010. The anatomy of language: a review of 100 fMRI studies published in 2009. *Ann. N. Y. Acad. Sci.* 1191, 62–88.
- Price, C.J., Crinion, J.T., Leff, A.P., Richardson, F.M., Schofield, T.M., Prejawa, S., Ramsden, S., Gazarian, K., Lawrence, M., Ambridge, L., Andric, M., Small, S.L., Seghier, M.L., 2010. Lesions sites that predict the ability to gesture how an object is used. *Arch. Ital. Biol.* 148 (3), 243–258.
- Romani, C., Galluzzi, C., 2005. Effects of syllabic complexity in predicting accuracy of repetition and direction of errors in patients with articulatory and phonological difficulties. *Cogn. Neuropsychol.* 22, 817–850.
- Romero, L., Walsh, V., Papagno, C., 2006. The neural correlates of phonological short-term memory: a repetitive transcranial magnetic stimulation study. *J. Cogn. Neurosci.* 18, 1147–1155.
- Rumelhart, D., McClelland, J.L., 1986. On learning the past tenses of English verbs. In: McClelland, J.L., Rumelhart, D.E. (Eds.), *Parallel Distributed Processing: Psychological and Biological Models*, vol. 2. MIT Press, Cambridge, MA, pp. 216–271.
- Seghier, M.L., Friston, K.J., Price, C.J., 2007. Detecting subject-specific activations using fuzzy clustering. *Neuroimage* 36, 594–605.
- Seghier, M.L., Ramlakhansingh, A., Crinion, J., Leff, A.P., Price, C.J., 2008. Lesion identification using unified segmentation–normalisation models and fuzzy clustering. *Neuroimage* 41, 1253–1266.
- Shapiro, K., Caramazza, A., 2003. Grammatical processing of nouns and verbs in left frontal cortex? *Neuropsychologia* 41, 1189–1198.
- Swinburn, K., Porter, G., Howard, D., 2004. *Comprehensive Aphasia Test*. Psychology Press, Hove.
- Tsapkini, K., Jarema, G., Kehayia, E., 2002. A morphological processing deficit in verbs but not in nouns: a case study in a highly inflected language. *J. Neurolinguist.* 15, 265–288.
- Tyler, L.K., DeMornay-Davies, P., Anokhina, R., Longworth, C., Randall, B., Marslen-Wilson, W.D., 2002. Dissociations in processing past tense morphology: neuropathology and behavioral studies. *J. Cogn. Neurosci.* 14, 79–94.

- Tyler, L.K., Stamatakis, E.A., Jones, R.W., Bright, P., Acres, K., Marslen-Wilson, W.D., 2004. Deficits for semantics and the irregular past tense: a causal relationship? *J. Cogn. Neurosci.* 16, 1159–1172.
- Ullman, M.T., 2001a. A neurocognitive perspective on language: the declarative/procedural model. *Nat. Rev. Neurosci.* 2, 717–726.
- Ullman, M.T., 2001b. The declarative/procedural model of lexicon and grammar. *J. Psycholinguist. Res.* 30, 37–69.
- Ullman, M.T., Corkin, S., Coppola, M., Hickok, G., Growdon, J.H., Koroshetz, W.J., et al., 1997. A neural dissociation within language: evidence that the mental dictionary is part of declarative memory, and that grammatical rules are processed by the procedural system. *J. Cogn. Neurosci.* 9, 266–276.
- Ullman, M.T., Pancheva, R., Love, T., Yee, E., Swinney, D., Hickok, G., 2005. Neural correlates of lexicon and grammar: evidence from the production, reading, and judgment of inflection in aphasia. *Brain Lang.* 93, 185–238.
- Visser, M., Embleton, K.V., Jefferies, E., Parker, G.J., Lambon Ralph, M.A., 2010. The inferior, anterior temporal lobes and semantic memory clarified: novel evidence from distortion-corrected fMRI. *Neuropsychologia* 48, 1689–1696.
- Wagner, R.K., Torgeson, J.K., Rashotte, C.A., 1993. *Comprehensive Test of Phonological Processing (CTOPP)*. Pro-Ed, Austin, TX.
- Woollams, A.M., Joanisse, M., Patterson, K., 2009. Past-tense generation from form versus meaning: behavioural data and simulation evidence. *J. Mem. Lang.* 61, 55–76.