



CASE REPORT

Case 1:

Management of Caries in A Young Child

**In partial fulfilment of the degree
Clinical Doctorate in Paediatric Dentistry
Eastman Dental Institute
University College London
2012 - 2015**

Submitted by

Lama Dakkouri

DDS (Jordan), MFD (Ireland)

Table of Contents

Summary	3
Clinical photographs	4
Pre-operative	4
Post-Operative	5
Case History	6
Pre-Treatment Assessment	6
Clinical Examination	7
Extraoral examination	7
Intraoral examination	7
Special Investigations	8
Diagnosis and Treatment Planning	9
Diagnosis	9
Treatment Objectives	9
Treatment Plan	9
Treatment progress and dental management.....	11
Clinical photographs upon completion of treatment	15
Appraisal and Discussion.....	20
References:	23

Summary

M.A, 6 year 2 month anxious little girl; whom recently just moved to UK from Iraq, was referred by her general dental practitioner (GDP) to the Department of Paediatric Dentistry at Eastman Dental Hospital for the management of her carious primary molars complicated by uncooperative behaviour towards dental treatment.

Chief complaint: M.A had a history of abscess related to the LLE when presented to GDP, and only Analgesics were prescribed. No further signs or symptoms reported at time of presentation.

Examination: The patient was on a cariogenic diet. She is a regular dental attendee but had no previous experience of dental treatment. She presented with multiple decays affecting her E's and D's accompanied with open bite secondary to thumb sucking. Patient seemed to be anxious towards dental treatment.

Treatment provided up to date:

1. Prevention and acclimatization

- According to (Delivering better Oral health: an evidence-base tool kit for prevention) third edition
- Oral hygiene & habit breaking instructions
- Dietary advise

2. Restorations

- Fissure sealant on all 6's
- Caries excavation and composite filling on ULD, ULE, URD, URE, and LRD
- Pulpotomy and stainless steel crown on LLD
- Extraction of LLE and LRE

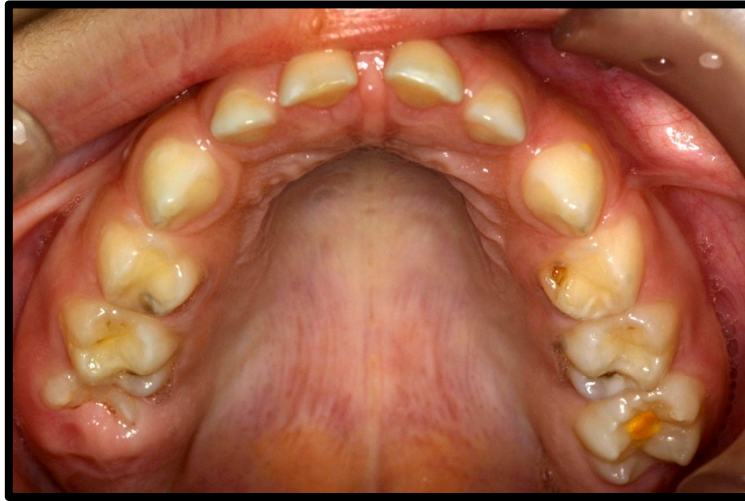
3. Maintenance and recall/ review

- Monitor permanent teeth eruption
- Monitor all restored primary teeth
- Monitor habit and reinforce cessation, consider referral to the orthodontic department in older age if behaviour therapy not effective

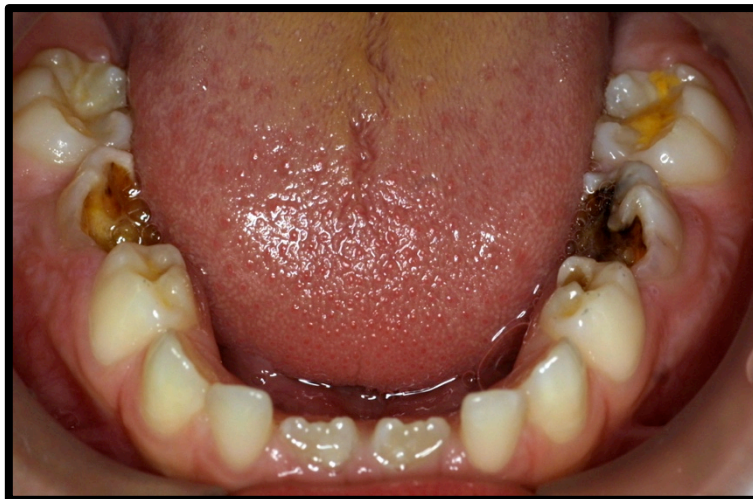Treatment was carried out under local anaesthesia, in conjunction with inhalation sedation in order to minimise the risk of loss of cooperation.

Clinical photographs

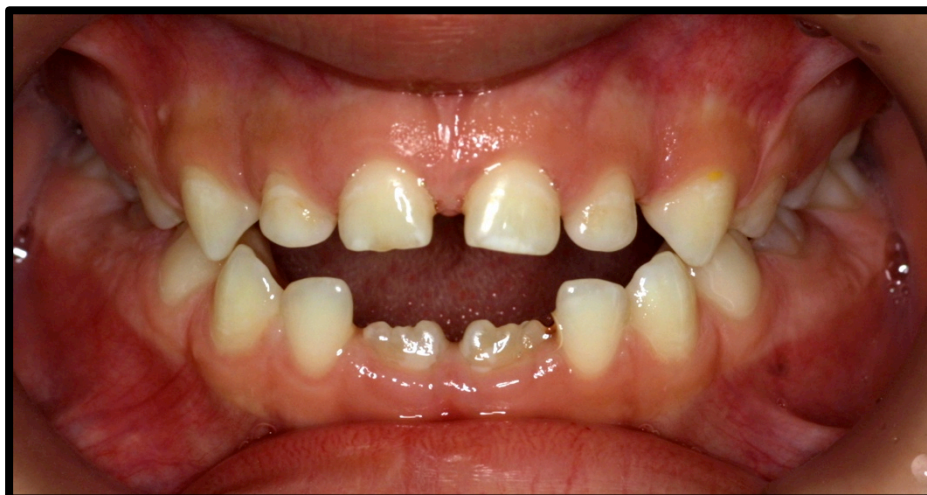Pre-operative



Maxillary Arch

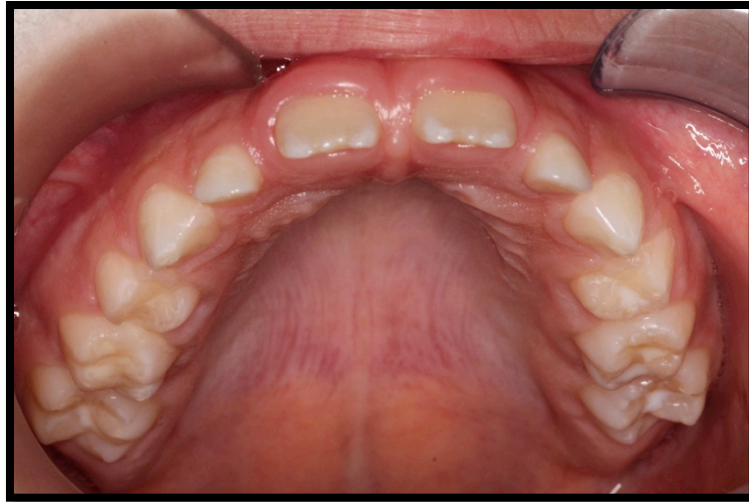

Mandibular Arch

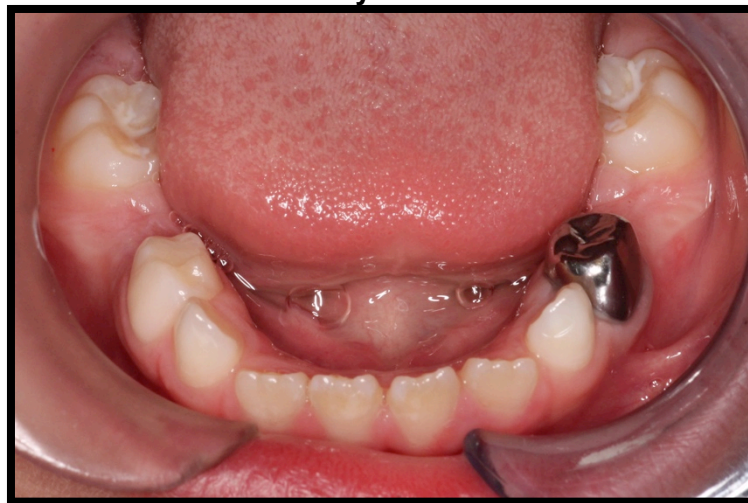

Frontal View

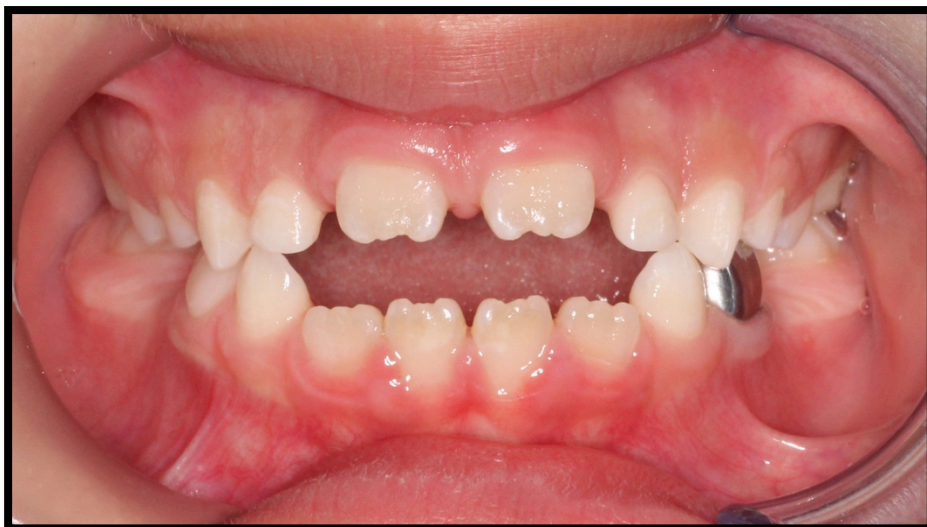Post-Operative



Maxillary Arch



Mandibular Arch



Frontal View

Case History

Personal Details

Initials: M.A

DOB: 11/04/2007

Age on presentation: 5 years and 6 months

Age on last appointment: 6 years and 1 month.

Sex: Female



Pre-Treatment Assessment

Refereed by: GDP

History of Presenting Complaint: Free of pain but presented with caries affecting upper and lower posterior teeth.

Medical History

- Fit and healthy, no known allergies
- Full term, normal delivery.
- No history of severe illness during the first three years of life.

Dental History

- Regular attendee to dentist back at her hometown (Iraq)
- No history of previous dental treatment

Family and Social History

- No significant family history
- Has younger 3 years baby brother
- Recently moved to UK
- Attends 'Argyle Primary School'.

Diet

- Snacks: Sweets frequently
- Fizzy drinks occasionally
- Breastfeeding stopped by the age of two.

Oral Hygiene

- Brushed twice/day, manual toothbrush
- Children's toothpaste

Habits

- Thumb sucking since age 2 years

Clinical Examination

M.A was willing to sit on the chair, however she showed signs of anxiety towards dental treatment earlier.

→ Extraoral examination

- Symmetrical face, no extra oral swelling
- No regional lymphadenopathy.
- Normal mouth opening.
- No TMJ abnormality noted.

→ Intraoral examination

- Soft tissue: nothing significant.
- Oral hygiene: Poor (Plaque Index 0.7).
- Early mixed dentition as charted

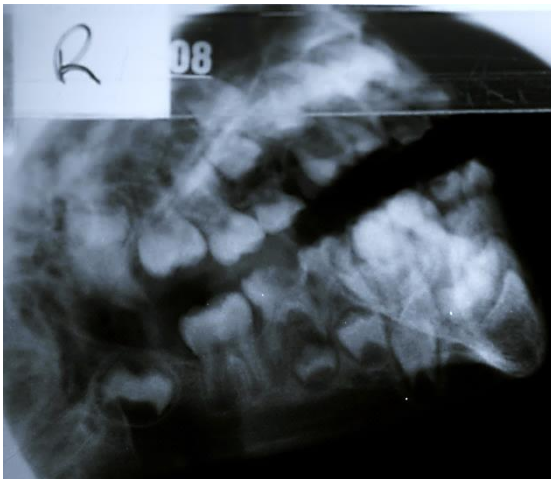
6	E	D	C	B	A		A	B	C	D	E	6
6	E	D	C	B	1		1	B	C	D	E	6
			E	D					D	E		
			E	D					D	E		

- Caries
- Mobility: Nil.
- UR6: partially erupted.
- Occlusion:
 - Class I skeletal relation
 - Class I right and left molar relation
 - 2 – 3 mm Anterior open bite related to thumb sucking habit

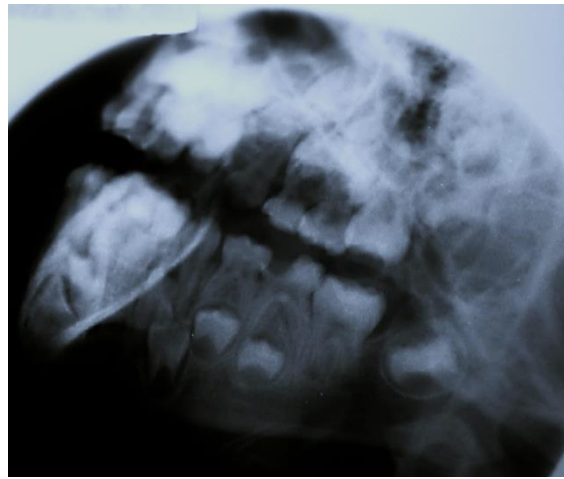
Special Investigations

Radiographs

Pre – operative Bi-molars
X-rays taken on 31-Oct-2012



Right



Left

Radiograph finding:

- Radiolucencies suggesting caries on all D's and E's

Diagnosis and Treatment Planning

Diagnosis

- Dental caries secondary to cariogenic diet.
- Anterior open bite related to thumb sucking habit.
- Dental anxiety.

Treatment Objectives

- Improve oral hygiene through instructions, fluoride advice, and dietary education.
- Thumb sucking cessation through behavioural techniques.
- Manage anxiety and promote positive attitude towards dental care.
- Restore oral health (function & aesthetics).
- Monitor development of permanent dentition

Treatment Plan

1) Prevention and Acclimatization

- Establish a preventive regimen consistent with the Department of Health preventive toolkit (third edition edition - 2014).
- Incorporation of nitrous oxide inhalation sedation as a pharmacological behavioural management technique.
- Thumb sucking habit breaking through advices and encouragements to patient and parents.

2) Restoration

Restorative care through quadrant dentistry:

I. URQ:

- ★ UR6- fissure sealant. (When fully erupted)
- ★ URE and URD- caries excavation and composite filling.

II. ULQ:

- ★ UL6- fissure sealant.
- ★ ULE and ULD- caries excavation and composite filling.

III. LLQ:

- ★ LL6- fissure sealant.
- ★ LLE- extraction.
- ★ LLD- pulpotomy and SSC.

IV. LRQ:

- ★ LR6- fissure sealant.
- ★ LRE- extraction.
- ★ LRD- caries excavation and composite filling.

3) *Maintenance and follow up*

- Clinical review every 3 months.
- Radiological review every 6 -12 months.
- Reinforcement of dietary & oral hygiene advice.
- Assess anterior open bite and thumb sucking habit. Consider referral orthodontics in older age (7 years old and above).

The above restorative treatment was done under local anaesthesia in conjunction with inhalation sedation. Her behaviour was assessed in each session using the facial imaging scale (FIS) to monitor her acceptance and attitude to each dental treatment performed.

Treatment progress and dental management

Visit 1: 31/10/2012

- Attended with father in a new patient clinic.
- No signs or symptoms.
- Complete history taken, with clinical and radiographical examination.
- Provisional treatment plan formulated and discussed with father.
- Inhalation sedation agreed to control anxiety and consent obtained.
- A 3-day diet sheet analysis provided.
- Adult tooth paste (1350 ppm fluoride) and spitting after brushing advised
- Thumb sucking habit history noted and habit breaking instructions given.
- Tell-Show-Do.
- Pre-operative clinical photographs.

Visit 2: 20/2/2013

- Attended with father.
- C.C: Nil.
- Extra oral: Nil
- Intra oral: Oral hygiene improved (Plaque Index – 33%).

Treatment:

- Acclimatization and Introduction to inhalation sedation. 30% Nitrous oxide to 70% Oxygen in 6 L/min flow.
- Cleaning and polishing of teeth.
- Delton occlusal fissure sealant applied on fully erupted 6's
- LRE and LLE stabilized with zinc oxide Eugenol (IRM®).
- Topical anaesthesia (20% benzocaine gel) and rubber dam introduction.
- Duraphat (2.2% Fluoride) varnish applied on presented teeth.
- 100% Oxygen for 5 minutes, post-operative instructions.
- Diet advice given based on the patient diet sheet analysis findings.
- Oral hygiene instructions reinforced.
- Thumb sucking habit interruption reinforced and monitored.
- FIS.

⇒ Next visit: Restore URE, URD under LA and IS.

Visit 3: 22/4/2013

- Attended with father.
- C.C: Nil.
- Extra oral: Nil
- Intra oral: Nil

Treatment:

- Inhalation sedation
- Topical anaesthesia
- Local anaesthesia infiltration administered (2.2 ml of 2% lignocaine hydrochloride with 1:80,000 adrenaline) on URE and URD areas.
- Rubber dam isolation of URE and URD by DW clamp on URE.

URE^(O) and URD^(OD):

- Caries excavation using high-speed hand piece and 330 bur.
- Gradia posterior composite filling.
- Finishing and polishing using composite finishing burs and white stone.
- Oxygen and post-operative instructions as previously.
- OHI, diet, and habit breaking instructions reinforced.
- FIS

⇒ N.V: Restore ULE + ULD under LA and IS.

Visit 4: 1/5/2013

- Attended with father.
- C.C: Nil.
- Extra oral: Nil.
- Intra oral: Mild improvement in oral hygiene (Plaque Index – 17%).

Treatment:

- **ULD^(OP) + ULE^(O)** : Fillings under IS and LA as described last visit.

⇒ N.V: Extract LLE, restore LLD under LA and IS.

Visit 5: 8/5/2013

- Attended with mother.
- C.C: Nil.
- Extra oral: Nil.
- Intra oral: Improved oral hygiene (Plaque Index – 11%).

Treatment:

- Inhalation sedation and topical anaesthesia.
- Local anaesthesia (4% articaine) infiltration on LLD and LLE. Inter-papillary and lingually anaesthesia administered on LLE area.
- Rubber dam isolation of LLD by DW clamp on LLD.

LLD^(O):

- Caries removed – noted pulpal involvement.
- Vital pulpotomy with 15.5% ferric sulphate (Astringent[®]) performed.
- Haemostasis achieved and IRM[®] packed into pulp chamber.
- Tooth prepared for SSC using diamond burs.
- SSC size 5 (3M) cemented using GIC luting cement.

LLE: Extraction using elevator and forceps.

- Oxygen and Instructions as previous visits.
- FIS.

⇒ N.V: Extract LRE, restore LRD under LA and IS.

Visit 6: 29/5/2013

- Attended with mother.
- C.C: Nil.
- Extra oral: Nil.
- Intra oral: Improved oral hygiene (Plaque Index – 5%).

Treatment:

- Inhalation sedation, topical and local anaesthesia (articaine), rubber dam as described last visit.

LRD^(O): Caries excavation and composite filling as described earlier.

LRE: Extraction using elevator and forceps.

- Oxygen and Instructions as previous visits.
- FIS.
- Diet sheet given again.

⇒ Next visit: Review of present restorations.

Visit 7: 5/6/2013

- Attended with mother.
- C.C: Nil.
- Extra oral: Nil.
- Intra oral: Nil

Treatment:

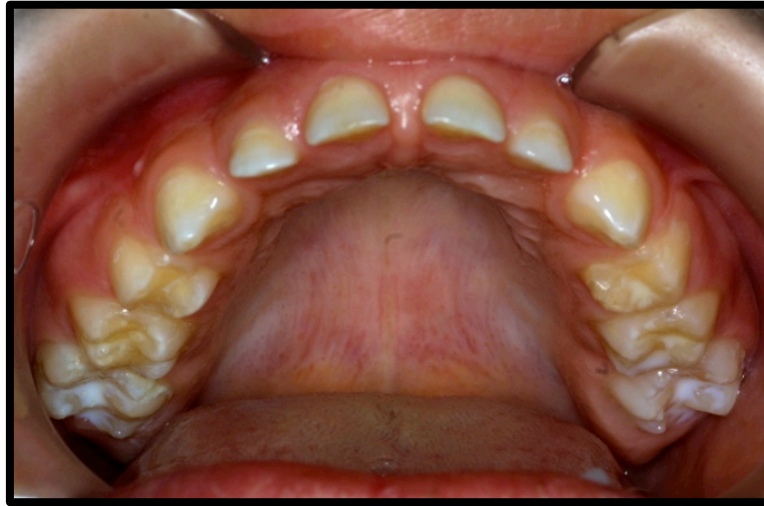- Clinical and radiographical examination to assess present restoration.
- Delton occlusal fissure sealant applied on UR6 under cotton roll isolation and without inhalation sedation.
- Diet sheet discussed and habits compared to previously.
- Previous instructions reinforced.
- Post treatment clinical photos.
- FIS.

⇒ N.V after 3 months:

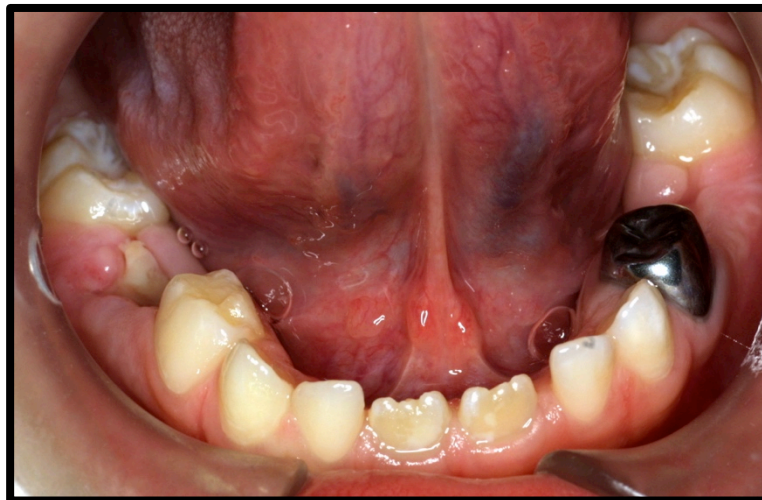- Review.
- Fluoride.
- Habit monitoring.

Clinical photographs upon completion of treatment

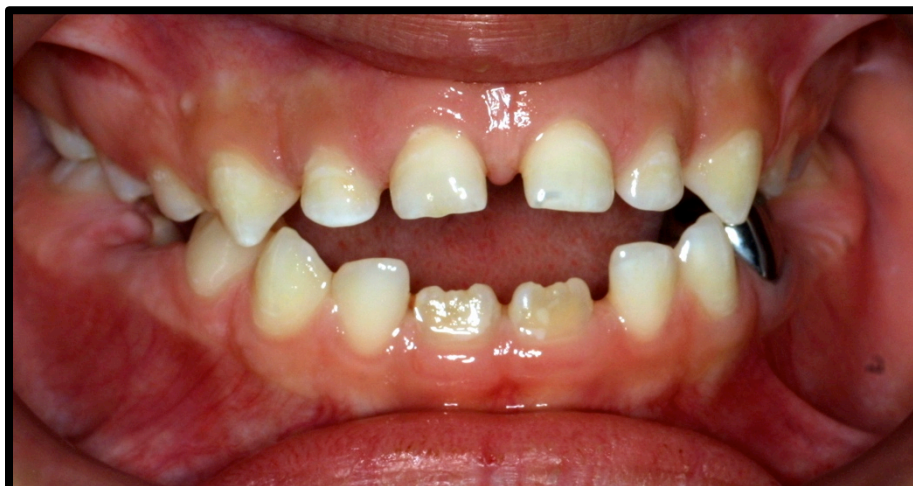Post-Operative 5/6/2013



Maxillary Arch

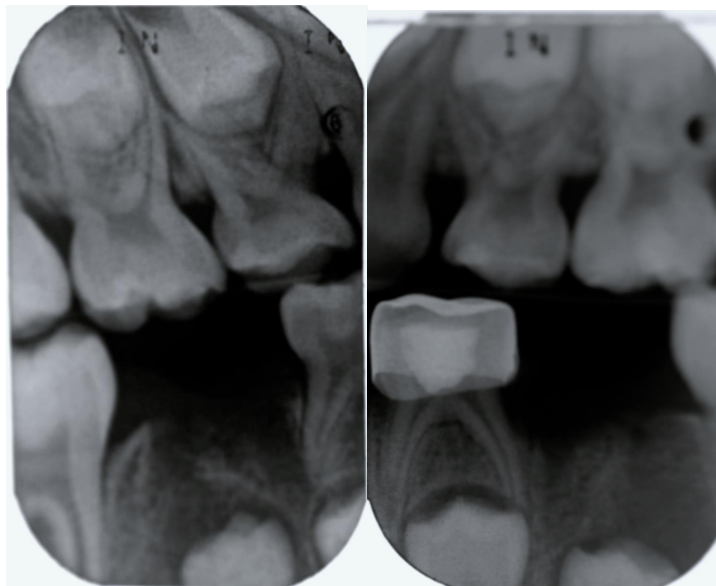


Mandibular Arch



Frontal View

Post-operative Radiographs upon completion of dental treatment



Right

Left

Post – operative right and left vertical bitewings with no significant findings.(5/6/2013)

Visit 8: 6/9/2013

Attended with mother.

C.C:Nil.

Extraoral:Nil.

Intraoral:Nil

Treatment:

- Review of present restorations.
- Fluoride.
- Oral hygiene reinforcement
- Diet habits reinforcement
- Habit monitoring.

⇒ N.V after 6 months: review

Visit 9: 5/3/2014

Attended with mother.

C.C:Nil.

Extraoral:Nil.

Intraoral:Nil

Treatment:

- Review of present restorations.
- Fluoride.
- Oral hygiene reinforcement
- Diet habits reinforcement
- Habit monitoring.

⇒ N.V after 6 months: review

Visit 10: 6/9/2014

Attended with mother.

C.C:Nil.

Extraoral:Nil.

Intraoral:Nil

Treatment:

- Review of present restorations.
- Fluoride.
- Oral hygiene reinforcement
- Diet habits reinforcement
- Habit monitoring.
- Photos

⇒ Discharge

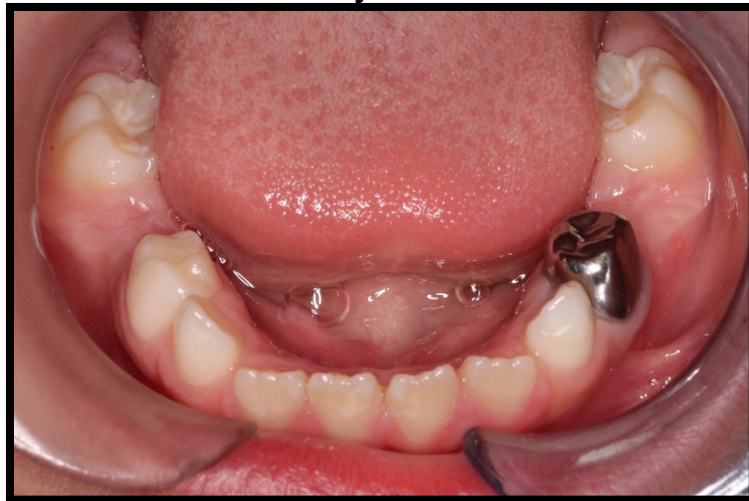Future Treatments and Managements Considerations:

- ❖ Thumb sucking habit-breaking monitoring and considering Orthodontic referral when above 7 years old.

Post-Operative clinical photos 6/9/2014



Maxillary Arch

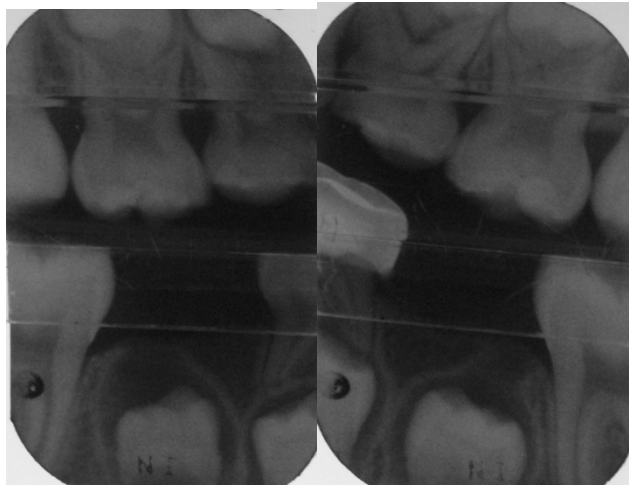


Mandibular Arch



Frontal View

Post-operative Radiographs after 1 year



R

L

Post – operative right and left vertical bitewings with no significant findings (6/9/2014)

Appraisal and Discussion

The main goals of M.A's dental care were to get healthy dentition and to induct a helpful dental attitude for persistence of oral hygiene. Therefore, treating her decayed primary teeth was essential to promote good oral health for forthcoming permanent teeth.

When presented she required several invasive treatments. Although her dental history revealed unsuccessful previous experience due to anxious behaviour toward dental environment, she responded well to acclimatisation and inhalation sedation supplemented by NPBMT.

M.A did not report any pain when first presented, so introduction to dental treatment by prophylaxis and temporization of grossly carious teeth performed to prevent pain and infection till scheduled for extractions. On each session, M.A's cooperation and acceptance to the dental environment reassessed constantly.

→ **Behaviour Management:**

Inhalation sedation with nitrous oxide is a conscious sedation technique with high success rate (Blain and Hill, 1998, Lyratzopoulos and Blain, 2003). Thus, it is favoured in managing mild to moderately anxious paediatric dental patient (Hosey, 2002).

Articaine is an amide local anaesthetic, it contains ester and thiophene group to increase liposolubility. This improves the diffusion of anaesthetic and consequently provides a superior effect. A systematic review compared the efficacy and safety of articaine to lignocaine and concluded that articaine is better than lignocaine in routine dental treatment, yet its use in children bellow 4 years of age not recommended as no evidence to support such usage (Katy, 2010). Which is inapplicable in M.A's case.

Because anxiety has significant impact on treatment, measuring it is essential to accomplish a treatment plan. M.A's level of anxiety was measured at each visit to assess her general concern, acceptance, and feeling about the dental treatment using the facial image scale (FIS) (Buchanan and Niven, 2002).

→ **Thumb sucking habit:**

Children suck their thumbs specially bellow 4 years old. As indicated in literature no any active treatment should be attempted until above 7 years old. Hence, in M.A's age,

behavioural therapy and monitoring her anterior open bite malocclusion is the most appropriate option (FRIMAN et al., 1986, Warren et al., 2005).

→ **Prevention:**

M.A was a high caries risk patient in mixed dentition. It is essential to evaluate the caries risk of the patient, as the decision for preventive therapy should be correlated to the risk (Hale, 2003) . M.A's was considered a high caries risk patient that requires special preventive interventions.

★ **Dietary Advise**

M.A consumed frequent cariogenic snacks in between meal and lots of throughout the day. It was suggested by (Deery and Toumba, 2012) that a positive and effective diet advice should be realistic. She was advised to cut down on sugary intake and have healthy snacks in between meal.

★ **Tooth Brushing**

Tooth brushing is a universal habit for controlling plaque and considered as a method to deliver fluoride. M.A used to brush unsupervised twice daily with children's toothpaste. She was advised to use adult toothpaste and to be supervised while brushing since this has been shown by (Curnow et al., 2010) to decrease caries level by 56%. She was also instructed to spit instead of rinse in order to increase the effect of the fluoridated tooth paste as recommended by (Pitts et al., 2012). As a result, M.A's oral hygiene had improved towards the end of treatment.

★ **Fluoride**

The efficacy of fluoride toothpastes in the prevention of dental caries was concluded in 2 systematic reviews (Marinho et al., 2003) and (Ammari et al., 2003). As M.A was a high-risk caries patient, she was advised to use adult toothpaste containing a minimum of 1350 ppm of fluoride, and a professional involvement by fluoride application as a prevention measure 3 times in 12 months, according to the Department of Health toolkit second edition.

→ **Fissure sealant:**

Fissure sealant application is promoted in high caries risk patients (Beauchamp et al., 2008). A recent systematic review has demonstrated more than 9 years effectiveness and 85% retention after 2 years (Ahovuo-Saloranta et al., 2008) and is recommended in the BSPD guidelines, 2000.

→ **Restorations:** The choice of restoration is established upon:

- The age and the dental development
- Location and extent of the lesion and any related signs and symptoms

Restoring primary molars might seem obvious but surprisingly limited evidence is available and (Tickle et al., 2002, Tickle et al., 2008) was the first to start this debate. However, unrestored primary teeth has adverse effect on the quality of life in children as stated by (Sheiham, 2006).

A systematic review (Yengopal et al., 2009) found that there is no certain recommendation for which filling material to use and therefore this will obviously depend on the clinical scenario. In M.A case her cooperation and the extent of the lesion allowed to the use of composite fillings to restore her teeth without any difficulty or complications.

→ **Vital Pulpotomy:**

Ferric sulphate pulpotomy was the technique used for the pulpally involved primary molar tooth. In concentration of 15.5% it's an excellent haemostatic agent, forming a ferric ion – protein complex on contact with blood that stops further bleeding by sealing the vessels.

→ **Stainless steel crown (SSC):**

It was indicated to restore LLD with SSC after pulp therapy as recommended by (Kindelan et al., 2008) at the UK national guidelines. Although, a Cochrane systematic review concluded that there is no evidence available to suggest superiority of SSCs in restoring primary molars (Innes et al., 2007).

In consideration of the treatment outcome, up to now it had been satisfactory. M.A completed the treatment planned established earlier and will be reviewed every 3 months for a year time before being discharged.

References:

- AHOVUO-SALORANTA, A., HIIRI, A., NORDBLAD, A., MÄKELÄ, M. & WORTHINGTON, H. V. 2008. Pit and fissure sealants for preventing dental decay in the permanent teeth of children and adolescents. *Cochrane Database Syst Rev*, 4.
- AMMARI, A., BLOCH-ZUPAN, A. & ASHLEY, P. 2003. Systematic review of studies comparing the anti-caries efficacy of children's toothpaste containing 600 ppm of fluoride or less with high fluoride toothpastes of 1,000 ppm or above. *Caries research*, 37, 85-92.
- BEAUCHAMP, J., CAUFIELD, P. W., CRALL, J. J., DONLY, K., FEIGAL, R., GOOCH, B., ISMAIL, A., KOHN, W., SIEGAL, M. & SIMONSEN, R. 2008. Evidence-based clinical recommendations for the use of pit-and-fissure sealants A report of the American Dental Association Council on Scientific Affairs. *The Journal of the American Dental Association*, 139, 257-268.
- BLAIN, K. M. & HILL, F. 1998. The use of inhalation sedation and local anaesthesia as an alternative to general anaesthesia for dental extractions in children. *British dental journal*, 184, 608-611.
- BUCHANAN, H. & NIVEN, N. 2002. Validation of a Facial Image Scale to assess child dental anxiety. *International Journal of Paediatric Dentistry*, 12, 47-52.
- CURNOW, M., PINE, C., BURNSIDE, G., NICHOLSON, J., CHESTERS, R. & HUNTINGTON, E. 2010. A randomised controlled trial of the efficacy of supervised toothbrushing in high-caries-risk children. *Caries Research*, 36, 294-300.
- DAVIES, G. M. & DAVIES, R. M. 2008. Delivering better oral health--an evidence-based toolkit for prevention: a review. *Dental update*, 35, 460-462.
- DEERY, C. & TOUMBA, K. 2012. Diagnosis and prevention of dental caries. *Paediatric dentistry*, 85.
- Department of Health, 2015. Delivering Better Oral Health An evidence-based toolkit for prevention - third edition.
- FRIMAN, P. C., BARONE, V. J. & CHRISTOPHERSEN, E. R. 1986. Aversive taste treatment of finger and thumb sucking. *Pediatrics*, 78, 174-176.
- HALE, K. 2003. Oral health risk assessment timing and establishment of the dental home. *Pediatrics*, 111, 1113.
- HOSEY, M. 2002. Managing anxious children: the use of conscious sedation in paediatric dentistry. *International Journal of Paediatric Dentistry*, 12, 359-372.
- INNES, N., RICKETTS, D. & EVANS, D. 2007. Preformed metal crowns for decayed primary molar teeth. *Cochrane Database Syst Rev*, 1.
- KATYAL, V. 2010. The efficacy and safety of articaine versus lignocaine in dental treatments: a meta-analysis. *journal of dentistry*, 38, 307.
- KINDELAN, S., DAY, P., NICHOL, R., WILLMOTT, N. & FAYLE, S. 2008. UK National Clinical Guidelines in Paediatric Dentistry: stainless steel preformed crowns for primary molars. *International Journal of Paediatric Dentistry*, 18, 20-28.
- LYRATZOPOULOS, G. & BLAIN, K. 2003. Inhalation sedation with nitrous oxide as an alternative to dental general anaesthesia for children. *Journal of Public Health*, 25, 303-312.
- MARINHO, V., HIGGINS, J., LOGAN, S. & SHEIHAM, A. 2003. Systematic review of controlled trials on the effectiveness of fluoride gels for the prevention of dental caries in children. *Journal of dental education*, 67, 448-458.
- PITTS, N., DUCKWORTH, R., MARSH, P., MUTTI, B., PARNELL, C. & ZERO, D. 2012. Post-brushing rinsing for the control of dental caries: exploration of the

- available evidence to establish what advice we should give our patients. *British Dental Journal*, 212, 315-320.
- SHEIHAM, A. 2006. Dental caries affects body weight, growth and quality of life in pre-school children. *British dental journal*, 201, 625-626.
- TICKLE, M., BLINKHORN, A. & MILSOM, K. 2008. The Occurrence of Dental Pain and Extractions over a 3-Year Period in a Cohort of Children Aged 3-6 Years. *Journal of public health dentistry*, 68, 63-69.
- TICKLE, M., MILSOM, K., KING, D., KEARNEY-MITCHELL, P. & BLINKHORN, A. 2002. The fate of the carious primary teeth of children who regularly attend the general dental service. *British dental journal*, 192, 219-223.
- WARREN, J. J., SLAYTON, R. L., YONEZU, T., BISHARA, S. E., LEVY, S. M. & KANELIS, M. J. 2005. Effects of nonnutritive sucking habits on occlusal characteristics in the mixed dentition. *Pediatric dentistry*, 27, 445-450.
- YENGOPAL, V., HARNEKER, S. Y., PATEL, N. & SIEGFRIED, N. 2009. Dental fillings for the treatment of caries in the primary dentition. *Cochrane Database Syst Rev*, 15.



CASE REPORT

Case 2:

(Special Care Dentistry for the Child & Adolescent)

**In partial fulfilment of the degree
Clinical Doctorate in Paediatric Dentistry
Eastman Dental Institute
University College London
2012 - 2015**

Submitted by

Lama Dakkouri

DDS (Jordan), MFD (Ireland)

Contents

CONTENTS.....	II
CASE SUMMARY	III
PRE-OPERATIVE CLINICAL PHOTOGRAPHS (15/08/2013).....	V
POST-OPERATIVE CLINICAL PHOTOGRAPHS (07/07/2015).....	VI
CASE HISTORY.....	1
PERSONAL DATA:.....	1
REASON FOR REFERRAL	1
CHIEF COMPLAINT (C/O)	1
MEDICAL HISTORY (MH).....	1
FAMILY HISTORY	1
SOCIAL HISTORY	1
DENTAL HISTORY	2
ORAL HYGIENE.....	2
DIET	2
HABITS	2
CLINICAL EXAMINATION.....	3
EXTRA-ORAL EXAMINATION (E/O)	3
INTRA-ORAL EXAMINATION (I/O).....	3
PRE-OPERATIVE RADIOGRAPHS	5
DIAGNOSIS AND TREATMENT PLANNING.....	7
DIAGNOSIS.....	7
TREATMENT OBJECTIVES.....	7
PROVISIONAL TREATMENT PLAN.....	7
VISIT 1: 15/08/2013.....	9
VISIT 2: 09/09/2013.....	9
VISIT 3: 22/09/2013.....	10
VISIT 4 02/10/2013:.....	10
VISIT 5 17/10/2013.....	11
VISIT 6 14/11/2013.....	12
VISIT 7 28/11/2013:.....	12
VISIT 8 16/01/2014.....	13
VISIT 9 24/01/2014.....	13
VISIT 10 27/03/2014.....	14
VISIT 11 08/09/2014.....	14
VISIT 12 07/01/2015 (IN HYPODONTIA CLINIC).....	14
VISIT 13 07/03/2015.....	15
VISIT 14 07/07/2015.....	15
FUTURE MANAGEMENT	15
POST-OPERATIVE CLINICAL PHOTOGRAPHS (07/07/2015).....	16
POST-OPERATIVE RADIOGRAPHS (07/07/2015).....	18
APPRAISAL AND DISCUSSION.....	19

Case summary

N.L. is a 10-year-old young girl who was referred by the hypodontia clinic at the Eastman Dental Hospital to the Department of Paediatric Dentistry for the management of her missing permanent teeth and defected UR1.

Her medical history involved naevoid hypopigmentation (Incontinentia pigmenti) with no complications. She is under the dermatological care in GOSH.

She was a regular dental attendee. Also, N had dental treatment at the age of 6 to construct removable partial dentures to replace her missing teeth. But, the dentures constructed previously are not fitting anymore. N had a history of natal teeth that were extracted the day she was born and some filling done in her primary teeth.

When she first presented, she was concerned about her smile and the look of her teeth. Upon examination, she presented with missing permanent teeth and retained primary teeth. Also, her UR1 is a malformed tooth with a deficient composite filling on the labial surface.

Treatment was carried out under local anaesthesia (LA) and in conjunction with non-pharmacological behaviour management (NPBM) techniques.

Treatment involved:

Immediate and preventive treatment

Liaise with GOSH.

OHI.

Dietary education.

Fluoride varnish application (duraphat Fluoride varnish 2.26%) every 6 months.

Advice on using adult toothpaste and spitting instead of rinsing.

Restorative and Prosthodontics (as planned in hypodontia clinic)

- Adjustment of UR1
- Stabilisation of present dentition:
- Upper and lower removable partial dentures to restore occlusion and aesthetics

6	E	D	C	2	1		3	4	6
7 ²	6	E		B	1		C	E	6

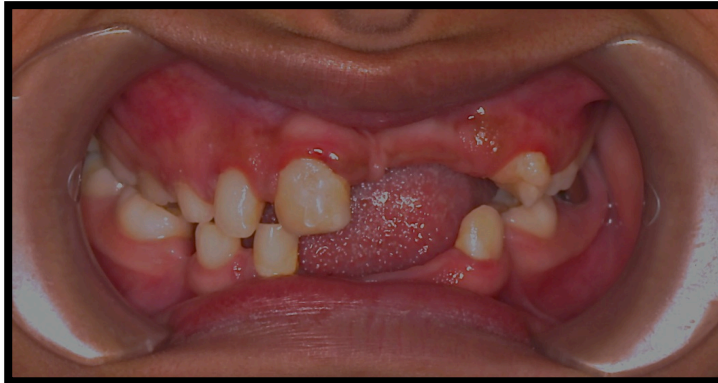Maintenance and follow up:

Clinical reviews every 6 months to monitor restorations, oral health and occlusion

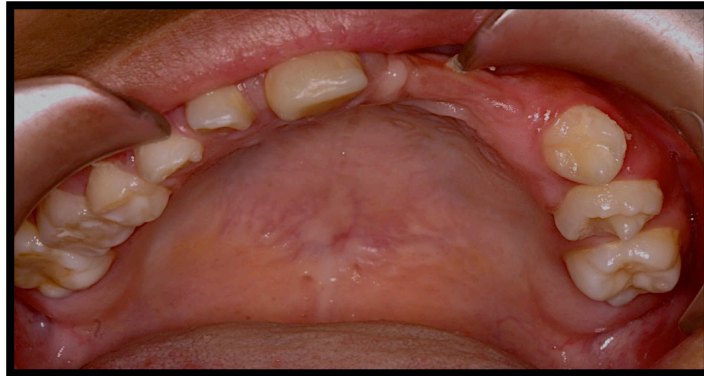
Annual reviews with the hypodontia clinic for further future planning

Pre-operative clinical photographs (15/08/2013)

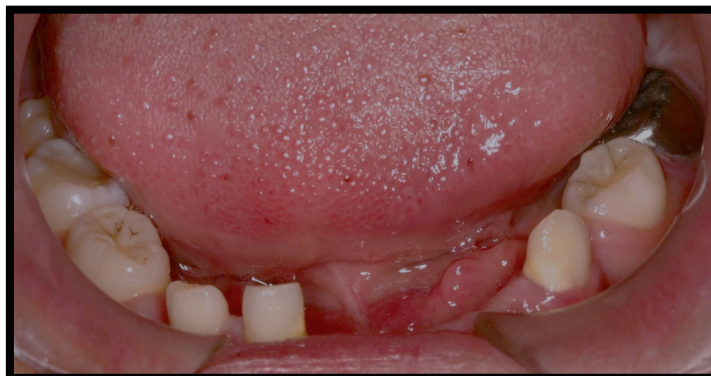Frontal view



Upper occlusal view

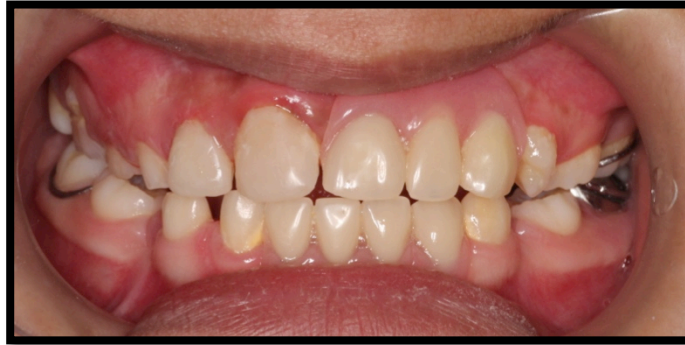

Lower occlusal view

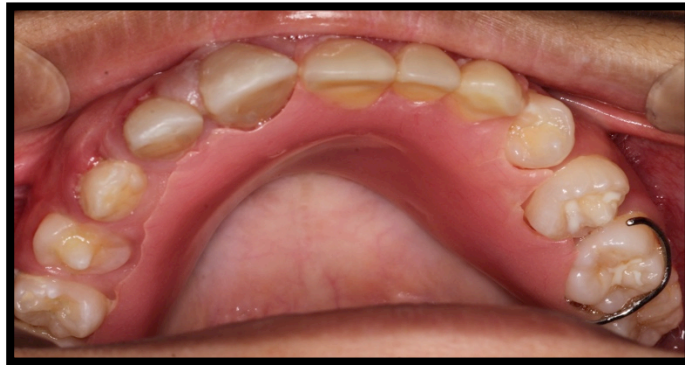

Post-operative clinical photographs (07/07/2015)

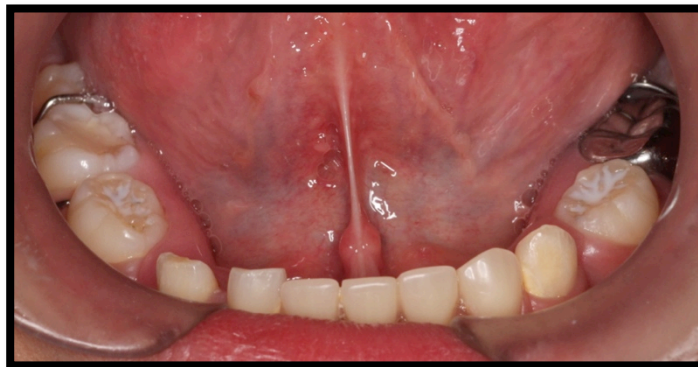Frontal view



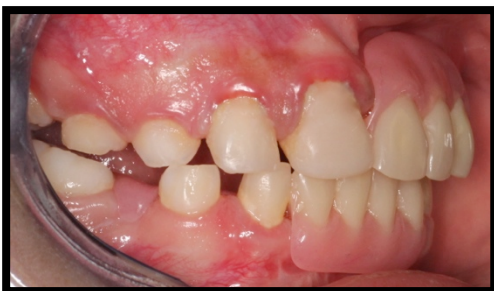Upper occlusal view



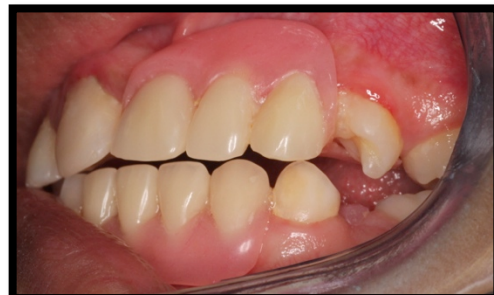Lower occlusal view



Right side view



Left side view



Case History

Personal data:

N.L.

female.

Date of Birth: 13/03/2003.

Referred by: hypodontia clinic

Date of first attendance: 15/08/2013.

Age at presentation: 10 years and 5 months.

Reason for referral

N.L. was referred regarding:

- Missing permanent teeth and retained primary teeth
- Malformed permanent dentition

Chief Complaint (C/O)

N complained about the appearance of her teeth.

Medical History (MH)

Naevoid hypopigmentation (incontinentia pigmenti)

Diagnosed in 2010.

On regular reviews at GOSH.

She was born full-term with normal delivery. Her immunisations were up-to-date and did not suffer any early childhood illnesses.

IP is an inherited X-linked dominant medical condition

Family History

No any family member has the same medical condition

No family history of dental abnormalities.

Social History

She had one older brother

Attends school

Dental History

N.L was a regular dental attendee.

4 to 5 Natal tooth that was extracted the day after she was born

Had fillings done on her upper and lower primary and permanent molars with L.A

Had upper partial denture previously

Oral Hygiene

Brushed twice a day in the morning and before sleep using kids toothpaste and manual toothbrush.

Diet

N.L likes a variety of food. Generally, she snacked on dried rice, biscuit and crisps.

She drank mainly water and orange juice.

Habits

No history of nail biting, thumb sucking or parafunctional activities.

Clinical Examination

Extra-Oral Examination (E/O)

A friendly young girl.

No skin abnormal pigmentation noted

No hair, nail, and finger malformations

No problems with vision and hearing

She functions very well developmentally

Symmetrical face.

No regional Lymphadenopathy.

Normal mouth opening with no temporomandibular joint abnormality.

Intra-Oral Examination (I/O)

Soft tissue (ST): -

NAD

Oral hygiene (OH): good (plaque index (PI): 33%).

Occlusion:

Class III molar relationship.

Rotated UR3 and UL2

Anterior open bite

Large edentulous space in the upper left and lower left region

Unilateral right side crossbite

Dentition:

Mixed dentition.

Teeth present as charted:

6	E	D	C	2	1		3	4	6	
7 [?]	6	E			B	1		C	E	6

Caries free

SSC LL6

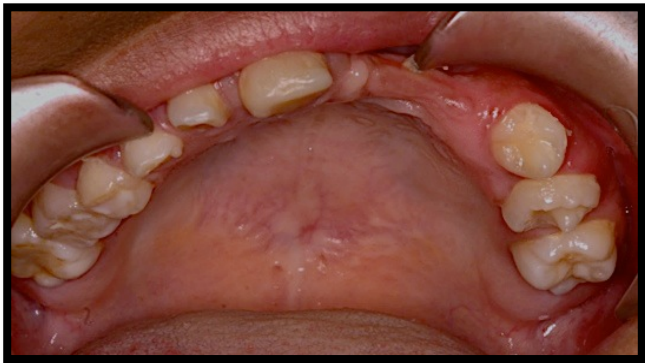
Composite Fillings

6	E	D
6		

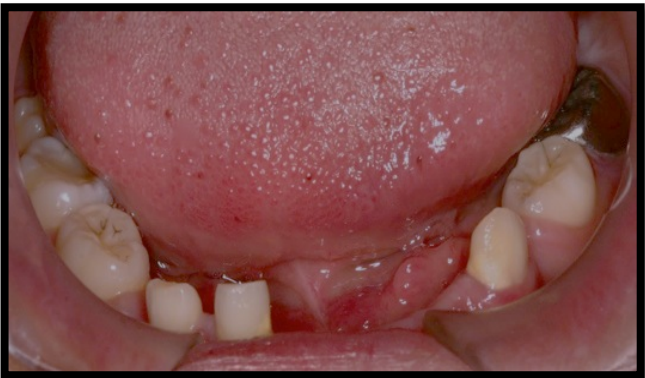Malformed permanent dentition

UR1 with deficient composite filling

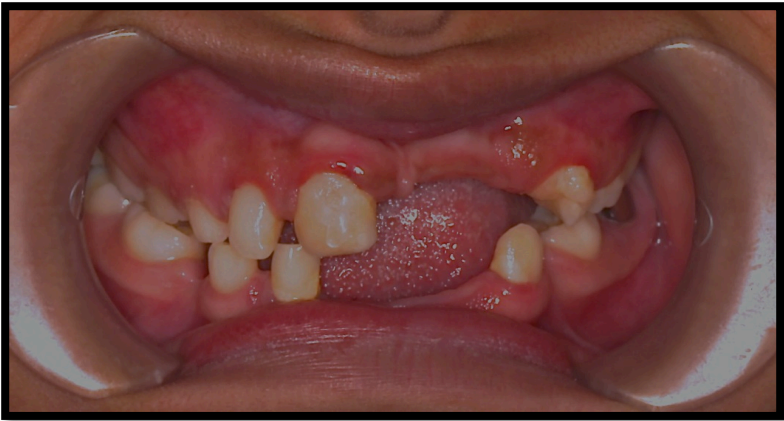Upper occlusal view



Lower occlusal view



Frontal view



Teeth present:

6	E	D	C	2	1	3	4	6
7 [?]	6	E		B	1	C	E	6

Missing teeth:

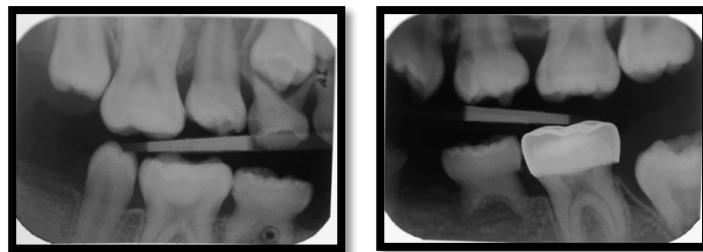
						1	2			
5	4	3	2			1	2	3	4	5

Pre-operative radiographs

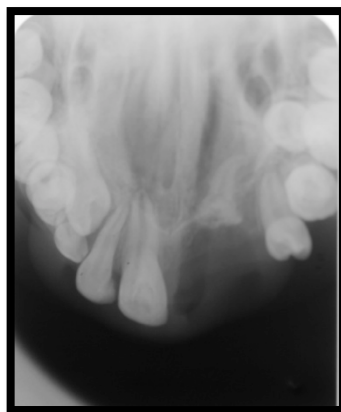
Orthopantogram
15/08/2013



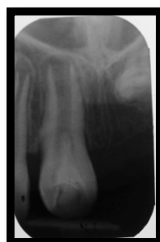Right and left bitewings



Upper anterior occlusal



Periapical



Diagnosis and Treatment Planning

Diagnosis

- Severe hypodontia secondary to Incontinentia pigmenti
- Malformed shape and form permanent dentition (Invaginated permanent dentition (UR1))
- Impacted UL5
- Malformed LR7
- Undeveloped UL1
- Under-developed alveolus bone in the upper and lower left segments

Treatment Objectives

- Restore function and aesthetics of dentition
- To establish and maintain good oral hygiene
- To provide dietary education to prevent dental caries
- Promote a positive attitude towards dental care

Provisional Treatment Plan

Immediate and preventive treatment

Liaise with GOSH regarding any medical concerns.

Prevention according to Delivering better oral health toolkit 2015

OHI.

Dietary education.

Fluoride varnish application (duraphat Fluoride varnish 2.26%) every 6 months.

Restorative and Prosthodontics (as planned in hypodontia clinic)

Adjustment of UR1

Stabilisation of present dentition:

6	E	D	C	2	1		3	4	6
7 [?]	6	E		B	1		C	E	6

Upper and lower removable partial dentures to restore occlusion and aesthetics

Maintenance and follow up

Clinical review every 6 months to monitor restorations, oral health and occlusion.

Reinforcement of dietary advice and OHI.

Annual reviews with hypodontia clinic for future planning

Treatment progress and dental management

Visit 1: 15/08/2013

Attended with her mother.

A complete medical and dental history was taken, with clinical examination

Appropriate X-rays examination was obtained.

A provisional treatment plan was formulated and discussed with the patient and her mother.

Hypodontia treatment plan to:

- Stabilise current dentition
- Restore defected upper anterior teeth
- Provide upper and lower RPD's
- Review annually for future treatment planning

Oral hygiene and diet advice given:

- Brush twice daily especially at night.
- Using toothpaste with minimum 1450ppm Fluoride prescription.
- Spitting after brushing rather than rinsing.
- Use mouthwash (.05% Fluoride) between brushing.

A letter to her consultants in GOSH was sent.

Pre-operative clinical photos obtained

Behaviour: very cooperative.

Visit 2: 09/09/2013

Attended with her mother.

C/O: Nil

MH: No change.

E/O: No abnormalities detected (NAD).

I/O: PI: 22%.

Treatment (TX):

Scaling and polishing

UR1:

Vitality test to confirm vitality of UR1

Under dry dam isolation:

Composite shade A1 used to repair the defected filling

Finishing and polishing

UR6, URE, URD, UL5, UL6, LRE, and LLE:

Cotton rolls isolation:

Fissure sealant on occlusal surface

OHLs given reinforcement

Fluoride varnish (Duraphat 2.26%) applied in her dentition.

Diet habits reinforced

Post-operative instructions (POIs).

Behaviour: cooperative.

Next appointment:

Primary impressions for upper and lower RPD's

Visit 3: 22/09/2013

Attended with her mother.

C/O: Nil

MH: No change.

E/O: No abnormalities detected (NAD).

I/O: PI: 11%.

Received a letter from her consultants in GOSH stating that there is no contraindication to dental treatment.

Treatment (TX):

Upper and lower alginate primary impressions to construct upper and lower special trays

Impressions disinfected and sent to the lab to construct upper and lower special trays

OHI

Behaviour: cooperative.

Next appointment:

Secondary impressions

Visit 4 02/10/2013:

Attended with her mother.

C/O: Nil

MH: No change.

E/O: NAD.

I/O: PI: 5%.

TX:

Upper and lower secondary silicone impressions using special trays constructed last visit

Bite registration

Secondary impressions disinfected and sent to the lab for constructing upper and lower removal partial dentures (RPD)

Shade selection (A1)

RPD design:

- Distal stops on upper and lower 6's

- Pontics to replace

			1	2	+/- 3
3	1		1	2	

- Shade A1

OHI and diet habits reinforced

Behaviour: cooperative.

Next visit:

Upper and lower RPD's wax-try in

Visit 5 17/10/2013

Attended with her mother.

C/O: Nil.

MH: No change.

E/O: NAD.

I/O: PI: 5%.

TX:

RPD wax try-in

Upper and lower wax dentures fit properly

Occlusion checked

Patient happy with teeth size, shape and colour

Denture sent for processing

OHI reinforced

Next visit:

Deliver upper and lower RPD's

Visit 6 14/11/2013

Attended with her mother, arrived 20 minutes late

C/O: Nil.

MH: No change.

E/O : NAD.

I/O: PI: 0%.

TX:

Upper and lower RPD's delivered

Adjustment made as required on both upper and lower dentures using adam's pliers

Dentures fit properly

Occlusion checked using articulating papers

Instruction over insertion, removal and maintenance of denture

OHI

Behaviour: cooperative.

Next visit:

Modify upper anterior teeth for better aesthetic results trying to mimic the acrylic teeth in the upper denture

Assess denture acceptance

Visit 7 28/11/2013:

Attended with her mother.

C/o: Nil.

MH: No change.

E/O: NAD.

I/O: PI: 0%.

TX:

Upper and lower dentures fit properly and N is getting used to it

Dry dam isolation.

UR2 and UR1: (shape modification)

- Composite shade A1 on labial surface

- Finishing and polishing

Occlusion checked

OHI

POIs.

Behaviour: cooperative.

Next visit:

Review N after 1 to 2 months to assess denture acceptance and maintenance

Visit 8 16/01/2014

Attended with her mother.

C/O: lower denture broken 1 week before the appointment during Christmas holiday while eating

MH: No change.

E/O: NAD.

I/O: PI: 5%.

TX:

- Laboratory contacted to fix broken lower denture
- Broken denture sent to the lab and arrangement for fixing done
- Denture maintenance instruction reinforced and emphasised

OHI

Behaviour: cooperative.

Next visit:

Deliver lower RPD

Visit 9 24/01/2014

Attended with her mother.

C/o: Nil.

MH: No change.

E/O: NAD.

I/O: PI: 0%.

TX:

Deliver lower RPD

Denture adjustment using adam's plier

Occlusion checked using articulating paper

POI's and denture maintenance reinforced

OHI

Post-operative photos

Behaviour: cooperative.

Next visit:

Review after 3 months

Visit 10 27/03/2014

Attended with her mother.

C/o: Nil.

MH: No change.

E/O: NAD.

I/O: PI: 0%.

TX:

Review of the upper and lower dentures

Fluoride application on all present dentition.

Patient is happy with dentures

OHI

Postoperative photos

Behaviour: cooperative.

Next visit:

Review after 6 months and consider hypodontia re-referral to update treatment plan if needed.

Visit 11 08/09/2014

Attended with her mother.

C/o: Nil.

MH: No change.

E/O: NAD.

I/O: PI: 0%.

TX:

Review of the upper and lower dentures

Minor adjustments of the UR1 and UR2

Arrange for re-referral to hypodontia clinic for further treatment planning.

Next visit:

Review after 6 months

Visit 12 07/01/2015 (in hypodontia clinic)

Attended with her mother.

Hypodontia clinic advised to:

- Monitor the impacted UL5 after 6 months from this appointment
- Review current restoration and refer back again after 1 year

Visit 13 07/03/2015

Attended with her mother.

C/o: Nil.

MH: No change.

E/O: NAD.

I/O: PI: 0%.

TX:

Review of the upper and lower dentures

Denture intact and patient happy

Next visit:

Review after 6 months

Visit 14 07/07/2015

Attended with her mother.

C/o: Nil.

MH: No change.

E/O: NAD.

I/O: PI: 0%.

TX:

Review of the upper and lower dentures / denture intact

Review the impacted UL5 and rotated UL3 (updated OPG)

Next visit:

Review and consider re-referral to hypodontia clinic for further future treatment planning.

Future Management

Clinical review every 6 months.

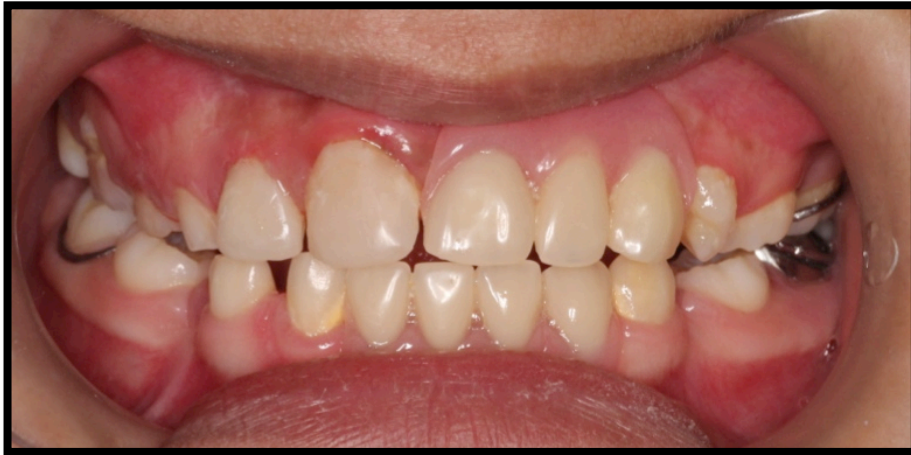Reinforcement of dietary advice and OHI.

Continuously liaise with GOSH for any medical consideration

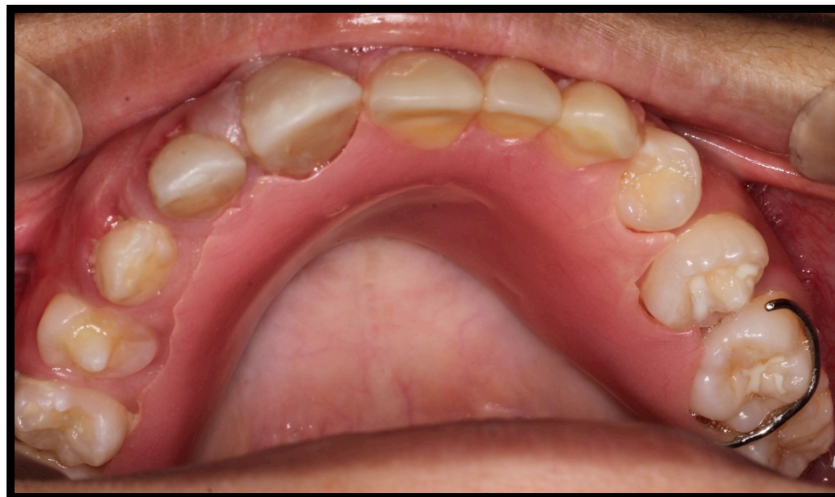Annual review with hypodontia clinic for future planning

Post-operative clinical photographs (07/07/2015)

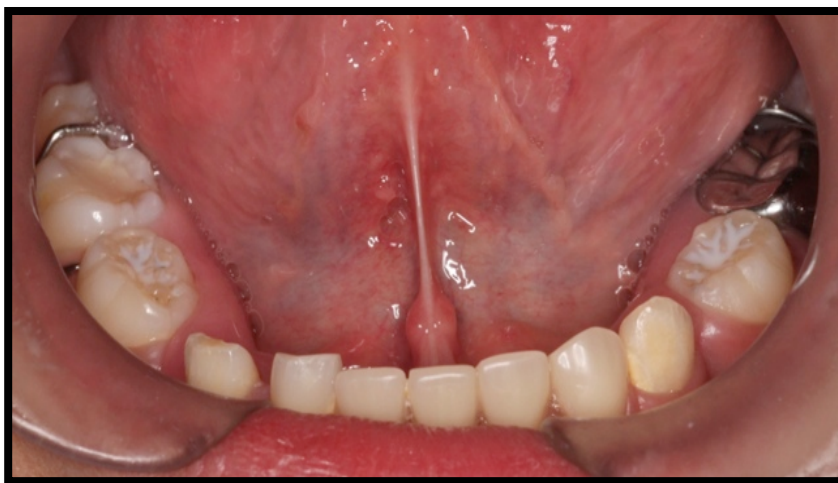Frontal view



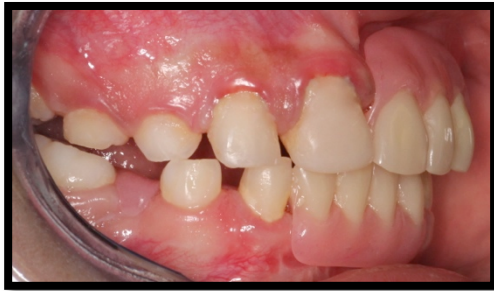Upper occlusal view



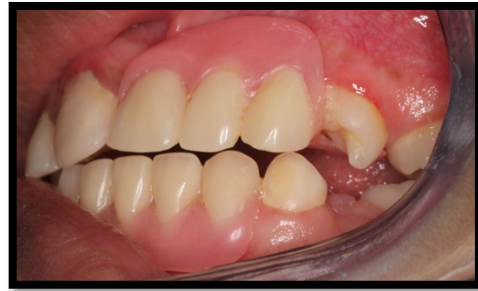Lower occlusal view



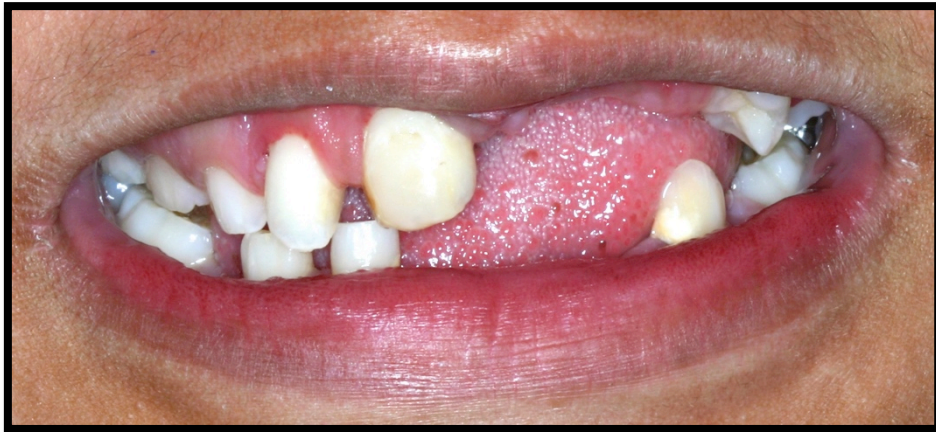Right side view



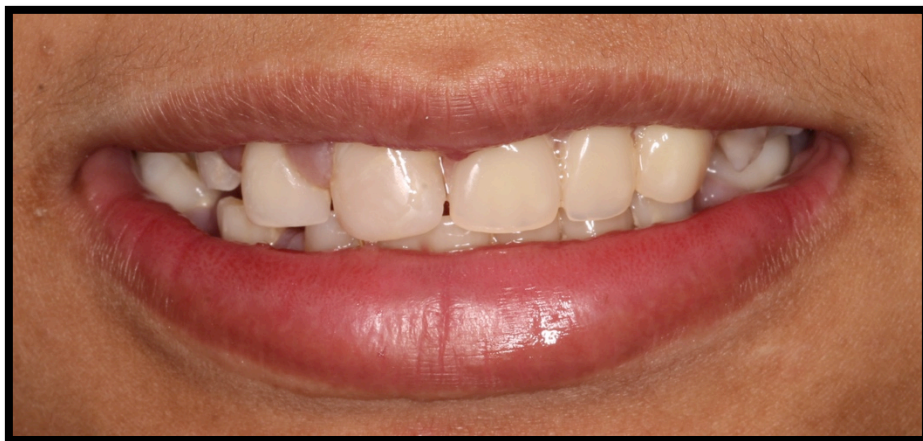Left side view



Pre-operative smile view

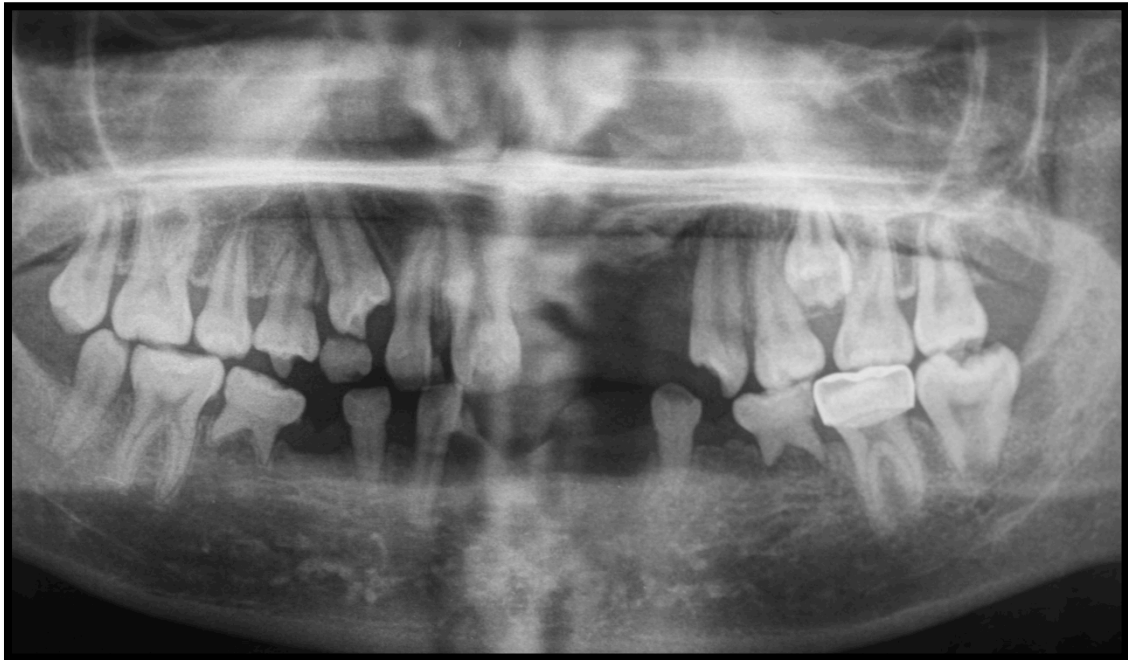

Post-operative smile view

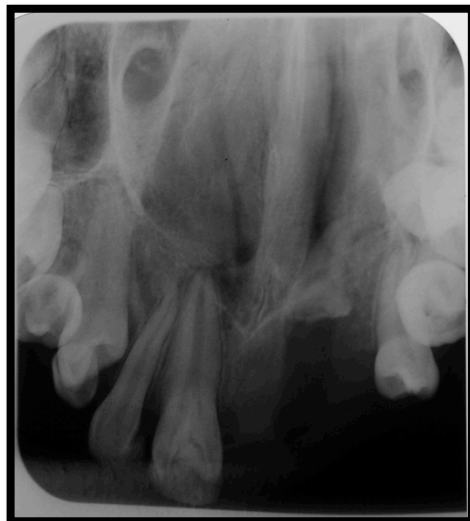

Post-operative radiographs (07/07/2015)

Orthopantogram



Upper anterior occlusal



Appraisal and Discussion

Incontinentia pigmenti (IP) is a rare X-linked dominant multi-systemic ectodermal disease that principally occurs in females. However, IP in men is considered lethal. A bullous rash along Blaschko's lines (BL) followed by verrucous plaques evolving over time to hyperpigmented swirling patterns is one main manifestation. Moreover, it is characterized by teeth abnormalities, alopecia, nails dystrophy and affects occasionally the retina and the central nervous system (CNS). Majority of IP cases are caused by mutations in the NEMO gene located in Xq28 locus that are responsible for 80% of the new mutations (Poziomczyk et al., 2014). As this mutation cause variable characteristics and expressions, cutaneous findings that follow a chronological sequence are main symptoms of the disease. Four clear stages of IP can occur: inflammatory or vesicular stage, verrucous stage, hyperpigmented stage, and hypopigmented stage.

As described in literature IP has major dental anomalies (Minić et al., 2013). For example, missing teeth, conical teeth, delayed eruption, and additional cusps in posterior teeth (Himelhoch et al., 1987).

N.L, a 10 years old girl, was diagnosed to have IP when she was 6 years old. On examination, N did not have skin abnormal pigmentation, hair, nail, and finger malformations, no problems with her vision and hearing was noted or reported by her consultants in GOSH. Though, she functions very well developmentally and mentally and no any medical concerns were received in her medical report.

N main dental anomalies and findings were:

1. Hypodontia
2. Malformed teeth
3. Invaginated permanent dentition (UR1)
4. Undeveloped tooth (UL1)
5. Impacted teeth and malocclusion
6. Under-developed alveolus bone in the upper and lower left segments
7. Natal teeth (extracted second day of her birth)

Hypodontia, is defined as the congenital absence of one or more teeth and it is more common in permanent teeth, around 3.5-6.5% in the Caucasian population. However, the prevalence is lower in deciduous dentition, ranging between 0.1-0.9%. It occurs in equal frequency in both jaws. The incidence in male to female ratio is 2:3 (Sundram and Walmsley, 2002). The cause of hypodontia is not yet certain, but the disturbance and disruption in tooth mesenchyme signalling during tooth development can be an explanation.

The reason of missing teeth can be classified into local and general causes. N's general reason was the IP ectodermal disease that was expressed orally by her missing teeth. N was referred to the hypodontia clinic for proper treatment planning and management. This is to gain from the benefit of the idea of multidisciplinary and interdisciplinary management of young people with hypodontia (Nunn et al., 2003). N alveolar ridges were under-developed because another common feature of hypodontia is a relative lack of alveolar growth due to missing teeth.

The invaginated teeth (dens invaginatus) is a rare dental anomaly with an incidence of 0.04-10%. It is basically deepening of the cingulum as a result of the infolded enamel and dentine. Maxillary lateral incisors are the most common affected teeth. Also, it can occur in other maxillary teeth such as central incisors, canines, premolars and molar teeth. Usually invaginated teeth are asymptomatic but morphologically abnormal. N did not report any clinical symptoms, but preventive treatment was necessary to prevent bacterial infiltration between the invagination that can lead to pulpitis. So, the UR1 was already restored with a deficient composite filling that needed addition and modifications (Vaidyanathan et al., 2008).

The aetiology of dens invaginatus is still unknown. In fact, tooth morphogenesis is affected by the ectomesenchymal signalling systems that occur between the internal enamel epithelium and the dental papilla during tooth development. These signals regulate growth and the folding process of the enamel organ. Problems in these signals can result in abnormally shaped teeth as well as defects in the developing tooth (Alani and Bishop, 2008). In N's situation her ectodermal disease (IP) may have a significant correlation with this teeth abnormality.

Treatment aims were to preserve the remaining teeth, restore function and aesthetics of dentition, to establish and maintain good oral hygiene, to provide dietary education to prevent dental caries, and to promote a positive attitude towards dental care. N's

attitude toward dental treatment was very helpful and she was very cooperative during all treatment sessions.

Preventive

N's oral hygiene was very good and this was stable during all the visits. So, a preventive regimen according to the Department of Health tool kit (Department of Health, 2009) was given to maintain good oral hygiene, preserve dentition and prevent dental caries. In addition, N was informed to use adults' toothpaste instead of children's toothpaste. Fluoride varnish will be applied professionally every 6 months and awareness of the potential for wear of retained primary teeth was also provided.

Restorative and prosthodontics:

Composite fillings were necessary to preserve the malformed UR1 and modify the shape of UR2. In addition, a treatment plan by hypodontia clinic agreed to provide N with upper and lower removable partial dentures. This is to provide her with intermediate restorations before definitive care. The indication of it is to improve aesthetics, enable her to eat wide range of foods, improve speech, promote emotional and psychological well-being, and to ease her transition into adolescent (Nunn et al., 2003).

Maintenance

N.L will be reviewed every 6 months to monitor oral health and review the integrity of the fillings and the provided prosthesis, and reinforcement of dietary advice and OHI (Department of Health, 2009). Radiographic review will be every 12-18 months as needed (SDCEP, 2010).

N was given post insertion denture instructions for maintaining the denture and optimising good denture care.

N will be reviewed annually with the hypodontia clinic for future treatment planning. Also patients with IP have poor teeth positioning and loss of the vertical occlusion dimension, accompanying hypodontia, so orthodontic consideration is very important as they show more possibility of dental malocclusion. (Poziomczyk et al., 2014). Thus an orthodontic opinion regarding her impacted UL5, rotated teeth, and unilateral right side crossbite will also be considered in her treatment plan in the hypodontia clinic.

A regular update from her consultants in GOSH is also important to confirm if any medical concerns are needed in future treatments.

In the appraisal, N.L. was happy with the outcome and motivated during the treatment. Providing her with the prosthesis improved her life style and own perception. It was really rewarding to see her and her mother satisfied.

References

- ALANI, A. & BISHOP, K. 2008. Dens invaginatus. Part 1: classification, prevalence and aetiology. *International endodontic journal*, 41, 1123-1136.
- DENTISTRY, D. OF H. AND THE B.A. FOR THE S. of C., 2009. Delivering Better Oral Health An evidence-based toolkit for prevention - second edition.
- HIMELHOCH, D. A., SCOTT, B. & OLSEN, R. 1987. Dental defects in incontinentia pigmenti: case report. *Pediatr Dent*, 9, 236-9.
- MINIĆ, S., TRPINAC, D., GABRIEL, H., GENCIK, M. & OBRADOVIĆ, M. 2013. Dental and oral anomalies in incontinentia pigmenti: a systematic review. *Clinical oral investigations*, 17, 1-8.
- NUNN, J., CARTER, N., GILLGRASS, T., HOBSON, R., JEPSON, N., MEECHAN, J. & NOHL, F. 2003. The interdisciplinary management of hypodontia: background and role of paediatric dentistry. *British dental journal*, 194, 245-251.
- POZIOMCZYK, C. S., RECUERO, J. K., BRINGHENTI, L., MARIA, F. D. S., CAMPOS, C. W., TRAVI, G. M., FREITAS, A. M., MAAHS, M. A. P., ZEN, P. R. G. & FIEGENBAUM, M. 2014. Incontinentia pigmenti. *Anais brasileiros de dermatologia*, 89, 26-36.
- SCOTTISH DENTAL CLINICAL EFFECTIVENESS PROGRAMME, 2010. Prevention and Management of Dental Caries in Children. Available at: <http://www.sdcep.org.uk/index.aspx?o=2332> [Accessed June 17, 2012].
- SUNDRAM, F. & WALMSLEY, A. 2002. The management of severe hypodontia in a young adult patient: a case report. *Dental update*, 30, 326-330.
- VAIDYANATHAN, M., WHATLING, R. & FEARNE, J. 2008. An overview of the dens invaginatus with case examples. *Dental update*, 35, 655-6, 658-60, 662-3.



CASE REPORT

Case 3:

Management of dento-alveolar Trauma (Paediatric Dentistry Advanced Clinical Care 3)

**In partial fulfilment of the degree
Clinical Doctorate in Paediatric Dentistry
Eastman Dental Institute
University College London
2012 - 2015**

Submitted by

Lama Dakkouri

DDS (Jordan), MFD (Ireland)

Contents

CONTENTS.....	II
CASE SUMMARY	III
PRE-OPERATIVE CLINICAL PHOTOGRAPHS (23/09/2013)	IV
PRE-OPERATIVE RADIOGRAPH (23/09/2013)	V
POST-OPERATIVE CLINICAL PHOTOGRAPH AND RADIOGRAPH	VI
CASE HISTORY.....	1
PERSONAL DATA:.....	1
REASON FOR REFERRAL:	1
CHIEF COMPLAINT (C/O)	1
HISTORY OF COMPLAINT	1
MEDICAL HISTORY (MH).....	1
FAMILY HISTORY	2
SOCIAL HISTORY	2
DENTAL HISTORY	2
ORAL HYGIENE.....	2
DIET	2
HABITS	2
CLINICAL EXAMINATION.....	3
EXTRA-ORAL EXAMINATION (E/O)	3
INTRA-ORAL EXAMINATION (I/O)	3
PRE-OPERATIVE RADIOGRAPHS	5
DIAGNOSIS AND TREATMENT PLANNING.....	6
DIAGNOSIS:.....	6
TREATMENT OBJECTIVES	6
PROVISIONAL TREATMENT PLAN.....	6
TREATMENT PROGRESS AND DENTAL MANAGEMENT	7
VISIT 1 23/09/2013	7
VISIT 2 30/09/2013	7
VISIT 3 23/10/2013:	9
VISIT 4 20/01/2015	10
VISIT 5 16/04/2014	12
VISIT 6 05/05/2014	14
POST-OPERATIVE CLINICAL PHOTOGRAPHS UPON TREATMENT COMPLETION (05/05/2014).....	15
VISIT 7 17/06/2014	16
VISIT 7 10/12/2015	17
VISIT 8 11/03/2015	18
VISIT 9 8/07/2015	19
POST-OPERATIVE CLINICAL PHOTOGRAPHS (08/07/2015)	21
APPRAISAL AND DISCUSSION.....	22
REFERENCES	25

Case summary

A.K is a 12-year old boy, fit and healthy who suffered a trauma to his teeth while he was playing hockey game for Harrow County. This accident resulted in an avulsion of UL1 in addition to lip swelling and gum laceration. He was immediately transferred to North Wick Hospital and had his tooth re-implanted and splinted with maxillofacial and ligature splint. Tooth kept in milk for more than 2 hours.

A.K presented to EDH 24 hours following the trauma, when he presented with swelled and lacerated lips and gum. A's main complaint was that he lost his front tooth while playing hockey game.

Upon examination, UL1 was re-implanted and splinted with a maxillofacial and ligature splint.

Treatment was carried out under local anaesthesia (LA) and in conjunction with non-pharmacological behaviour management (NPBM) techniques.

Treatment provided:

1- Emergency (Immediate):

- Verify position of re-implanted UL1
- Apply a flexible dental splint for up to 4 weeks
- Antibiotics prescription (already on antibiotics)
- CHX and analgesics prescription
- Check tetanus protection
- Give patient instructions (soft diet and gentle tooth brushing)
- Explain treatment options and long-term prognosis

2- Intermediate:

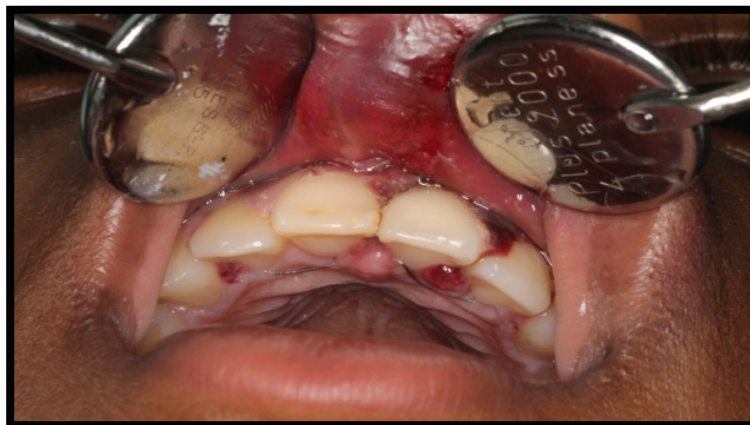
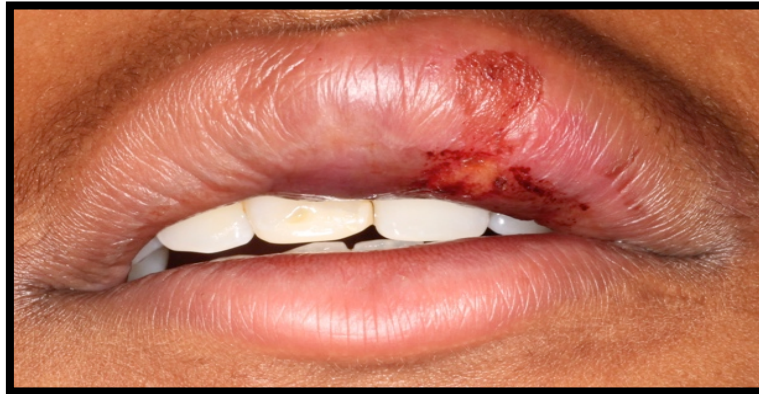- Remove ligature splint applied by maxillofacial
- Initiate root canal treatment 7–10 days before dental splint removal
- Remove dental splint after 4 weeks
- Explain the possible outcome and poor prognosis

3- Long Term:

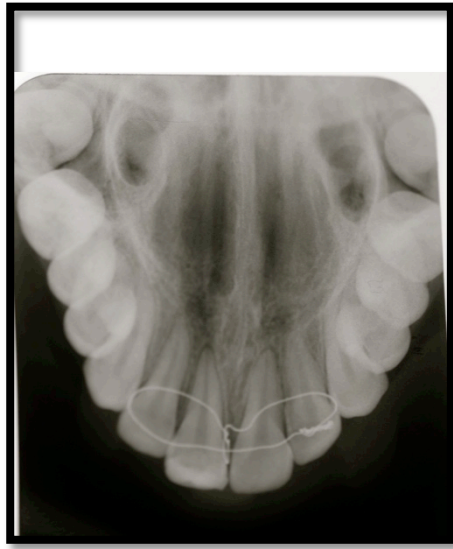- Monitor the vitality of UL2, UR1 and UR2
- Obturate UL1
- Monitor UL1
- Explain the possible replacement options if poor outcomes in UL1

Pre-operative clinical photographs (23/09/2013)

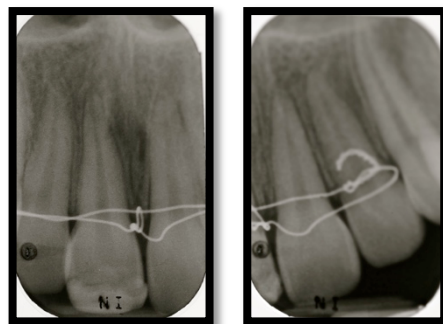
Frontal views



Pre-operative radiograph (23/09/2013)



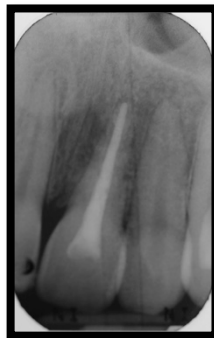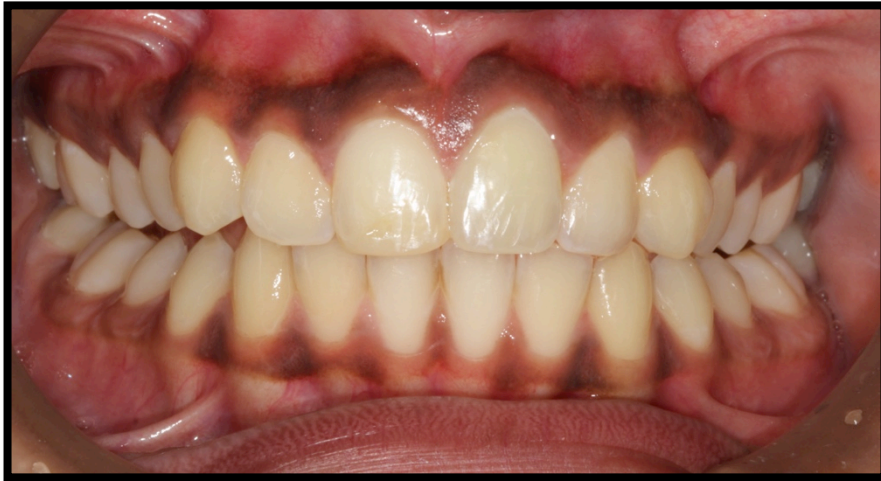Upper anterior occlusal radiograph



Long-cone periapicals

Post-operative clinical photograph and radiograph

Frontal view (08/07/2015)



**Pot-operative long-cone periapical
08/07/2015**

Case History

Personal data:

A.K.

Male.

Date of Birth: 05/05/2001.

Referred by: GDP.

Date of first attendance: 23/09/2013.

Age at presentation: 12 years and 4 month.

Reason for referral:

He was referred by GDP regarding avulsion of his UL1

Chief Complaint (C/O)

- Lost his upper front teeth while playing hockey game

History of Complaint

When: 22/09/2013 11:30a.m.

How:

- Knocked by friend's hockey stick during the game
- One tooth pulled out.
- Accidentally by his friend.

Action:

- Was taken to North Wick Hospital.
- Stored the avulsed tooth (UL1) in milk for more than 2 hours

At North Wick Hospital:

- Re-implanted UL1 (after 2 hours in milk)
- Maxillofacial and ligature splint applied around the UL1

Where: outdoor

Other symptoms: headache

Medical History (MH)

He is a fit and healthy young man who was born full-term with x-section delivery. His immunisations were up-to-date and did not suffer any early childhood illnesses.

Family History

No family history of any dental abnormalities.

Social History

He has one younger sister (9 years) and one younger brother (6 years).

He attends main stream school.

Dental History

A was a regular attendee to his GDP 6-monthly. He had previous trauma (uncomplicated crown fracture) when he was 7 years old on his UR1 while playing sports.

Oral Hygiene

He brushes twice daily with adult's toothpaste and a manual toothbrush.

Diet

He was a good eater and liked a variety of food. Occasionally consumed sweets and crisps between meals and mainly drinks water.

Following the trauma, he was on soft diet only.

Habits

No history of nails biting, thumb sucking or para-functional activities.

Clinical Examination

Extra-Oral examination (E/O)

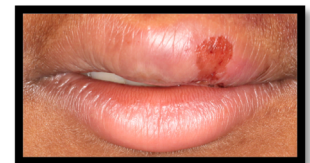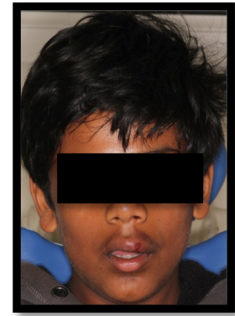Maxilla and mandible (NAD).

TMJ (N/A) but difficulty in mouth opening due to swelled upper lip

Lymph nodes (NAD)

Soft tissue:

- Swelled and abraded upper lip



Intra-Oral examination (I/O)

Soft tissue (ST):

- Swelling on the labial vestibule of the upper lip.
- Abrasion in the upper labial mucosa
- Abrasion and contusion in the upper anterior gingivae and around upper front teeth
- Abrasion and laceration in palatal gingivae
- Swelled interdental papilla
- Labial and palatal ligature splint present from UL2 to UR2

Oral hygiene (OH):

Good (plaque index (PI): 17%) (Simplified oral hygiene index by Green and Vermilion 1964).

Occlusion:

Permanent molar relationship: class I on the right and left sides.

Class I incisor relation

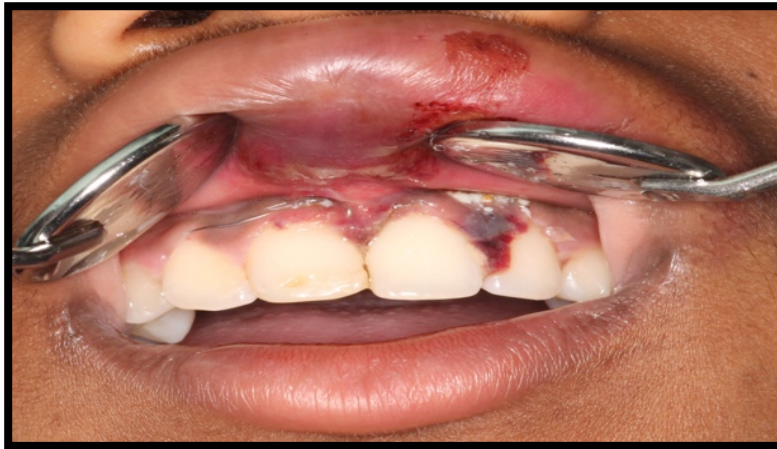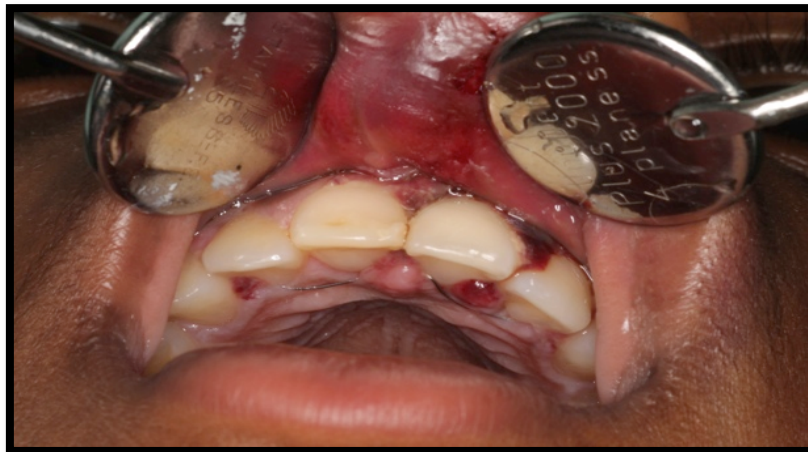Dentition:

Re-implanted avulsed UL1 in socket with ligature splint around soft tissue labially and palatally

Composite filling in the incisal area of UR1

Trauma findings:

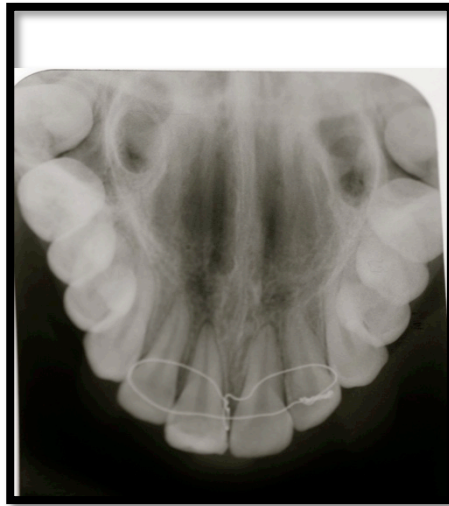Splint (ligature) from UL2 to UR2.

Frontal view**Upper ligature suture****Teeth present:**

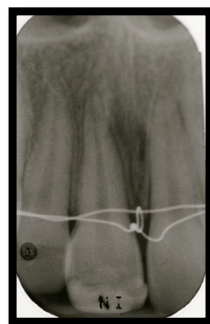6	5	4	3	2	1		1	2	3	4	5	6
6	5	4	3	2	1		1	2	3	4	5	6

Pre-operative radiographs

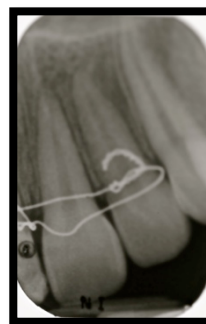Upper Anterior Occlusal
23/09/2013



Right and left PA's



Right



Left

Findings:

UL1 replanted in socket and ligature splint wires present
No root fracture, no periapical pathology or alveolar fracture
Closed apex in UL1
Mature roots of UR2, UR1, UL1 and UL2.
Composite filling on UR1

Diagnosis and Treatment Planning

Diagnosis:

Soft tissue trauma:

- Lip laceration and abrasion
- Labial mucosa and gingivae abrasion and contusion

Periodontal tissue trauma:

- Re-implanted avulsed UL1 with closed apex (more than 60 min)

Treatment Objectives

Remove source of infection and extirpate the upper UL1.

To preserve and maintain the traumatised UL1 to preserve bone

To restore function and aesthetic.

Prevent/ manage the sequelae of the trauma as appropriate.

Provisional Treatment Plan

1- Emergency (Immediate):

- Verify position of re-implanted UL1
- Apply a flexible dental splint for up to 4 weeks
- Antibiotics prescription (A.K already under antibiotics prescribed by his GDP)
- CHX and analgesics prescription
- Check tetanus protection
- Give patient instructions (soft diet and gentle tooth brushing)
- Explain treatment options and long term prognosis

2- Intermediate:

- Remove ligature splint applied by maxillofacial
- Initiate root canal treatment 7–10 days and before dental splint removal
- Remove dental splint after 4 weeks
- Explain the possible outcome and poor prognosis

3- Long Term:

- Monitor the vitality of UL2, UR1 and UR2
- Root canal obturation of UL1
- Explain the possible replacement options if poor outcomes in UL1

Treatment progress and dental management

Visit 1 23/09/2013

- Patient attended with Dad in an emergency appointment
- Cooperative, sits on dental Chair

Treatment (TX):

Trauma history and perfroma done

Gentle clinical examination as patient in pain and it shows:

Re-implanted UL1 and ligature splint on labially and palatally soft tissue

Soft tissue trauma

Radiographical examination to verify re-implanted UL1

UL1 splinted dentally from UR1 to UL2 using wire and composite splint

Photos taken

Patient to be seen after 7 days to start RCT in UL1 and remove the ligature splints (when traumatised soft tissue heals)

Visit 2 30/09/2013

- Patient attended with his Dad

M.H: NAD

D.H: NAD

C/C: Nil

Healed soft tissue trauma

Both splints in place

Proper history and examination of oral condition

Photos taken

Extra Oral Examination:

- Healed soft tissue trauma
- No facial asymmetry
- LN/TMJ: NAD

Intra Oral Examination:

S.T: NAD (wax to cover the ligature splint in the upper left labial mucosa)

PI:0%.

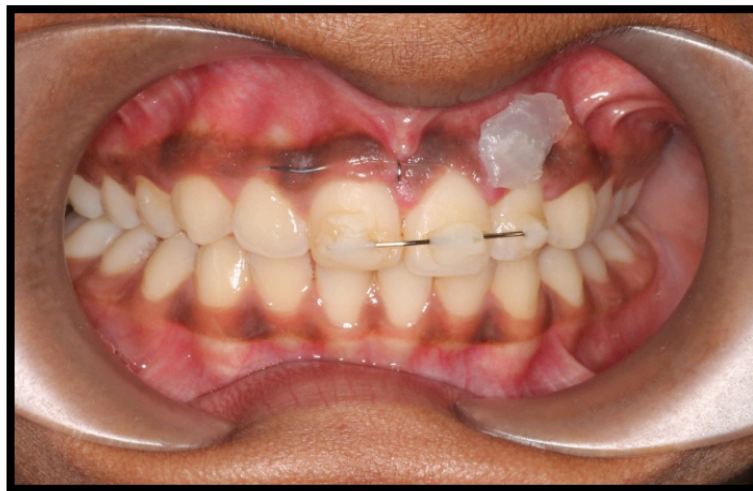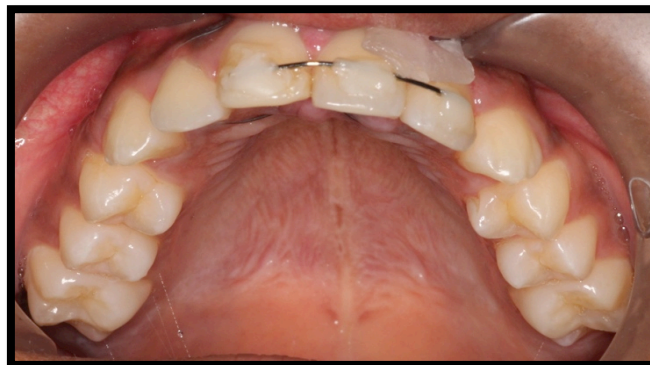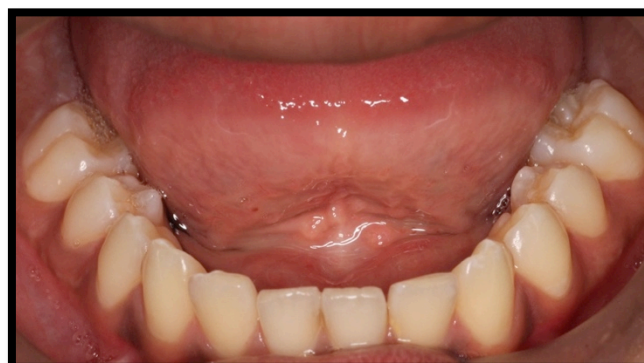Dentition:

- Splinted avulsed UL1
- Teeth presented as charted
- Caries free

6	5	4	3	2	1		1	2	3	4	5	6
6	5	4	3	2	1		1	2	3	4	5	6

Occlusion:

- Class I incisor relation
- Class I Molar relation L and R

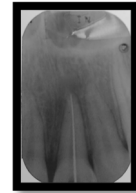Anterior view**Upper occlusal view****Lower occlusal view**

Txt: remove maxillofacial splint and start RCT on UL1

- Topical Benzocaine 20% on upper anterior mucosa
- LA: Lidocaine 1:80,000 adrenaline infiltration of upper anterior mucosa
- Maxillofacial splint removed using orthodontic cutters
- Dry dam isolation from UR2 to UL2

RCT started on UL1

- Access cavity preparation (palatal).
- Removal of pulp tissue (necrotic).
- Canal irrigation with sodium hypochlorite (0.5%).
- X-ray was taken with a size 40 K-files to determine WL
- WL determination (UL1= 23.5mm).
- Drying of the canal using paper points size 60.
- Minimal canal preparation
- Non-setting calcium hydroxide dressing (CaOH), Ultracal used for canal dressing.
- Cotton pledget + temporary filling (IRM) used to close the access cavity.



Working length
PA

Post-operative instructions to avoid heavy sports

Behaviour: cooperative.

Next appointment:

After 2 to 3 weeks to remove dental splint on UL1 and change Ca(OH) on the UL1

Visit 3 23/10/2013:

- Patient attended with his Dad

M.H and D.H checked

E/O: NAD.

I/O: PI:0%.

C.C: Nil

Txt:

- Removal of the dental splint on UL1
- Change calcium hydroxide on UL1
 - Removal of temporary filling and cotton pledget
 - Canal irrigation with sodium hypochlorite (0.5%).
 - Drying of the canal using paper points size 60.

- Canal preparation.
- Non-setting calcium hydroxide dressing (CaOH), Ultracal used for canal dressing.
- Cotton pledget + IRM used to close the access cavity
- Monitor UR2, UR1 and UL2 vitality

Test	Tooth			
	UR2	UR1	UL1	UL2
EPT	+22	+40	-	+36
E.C.	+	+	-	+
Colour	-	-	-	-
TTP	-	-	-	-
Mobility	-	-	mild	-
Tenderness in the sulcus	-	-	-	-
Sinus	-	-	-	-
Percussion sound	-	-	-	-

- Emphasize on patients instruction to avoid excessive sports
- Vitality tests findings:
 - Vital UR2 UR1 UL2
 - Non-vital UL1 (RCT)
 - Mild mobility on UL1

Behaviour: cooperative.

Next appointment:

Proceed in RCT of UL1 and assess mobility and ankylosis of UL1.

(Consider mouthguard construction next appointment)

Visit 4 20/01/2015

- Patient attended with his Dad

M.H and D.H checked

E/O: NAD.

I/O: PI:0%.

C.C: Nil

Txt:

Change calcium hydroxide on UL1

- Removal of temporary filling and cotton pledget
- Canal irrigation with sodium hypochlorite (0.5%).
- Drying of the canal using paper points size 60.
- Canal preparation.
- Non-setting calcium hydroxide dressing (CaOH), Ultracal used for canal dressing.
- Cotton pledget + IRM used to close the access cavity

Monitor UR2, UR1 and UL2 vitality

Test	Tooth			
	UR2	UR1	UL1	UL2
EPT	+33	+42	-	+45
Ethyl Chloride	+	+	-	+
Colour	-	-	-	-
TTP	-	-	-	-
Mobility	-	-	-	-
Tenderness in the sulcus	-	-	-	-
Sinus	-	-	-	-
Percussion sound	-	-	-	-

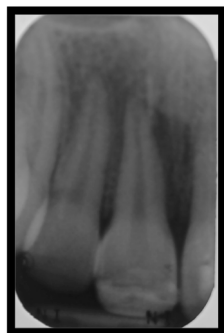Vitality tests findings:

- Non-vital (RCT) UL1
- Vital UR2 UR1 UL2

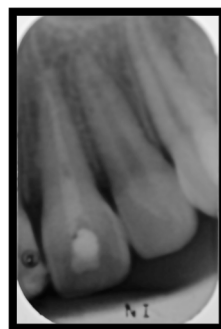
Alginate impression to construct sport guard (posted to patient)

- PA's to both upper centrals taken

Radiographs:



Right PA



Left PA

Findings:

- No any significant pathology noted related to UL1
- Mature apex in UR2 UR1 UL2 and UL1
- Calcium hydroxide to the full working length in UL1

Behaviour: cooperative.

Next appointment:

Reviewed in 3 months to assess barrier and proceed in RCT

Visit 5 16/04/2014

- Attended with his father

C/O: Nil.

MH: No change.

E/O: NAD.

I/O: PI:0%.

TX:

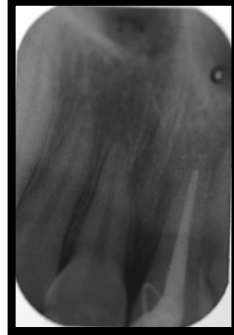Monitor UR2 UR1 UL2 vitality

Test	Tooth			
	UR2	UR1	UL1	UL2
EPT	+38	+41	-	+43
Ethyl Chloride	+	+	-	+
Colour	-	-	-	-
TTP	-	-	-	-
Mobility	-	-	-	-
Tenderness in the sulcus	-	-	-	-
Sinus	-	-	-	-
Percussion sound	-	-	-	-

UL1: (obturation)

- Dry dam isolation
- Removal of temporary filling and cotton pledget from access cavity.
- Canal irrigation with sodium hypochlorite (0.5%).
- Drying of the canal using paper points size 60.
- Barrier felt.
- Canal prepared

- Canal was obturated with GP and canal sealer (zinc oxide eugenol, Roth canal cement, Roth international LTD, Chicago, USA) using lateral condensation technique.
- Cotton pledget + IRM used to close access cavities of UL1.



PA pre-obturation (cone fit stage)

Findings:

- Homogenous obturation to full working length in UL1
- No any apical pathology related to UR2 UR1 UL1
- Matures apexes in UR2 UR1 UL1
- No any bony pathology

POIs.

Behaviour: cooperative.

Next visit:

Composite filling on access cavity of UL1

Visit 6 05/05/2014

- Attended with his mother

C/O: Nil.

MH: No change.

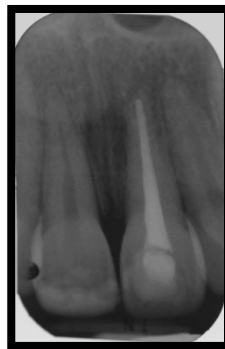E/O: NAD.

I/O: PI:0%.

TX:

UL1: composite filling of access cavity

- Dry dam isolation
- Removal of temporary filling and cotton pledget from access cavity.
- Removal of excess gutta percha from pulp chamber
- Glass ionomer cement (fuji IX) as a base on top of gutta percha
- Composite shade A1 on the palatal surface of UL1
- Finishing and polishing of composite filling
- Post operative radiograph



- PA post-obturation

Behaviour: cooperative.

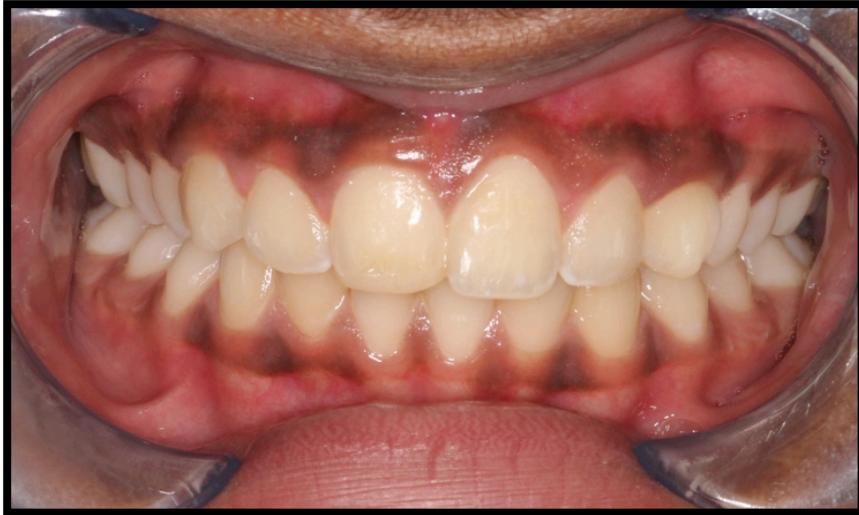Post-operative photos

Next visit:

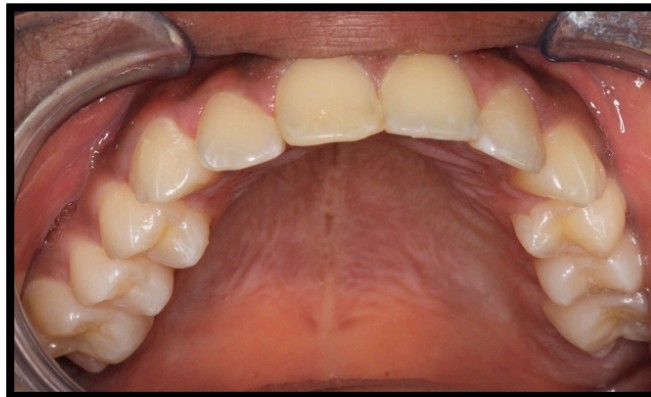After 6- 8 weeks review of UL1 for any significant pathology and monitor the vitality of UL2 UR1 UR2

**Post-operative clinical photographs upon treatment completion
(05/05/2014)**

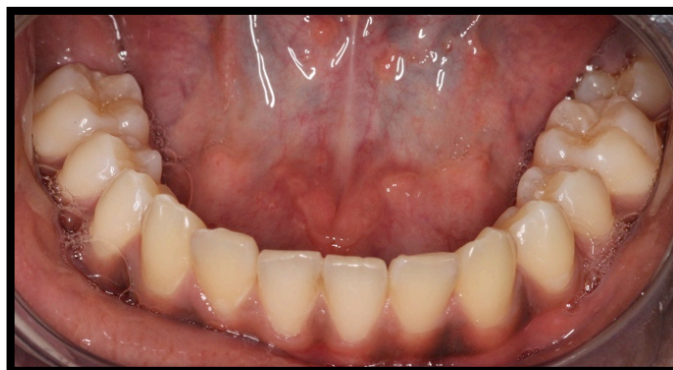Frontal view



Upper occlusal view



Lower occlusal view



Visit 7 17/06/2014

- Attended with his mother

C/O: Nil.

MH: No change.

E/O: NAD.

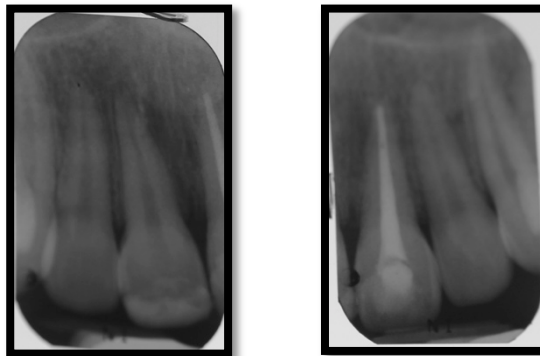
I/O: PI:0%.

TX:

Monitor UR1 UR2 UL2 vitality: (no any significant findings)

Test	Tooth			
	UR2	UR1	UL1	UL2
EPT	+42	+44	-	+46
Ethyl Chloride	+	+	-	+
Colour	-	-	-	-
TTP	-	-	-	-
Mobility	-	-	-	-
Tenderness in the sulcus	-	-	-	-
Sinus	-	-	-	-
Percussion sound	-	-	-	-

- Clinical and radiographical review.



Long cone periapicals with no any significant findings

Next visit:

After 6 months review of UL1 for any significant pathology and monitor the vitality of UL2 UR1 UR2

Visit 7 10/12/2015

- Attended with his mother

C/O: Nil.

MH: No change.

E/O: NAD.

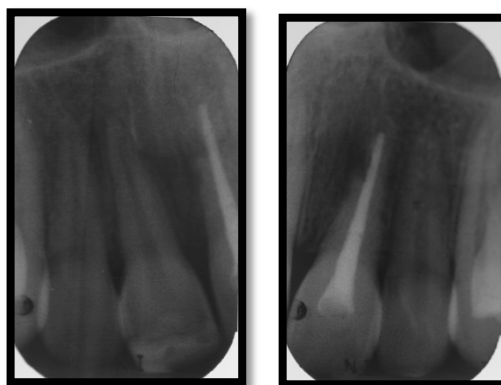
I/O: PI:0%.

TX:

- Clinical and radiographical review.
- Vitality tests for UR2 UR1 UL2 (no any significant findings)

Test	Tooth			
	UR2	UR1	UL1	UL2
EPT	+49	+41	-	+44
Ethyl Chloride	+	+	-	+
Colour	-	-	-	-
TTP	-	-	-	-
Mobility	-	-	-	-
Tenderness in the sulcus	-	-	-	-
Sinus	-	-	-	-
Percussion sound	-	-	Mild metallic	-

- New PA takes and radiolucency related to UL1 noted.



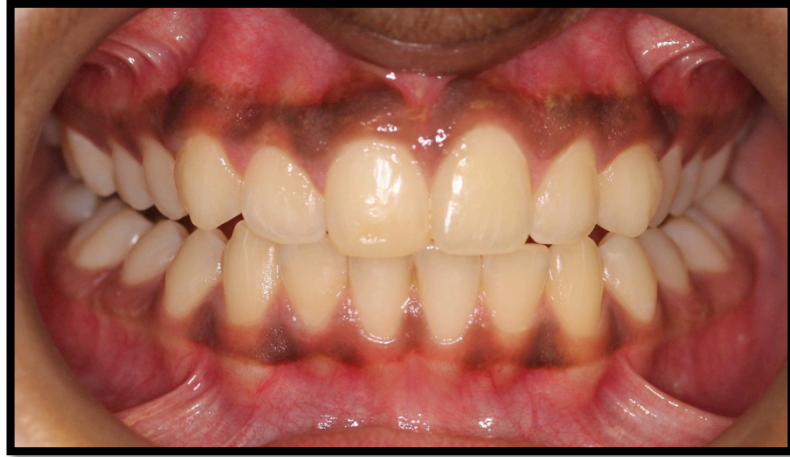R

L

Radiographical findings:

Radiolucency related to UL1

- Patient informed and treatment plan agreed to review and monitor the radiolucency related to UL1.
- Clinical photos to monitor UL1 gum line



Frontal view

Next visit:

After 3 months review UL1 radiolucency and monitor the vitality of UL2 UR1 UR2

Visit 8 11/03/2015

- Attended with his father

C/O: Nil.

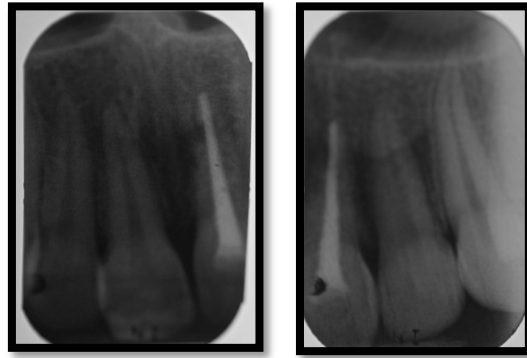
MH: No change.

E/O: NAD.

I/O: PI:0%.

TX:

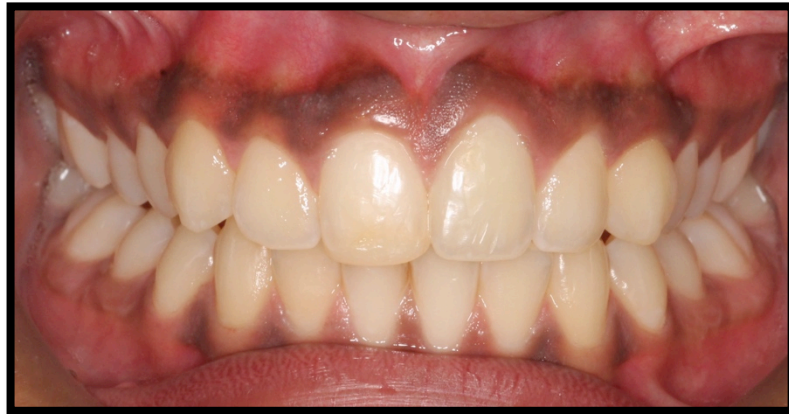- Clinical and radiographical review of UL1
- Vitality tests for UR2 UR1 UL2 (no any significant findings)
- Endodontic consultation regarding the radiolucency related to UL1 taken, advise is to monitor the radiolucency and act to replace the GP with Ca(OH)_2 if aggressive active inflammation is noted
- New PA taken to monitor the radiolucency related to UL1

**R****L**

Radiographical findings:

Radiolucency related to UL1

- Clinical photos to monitor UL1 gum line



Frontal view

Next visit:

After 4-6 months review UL1 radiolucency and monitor the vitality of UL2 UR1 UR2

Visit 9 8/07/2015

- Attended with his mother

C/O: Nil.

MH: No change.

E/O: NAD.

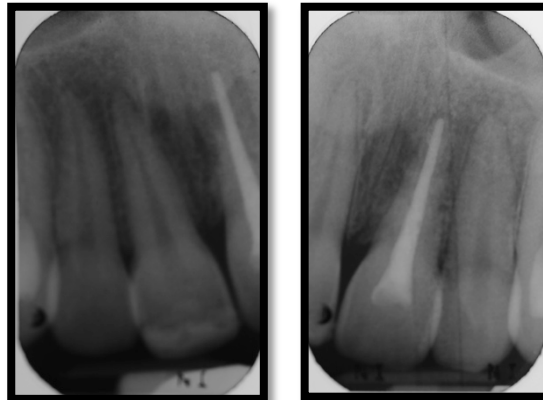
I/O: PI:0%.

TX:

- Clinical and radiographical review of UL1
- Vitality tests for UR2 UR1 UL2 (no any significant findings)

Test	Tooth			
	UR2	UR1	UL1	UL2
EPT	+48	+45	-	+42
Ethyl Chloride	+	+	-	+
Colour	-	-	-	-
TTP	-	-	-	-
Mobility	-	-	-	-
Tenderness in the sulcus	-	-	-	-
Sinus	-	-	-	-
Percussion sound	-	-	Mild metallic	-

- New PA taken to monitor the radiolucency related to UL1



R

L

Radiographical findings:

Lateral radiolucency related to UL1 is replaced by bone reposition and a possibility of replacement resorption instead of inflammation resorption started.

Next visit:

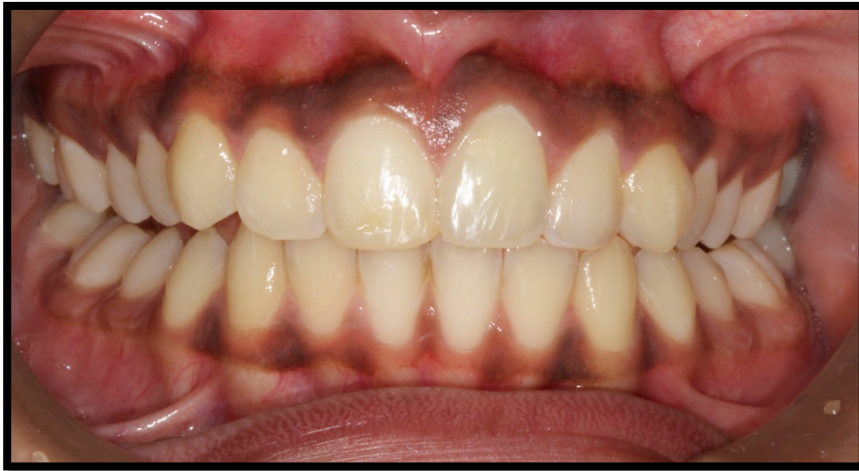After 6 months review UL1 and monitor the vitality of UL2 UR1 UR2

Future management:

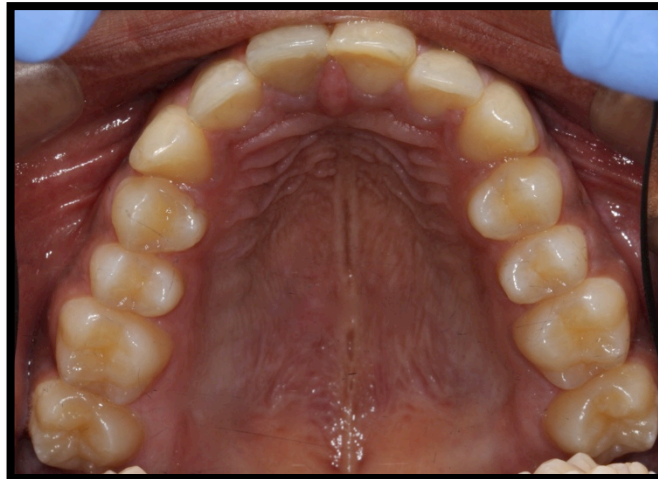
- Monitor UL1
- Discussion of treatment options if poor prognosis of UL1
- Clinical and radiographic follow-up for 5 years.

Post-operative clinical photographs (08/07/2015)

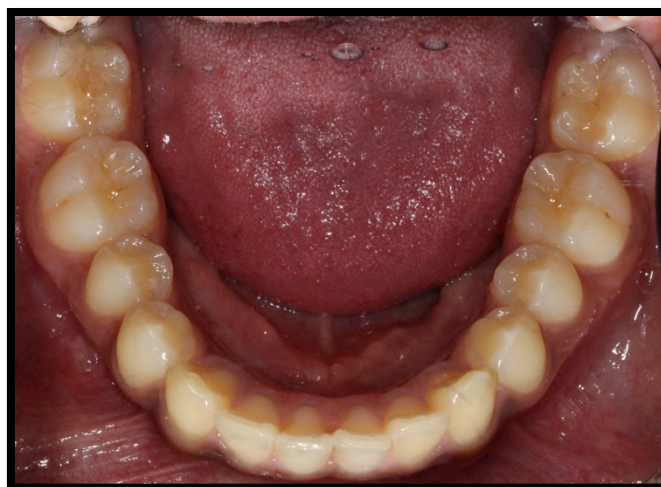Frontal view



Upper occlusal view



Lower occlusal view



Appraisal and Discussion

Due to the high occurrence of traumatic dental injuries (TDI), it is considered a dental public health problem. Its prevalence differs between countries ranging from 4.1% to 58.6% of the permanent dentition (Bastone et al., 2000).

Uncomplicated crown fracture may occur in 20-30% of 12 year-old children; however, one third of 5 year-old children may suffer luxative traumatic injuries (Flores et al., 2007) (Flores, 2002). Roberts and Longhurst in 1996 showed that maxillary central incisor is the most tooth to be affected by trauma and accounts of 73% of all injuries (Roberts and Longhurst et al., 1996).

Because TDIs compromises 5% of all injuries; therefore, occur in high percentages in preschool, school-age children, and adolescents (DiAngelis et al., 2012). According to a 12-year review of the literature, the majority of injuries happening before age nineteen. Showing dental trauma of 25% in school children and 33% in adults (Glendor, 2008).

Seen in 0.5-3% of all dental injuries, avulsion is one of the most serious dental injuries. The prognosis of the avulsed teeth highly depends on the actions undertaken at the place of the accident and straightaway after the accident (Andersson et al., 2012). For better outcomes, a proper emergency management and treatment planning is essential. So, replantation is used in most situations in traumatised avulsed teeth.

A.K, a twelve years old boy, was referred by his GDP regarding his avulsed UL1. Emergency management had been provided at North Wick Hospital where the UL1 Was re-implanted (after more than 2 hours in milk) and splinted and ligatured by a maxillofacial surgeon.

When he first presented, examination was challenging due to his contused, lacerated, and swelled lips and gums. He was diagnosed with the following:

Soft tissue trauma:

- Lip laceration and abrasion
- Labial mucosa and gingivae abrasion and contusion

Periodontal tissue trauma:

- Re-implanted avulsed UL1 with closed apex (more than 60 min)

The ideal treatment for avulsed permanent teeth is to reduce the extra alveolar period by immediate re-implantation; however, the tooth was kept in milk for more than 2 hours. So, the periodontal ligament of the avulsed tooth might be affected.

Delayed re-implantation might have poor long-term prognosis and external root resorption might be expected. The aim of our treatment is to extirpate the pulp of this tooth as soon as possible to reduce the possibilities of inflammation, to minimise the possibility of resorption, to properly seal the root canal using GP, and to preserve the tooth for as long as possible. Ideally extirpation of the mature permanent tooth should be established within 7-10 days following the trauma.

Upon examination, soft tissue trauma was seen and the surgeon at North Wick Hospital placed a ligature splint around UL1 labially and palatally. In the first visit a wire and composite splint used to immobilise the tooth in the correct anatomical position, to prevent further trauma and allow healing to occur. Functional splint was used to maintain physiological tooth mobility and prevent bony healing (ankylosis) (Andersson *et al*, 2012). The removal of the ligature splint in the first visit was not possible because patient's lips and gums were traumatised. After 1 week the soft tissue trauma healed and the ligature splint removed while the dental splint placed in the first visit kept for another 3 weeks to sum up with 4 weeks flexible splinting as mentioned in the international association of dental traumatology guidelines for the management of dental injuries: (avulsion of permanent teeth) (Andersson *et al.*, 2012).

Pulp extirpation and dressing the canal using Ca(OH)_2 was used to achieve disinfection and reduce the possibility of inflammation (Andreasen *et al*, 2002). Conventional root canal treatment was carried out on this tooth and lateral condensation obturation technique was used. The obturation was homogenous and created a good apical seal.

However, 6 months after obturation an apical radiolucency related to the UL1 was noted. Though, upon treatment completion the apex of UL1 was mature and there was no any sign of infection related. Thus, the tooth was obturated with GP to reduce any risk of reinfection or root fracture.

In terms of the radiolucency noted, following avulsion and periodontal membrane injury, the type of periodontal healing that is more likely to occur can be bony healing (ankylosis) or inflammatory resorption (Day and Gregg, 2012).

Therefore, a possible consequence of the trauma A.K suffered can have poor prognosis of the UL1. However, an endodontic consultation advised on monitoring and assesses the infection related to UL1, so a decision was to monitor the radiolucency. After 2 reviews (6 months after detecting the radiolucency / 14 months after obturation), the radiolucency faded gradually and possibly a replacement resorption followed the initial inflammatory resorption.

The inflammation related to UL1 will be monitored every 6 months clinically and radiographically. Extraction or decoronation as possible treatment options were discussed with A.K (Cohenca and Stabholz, 2007). However, clinical photos were taken in every visit to monitor any gingival discrepancy of the UL1.

Appraisal: A.K. was informed about the prognosis of his tooth and future management and treatment options were discussed with him, however he was happy with the colour of his teeth and pleased with the results. A.K will be reviewed and followed up for 5 years.

References

- Andreasen, J.O., Farik, B. & Munksgaard, E.C., (2002). Long-term calcium hydroxide as a root canal dressing may increase risk of root fracture. *Dental Traumatology*, 18, p. 134-137.
- Andreasen, J.O., Andreasen, F.M., Bakland, L.K. & Flores, M.T., (2003). *Traumatic Dental Injuries. A Manual*. 2nd ed. Oxford, UK: Blackwell Munksgaard.
- Andersson, Lars, O. Jens, Anthony J. DiAngelis, J. David, Asgeir Sigurdsson Kenny, Cecilia Bourguignon, Marie Therese Flores et al. "International Association of Dental Traumatology guidelines for the management of traumatic dental injuries~ 2. Avulsion of permanent teeth." (2012).
- ANDERSSON, L., ANDREASEN, J. O., DAY, P., HEITHERSAY, G., TROPE, M., DIANGELIS, A. J., KENNY, D. J., SIGURDSSON, A., BOURGUIGNON, C. & FLORES, M. T. 2012. International Association of Dental Traumatology guidelines for the management of traumatic dental injuries: 2. Avulsion of permanent teeth. *Dental Traumatology*, 28, 88-96.
- Bastone EB, Freer TJ, McNamara JR. Epidemiology of dental trauma: A review of the literature. *Australian Dent J* 2000; 45:2-9.
- DIANGELIS, A. J., ANDREASEN, J. O., EBELESEDER, K. A., KENNY, D. J., TROPE, M., SIGURDSSON, A., ANDERSSON, L., BOURGUIGNON, C., FLORES, M. T. & HICKS, M. L. 2012. International Association of Dental Traumatology guidelines for the management of traumatic dental injuries: 1. Fractures and luxations of permanent teeth. *Dental Traumatology*, 28, 2-12.
- FLORES, M. T. 2002. Traumatic injuries in the primary dentition. *Dental Traumatology*, 18, 287-298.
- Flores, M.T., Andersson, L., Andreasen, J.O., Bakland, L.K., Malmgren, B., (2007). Guidelines for the management of traumatic dental injuries. I. Fractures and luxations of permanent teeth. *Dental Traumatology*. IADT guidelines. 23, 66-71.
- Andersson, L., Andreasen, J. O., Day, P., Heithersay, G., Trope, M., DiAngelis, A. J., Kenny, D. J., Sigurdsson, A., Bourguignon, C. & Flores, M. T. 2012. International Association of Dental Traumatology guidelines for the management of traumatic dental injuries: 2. Avulsion of permanent teeth. *Dental Traumatology*, 28, 88-96.
- Cohenca, N. & Stabholz, A. 2007. Decoronation—a conservative method to treat ankylosed teeth for preservation of alveolar ridge prior to permanent prosthetic reconstruction: literature review and case presentation. *Dental Traumatology*, 23, 87-94.
- Day, P. & Gregg, T. 2012. Treatment of avulsed permanent teeth in children. *Faculty Dental Journal*, 3, 166-169.
- DiAngelis, A. J., Andreasen, J. O., Ebeleseder, K. A., Kenny, D. J., Trope, M., Sigurdsson, A., Andersson, L., Bourguignon, C., Flores, M. T. & Hicks, M. L. 2012. International Association of Dental Traumatology guidelines for the management of traumatic dental injuries: 1. Fractures and luxations of permanent teeth. *Dental Traumatology*, 28, 2-12.

- Flores, M. T. 2002. Traumatic injuries in the primary dentition. *Dental Traumatology*, 18, 287-298.
- Glendor, U. 2008. Epidemiology of traumatic dental injuries—a 12 year review of the literature. *Dental traumatology*, 24, 603-611.



CASE REPORT

Case 4:

Complex restorative treatment (Managing the developing child)

**In partial fulfilment of the degree
Clinical Doctorate in Paediatric Dentistry
Eastman Dental Institute
University College London
2012 - 2015**

Submitted by

Lama Dakkouri

DDS (Jordan), MFD (Ireland)

Contents

CONTENTS.....	II
CASE SUMMARY	III
PRE-OPERATIVE CLINICAL PHOTOGRAPHS (02/10/2013) BEFORE DEBONDING	V
POST-OPERATIVE CLINICAL PHOTOGRAPHS (12/05/2015)	VI
CASE HISTORY.....	1
PERSONAL DATA:.....	1
REASON FOR REFERRAL:	1
CHIEF COMPLAINT (C/O)	1
HISTORY OF COMPLAINT	1
MEDICAL HISTORY (MH)	1
FAMILY HISTORY	2
SOCIAL HISTORY	2
DENTAL HISTORY	2
ORAL HYGIENE.....	2
DIET	2
HABITS	2
CLINICAL EXAMINATION.....	3
INTRA-ORAL EXAMINATION (I/O)	III
PRE-OPERATIVE RADIOGRAPHS	III
DIAGNOSIS AND TREATMENT PLANNING.....	IV
DIAGNOSIS.....	IV
TREATMENT OBJECTIVES.....	IV
PROVISIONAL TREATMENT PLAN.....	IV
TREATMENT PROGRESS AND DENTAL MANAGEMENT	VI
VISIT 1 2/10/2013	VI
VISIT 2 31/10/2013	VI
VISIT 3 6/11/2013:.....	VII
VISIT 4 28/11/2013	VIII
VISIT 5 9/12/2013	VIII
VISIT 6 6/01/2014:.....	IX
VISIT 7 23/01/2014	X
VISIT 8 27/02/2014	X
VISIT 9 17/03/2014	XI
VISIT 10 10/04/2014	XII
<i>Photos upon completion of the treatment:</i>	<i>XIII</i>
VISIT 11 21/10/2014	14
VISIT 12 12/05/2015	14
LONG-TERM PLAN:	15
POST-OPERATIVE CLINICAL PHOTOGRAPHS (12/05/2015)	16
APPRAISAL AND DISCUSSION.....	17
REFERENCES	21

Case summary

J.A. is a 15-year-old young boy who was referred by the hypodontia clinic at the Eastman Dental Hospital (EDH) to provide prosthetic replacements of his missing teeth.

A diagnosis of severe congenital hypodontia was made based on the history and clinical examination, together with the presence of microdont peg upper right lateral incisor and retained primary teeth. He has class I incisor relation on a class I skeletal base with maxillary and mandibular teeth spaces. His main complain when he first presented was missing adult teeth. When he first presented to the paediatric department J.A was under orthodontic treatment to idealise spaces between his teeth for further prosthodontics replacements.

He has mild controlled asthma. No history of any early childhood illnesses or systemic disorders. He was a regular dental attendee to his GDP and under orthodontic treatment in the Eastman dental hospital to idealise spaces. Previously he had extraction of his retained primary teeth under inhalation sedation and local anaesthesia.

Upon examination, he presented with 11 missing permanent teeth (severe hypodontia) with 3 retained (infra occluded) primary teeth and a microdont peg shape UR2. Radiographic examination showed missing adult teeth and retained primary teeth with adequate spaces and root parallelism.

Treatment was carried mainly using non-pharmacological behaviour management (NPBM) techniques.

Treatment provided:

Prevention

- Oral hygiene instructions (OHIs).
- Dietary advice.

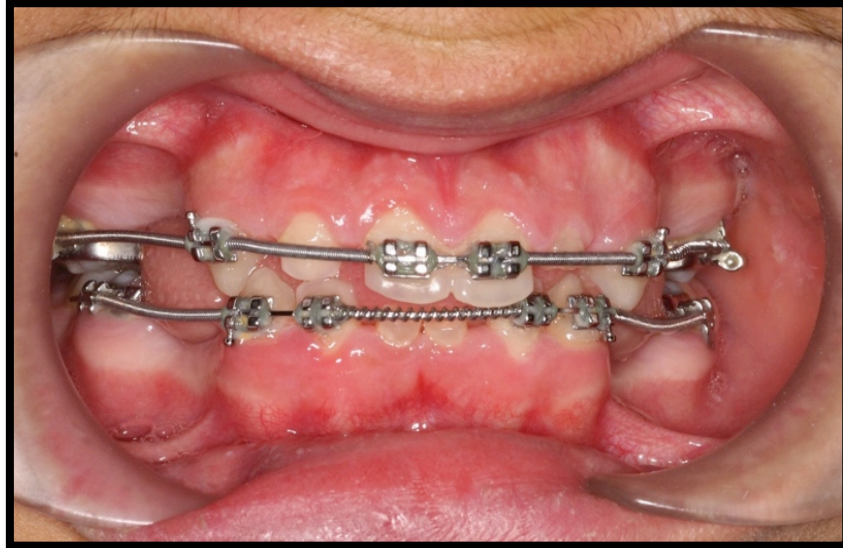
Restoration and prosthesis

- Composite build up of UR2
- Reshaping of UR1 and UL1 with composite
- Resin bonded bridge (RBB) to replace UL2 after extraction of ULB

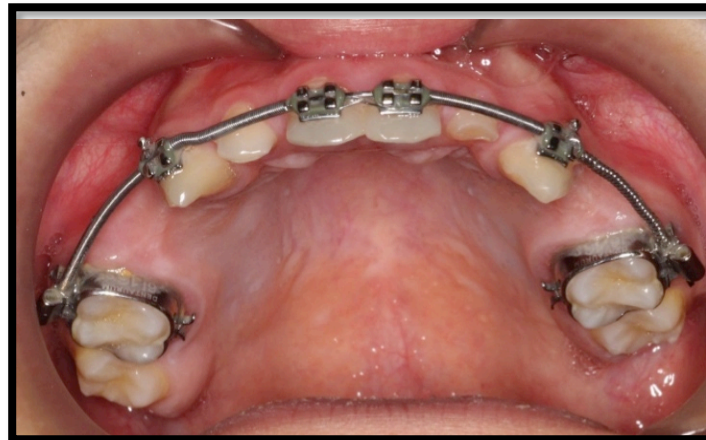- Resin bonded bridge (RBB) to replace LR1 and LL1 after extraction of retained LRA and LLA
- Upper and lower removable partial dentures to replace upper and lower 4's and 5's

Pre-operative clinical photographs (02/10/2013) before debonding

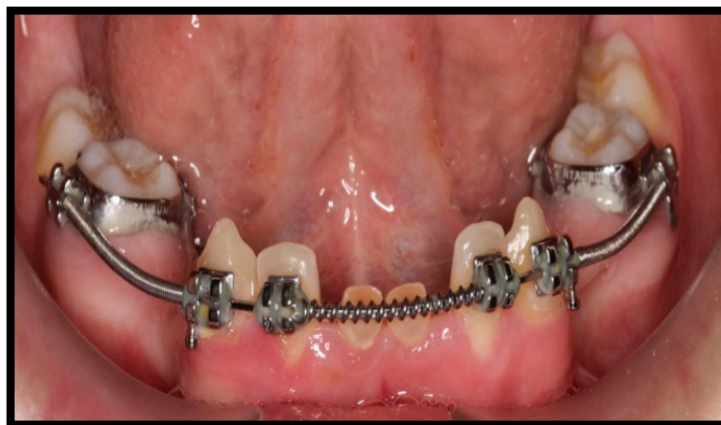Frontal view



Upper occlusal view

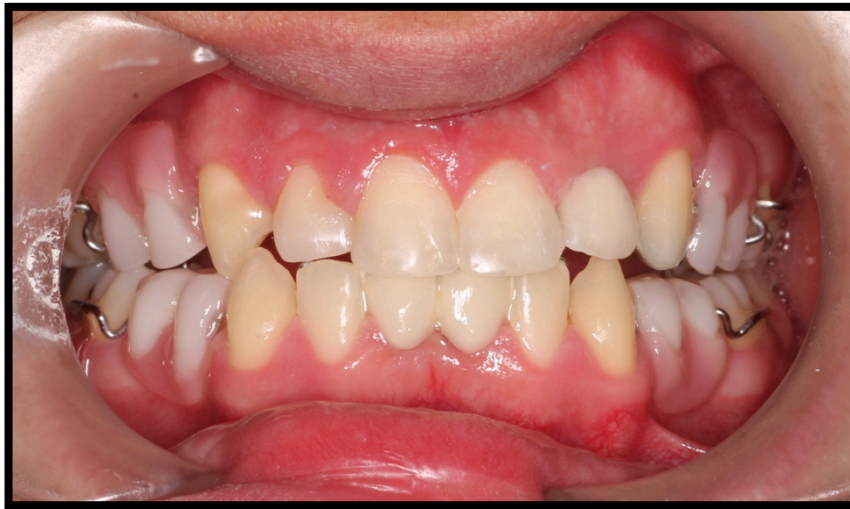

Lower occlusal view

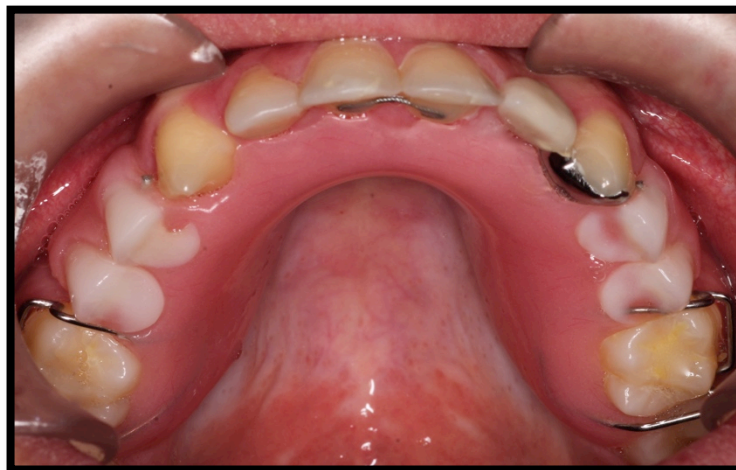

Post-operative clinical photographs (12/05/2015)

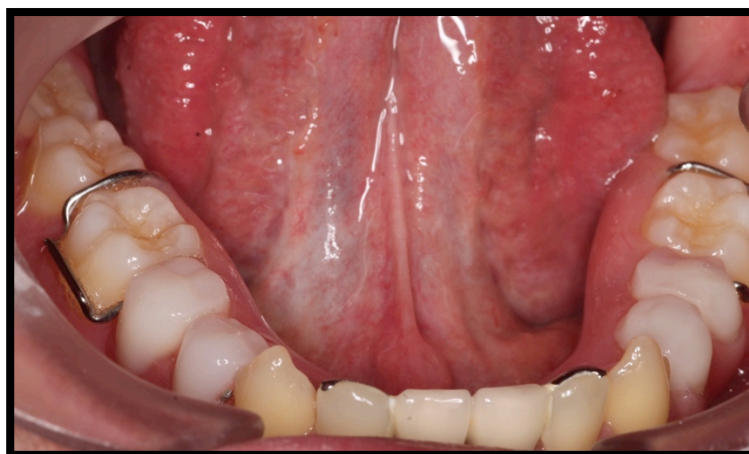Frontal view



Upper occlusal view



Lower occlusal view



Case History

Personal data:

J.A.

Male.

Date of Birth: 16/10/1997.

Referred by: hypodontia clinic.

Date of first attendance: 2/10/2013.

Age at presentation: 15 years and 11 months.

Reason for referral:

He was referred by hypodontia clinic at the Eastman Dental Hospital (EDH) to provide prosthetic replacements of his missing teeth.

Chief Complaint (C/O)

J.A was complaining about missing some adult teeth.

History of Complaint

Patient became concern about the appearance of his teeth when he noticed that he is missing some adult teeth. Therefore, J.A when first presented he was under orthodontic treatment to idealise spaces between his teeth.

Medical History (MH)

He has mild asthma and inhaler used only if needed. Last asthma attack was long time ago (more than 2 years ago). No any previous hospitalisation. Otherwise, he is a fit and healthy young boy who was born full-term with normal delivery. His immunisations were up-to-date and did not suffer any early childhood illnesses.

Family History

No family history of teeth abnormalities or missing teeth

Social History

He is only child.

He was born in the UK and attends Queen Elizabeth School for boys.

Dental History

J was a regular attendee to his GDP 6-monthly. He is under orthodontic treatment for the last 2 years to idealise spaces for prosthetic replacements. Previous extraction of retained URE URD ULC ULE LLD LLE LRD and LRE under LA and IS.

Oral Hygiene

He brushes twice daily with adult's toothpaste and a manual toothbrush.

Diet

He was a good eater and liked a variety of food consuming regular meals. Sweets and snacks occasionally and often drink water and tea with sugar.

Habits

No history of nail biting, thumb sucking or parafunctional activities.

Clinical Examination

Extra-Oral examination (E/O)

Symmetrical face.

No regional Lymphadenopathy.

Normal mouth opening with no temporomandibular joint abnormality.

Intra-Oral examination (I/O)

Soft tissue (ST):

No any significant findings noted.

Oral hygiene (OH):

Good (plaque index (PI): 17%) (Simplified oral hygiene index by Green and Vermilion 1964).

Occlusion:

Permanent molar relationship: class I on the right and left sides.

Class I incisor relation on a class I skeletal base

Maxillary and mandibular spaces between 6's and 3's

Infraoccluded LLA, LRA and ULB

Dentition:

Mixed dentition.

Teeth present as charted

7 6	3 2 1	1 B 3	6 7
7 6	3 2 A	A 2 3	6 7

Microdont peg lateral UR2

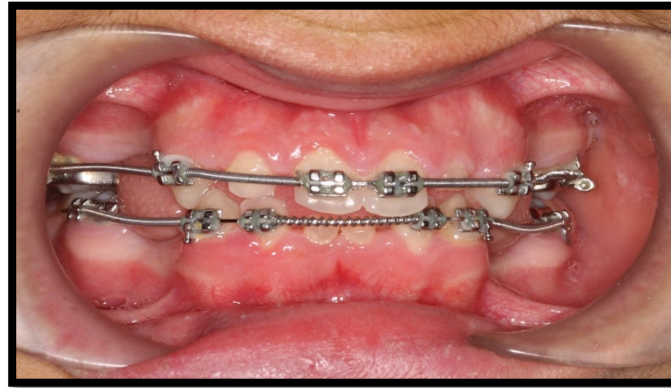
Teeth missing

5 4	2 4 5
5 4 1	1 4 5

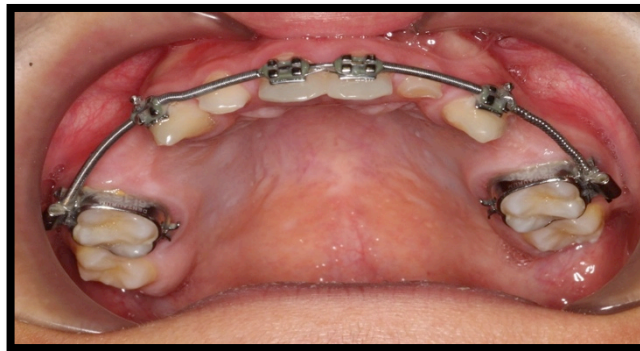
Caries free

Orthodontic wires and brackets exist in first visit

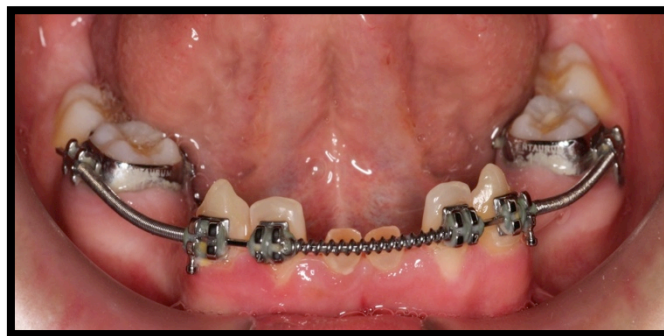Anterior view



Upper occlusal view



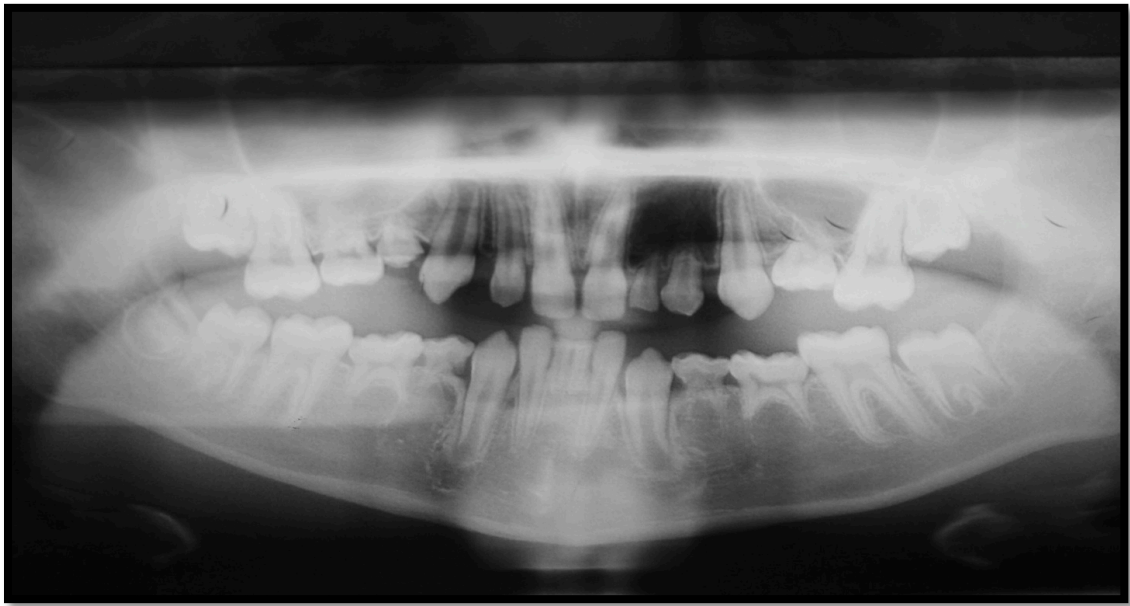
Lower occlusal view



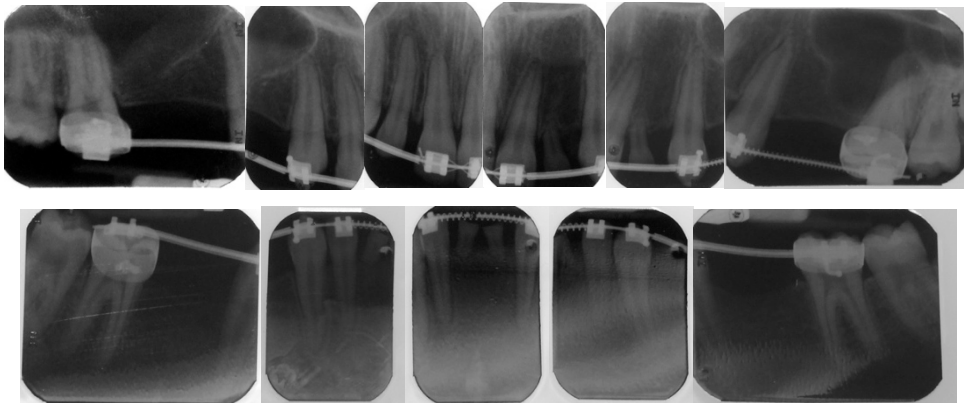
Teeth present:

7 6	3 2 1	1 B 3	6 7
7 6	3 2 A	A 2 3	6 7

Pre-operative radiographs



Orthopantomogram taken before orthodontic treatment
On 22/10/2010



Long cone peri-apical for all the present teeth before ortho debonding on
24/7/2013

Findings:

- Missing permanent teeth

5	4
5	4 1

2	4	5
1	4	5
- Retained

	B
A	A
- No bone and teeth pathology noted
- Adequate spacing and root parallelism

Diagnosis and Treatment Planning

Diagnosis

- Severe congenital hypodontia (11 missing teeth)
- Microdont peg lateral UR2

Treatment Objectives

- To promote oral preventive measures by:
 - Reinforcing and maintaining good oral hygiene
 - Providing dietary education to prevent dental caries
- To restore function and aesthetic.
- To maintain spaces and stabilise dentition for future planning and definitive treatment.
- To enhance positive attitude toward dental care.

Provisional Treatment Plan

Patient was seen in the hypodontia clinic in the Eastman dental hospital and the treatment plan agreed is as follow:

Prevention (according to Delivering better oral health – tool kit – 2015)

OHI.

Dietary education.

Fluoride varnish application every 6 months.

Restoration and extraction

1. Restorative:
 - Composite build up of UR2
 - Reshaping of UR1 and UR2 with composite
 - Resin bonded bridge to replace UL2 after extraction of ULB
 - Resin bonded bridge to replace LL1 and LR1 after extraction of retained LLA and LRA
 - Upper and lower removable partial dentures to replace the missing upper and lower 4's and 5's
2. Extraction of the retained primary teeth (ULB, LLA, and LRA).

Maintenance and follow up

Clinical review every 6 months to monitor prosthesis, restorations, oral health and occlusion.

Reinforcement of dietary advice and OHI (according to delivering better oral health toolkit 2015)

Annual reviews with the hypodontia clinic for future planning

Radiographic review if required every 2 years.

Treatment progress and dental management

Visit 1 2/10/2013

Attended with father.

A complete medical and dental history with clinical and radiographic examination taken.

A provisional treatment plan was formulated and discussed with the father.

Pre-operative clinical photographs (before de-bonding).

OHI:

- Adult toothpaste with 1350ppm Fluoride or above.
- Spitting after brushing rather than rinsing.
- Use mouthwash (0.05% Fluoride) between brushing.

Diet habits education

Behaviour: quiet but very cooperative.

Next appointment: build up of UR2 after orthodontic de-bonding

Visit 2 31/10/2013

Attended with father.

C/O: Nil

MH: No change.

E/O: No abnormalities detected (NAD).

I/O:

Orthodontic appliance de-bonded and essix retainer provided with pontics on 4's and 5's

PI: 11%.

Treatment (TX):

Composite build up of UR2

Dry dam isolation:

Acid etching (phosphoric acid 37%).

Bonding, composite build up using crown form (shade: A1).

Finishing and polishing using composite finishing discs

Upper alginate impression to construct a new retainer (replacing the one provided by orthodontic department to be sent by post)

Post operative instructions

OHI reinforced

Behaviour: very cooperative and happy with the results.

Next appointment: reshape UR1 and UL1 and adjust the composite build up on UR2 if necessary

Visit 3 6/11/2013:

Attended with father.

C/O: Nil

MH: No change.

E/O: NAD.

I/O: NAD

Treatment (TX):

Reshaping of UR1 and UL1

Dry dam isolation:

Acid etching (phosphoric acid 37%).

Bonding, composite to reshape both UR1 and UL1 (shade: A1).

Finishing and polishing using composite finishing discs for UR2, UR1 and UL1

Retainer fits properly so no need to construct a new retainer

Post operative instructions

OHI reinforced

Behaviour: cooperative.

Next appointment: upper and lower impressions to construct both upper and lower immediate dentures plus upper and lower special trays to start RPD

Visit 4 28/11/2013

Attended with father.

C/O: Nil.

MH: No change.

E/O: NAD.

I/O: PI:0%.

TX:

Upper and lower alginate impressions to construct immediate dentures and special trays:

Upper alginate impression using size 3 tray to:

- 1st: to construct immediate dentures with adams clasps on upper 6's and pontics replacing UR4 UR5 UL2 UL4 and UL5
- 2nd: to make upper special tray for the planned upper RPD to be constructed in next visits

Lower alginate impressions using size 3 trays:

- 1st: to construct immediate dentures with adams clasps on lower 6's and pontics replacing LR4 LR5 LR1 LL1 LL4 and LL5
- 2nd: to make lower special tray for the planned lower RPD to be constructed in next visits

POIs.

Behaviour: cooperative.

Next appointment: Extraction of the retained primary teeth

Visit 5 9/12/2013

Attended with father.

C/O: Nil.

MH: No change.

E/O: NAD.

I/O: PI:0%.

TX:

Extraction of ULB, LRA, and LLA

- Topical anaesthesia
- Local anaesthesia (2% lignocaine and 1:80,000 epinephrine) infiltrated in ULB LRA and LLA mucosa

- Simple extraction of ULB LRA and LLA using forceps
- Haemostasis achieved
- Upper and lower immediate dentures inserted (dentures fits properly and patients happy with it)
- Post-operative instructions and denture instructions.

Behaviour: very cooperative.

Next appointment: upper and lower secondary impressions using the special trays

Visit 6 6/01/2014:

Attended with mother

C/O: Nil.

MH: No change.

E/O: NAD.

I/O:

Gum healed after the extraction last visit and the immediate dentures fitting properly

PI:0%.

TX:

Upper and lower secondary impressions:

- Upper and lower silicone (heavy and light body) impression using the special trays to construct upper and lower RPD

⇒ RPD design:

– Adam's clasps on $\begin{array}{c|c} 6 & 6 \\ \hline 6 & 6 \end{array}$

– C-clasp on $\begin{array}{c|c} 3 & 3 \\ \hline 3 & 3 \end{array}$

– Pontics to replace $\begin{array}{cc|cc} 5 & 4 & 4 & 5 \\ \hline 5 & 4 & 4 & 5 \end{array}$

- RPD Shade selection (shade A1)

Behaviour: cooperative.

Next appointment:

- Wax try of the RPD's and asses healed gum for considering the RBB construction

Visit 7 23/01/2014

Attended with father.

C/O: no complains

MH: No change.

E/O: NAD.

I/O: PI:0%.

TX:

Wax try-in of the RPD:

Upper and lower wax RPD fit properly and occlusion checked (Patient satisfied)

Gum on UL2 and LR1 and LL1 healed but more time allowed for constructing the RBB replacing UL2 and LR1 and LL1

Behaviour: cooperative.

Next appointment:

- Assess healed gum for considering the RBB construction

Visit 8 27/02/2014

Attended with father.

C/O: no complains

MH: No change.

E/O: gum on UL2, LR1 and LL1 healed and agreed to start RBB construction.

I/O: PI:0%.

TX:

Upper and lower silicone impressions to construct resin-bonded bridges (RBB) replacing UL2, LL1, and LR1

Upper and lower silicone impression:

Upper silicone impression to construct RBB replacing UL2 with a wing on UL3

Lower silicone impression to construct 2 RBB's

- 1st: replacing LL1 With a wing on LL2

- 2nd: replacing LR1 with a wing on LR2

Shade selection (A1)

Behaviour: cooperative.

Next appointment:

Deliver all prosthesis:

- Upper and lower RPD's
- Upper and lower RBB's

Visit 9 17/03/2014

Attended with mother

C/O: no complains

MH: No change.

E/O: NAD.

I/O: PI:0%.

TX:

Delivery of RPD's and RBB's:

- Upper RPD replacing upper right and left 4's and 5's with adam's clasps on upper 6's and C-clasps on upper 3's fitted and adjusted with adams plier
- Lower RPD replacing lower right and left 4's and 5's with adams clasps on lower 6's and C-clasps on lower 3's fitted and adjusted.
- Lower right C-clasp removed because lower denture was too retentive and patient unable to take it off appropriately.
- Upper and lower RBB's cemented using PANAVIA cement under dry dam isolation
- Post operative instructions (denture and bridge instructions)
- Patient happy with the result

Behaviour: cooperative.

Next appointment:

- Review
- Assess patient's acceptance of the prosthesis
- Adjust composites on UR2 UL1 UR1 for better aesthetic results

Visit 10 10/04/2014

Attended with mother

C/O: no complains

MH: No change.

E/O: NAD.

I/O: Pl:0%.

TX:

Composite modification of UL2 UL1 UR1:

Dry dam isolation

Composite shade A1 to adjust and modify fillings on upper anterior teeth

Finishing and polishing

Review and assess prosthesis acceptance

J is satisfied with the treatment's results

OH is good

Post-operative photos

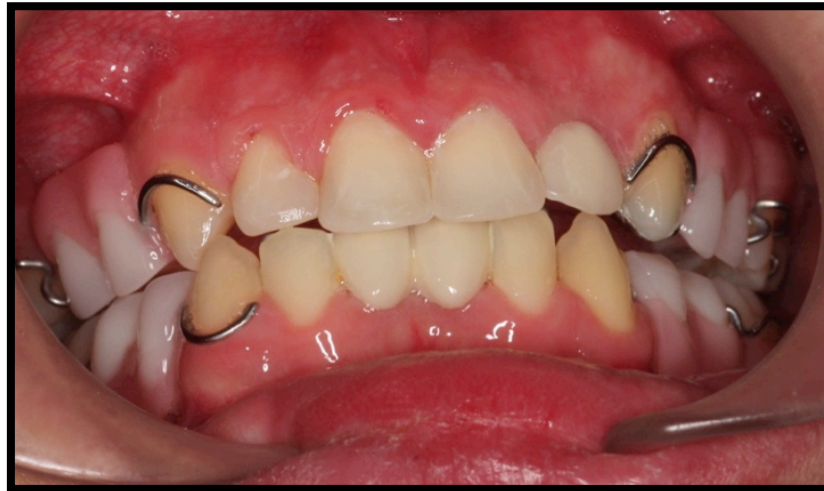Behaviour: cooperative.

Next appointment:

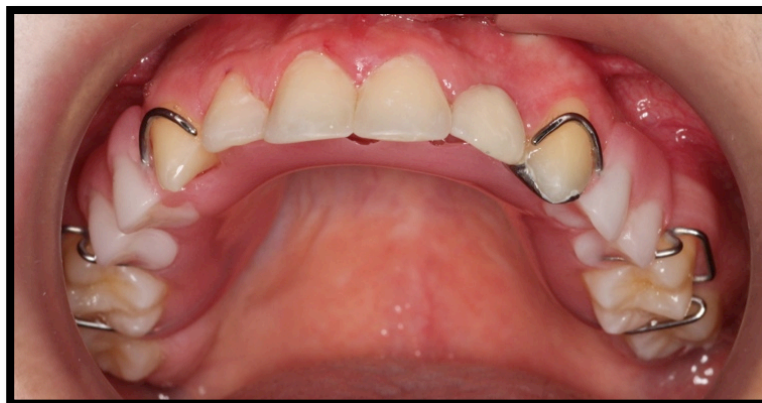- Review after 6 months

Photos upon completion of the treatment:

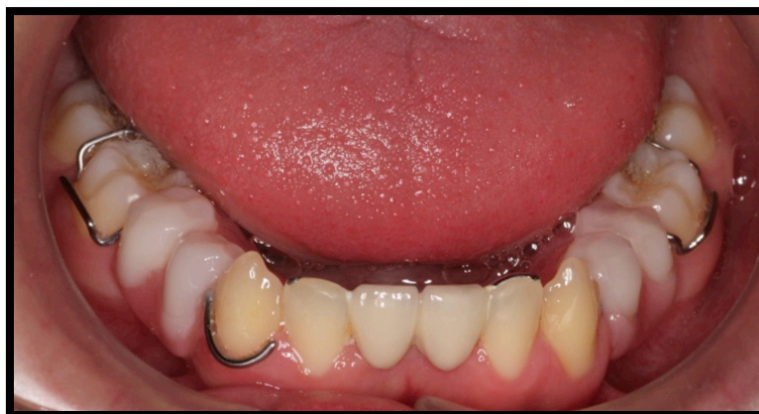Anterior view



Upper occlusal view



Lower occlusal view



Visit 11 21/10/2014

Attended with mother

C/O: no complains

MH: No change.

E/O: NAD.

I/O: PI:0%.

TX:

Minor adjustment for the UL1 composite filling and Review of dentures and bridges

Removal of all the C-clasps on the upper and lower dentures to improve aesthetics.

Restorations intact

J is satisfied with the treatment's results

OH is good

Next appointment:

- Review after 6 months

Visit 12 12/05/2015

Attended alone

C/O: no complains

MH: No change.

E/O: NAD.

I/O: PI:0%.

TX:

Review and fluoride varnish (2.26%) application:

Restorations intact

OH is good

Post-operative clinical photos

Next appointment:

- Review after 6 months

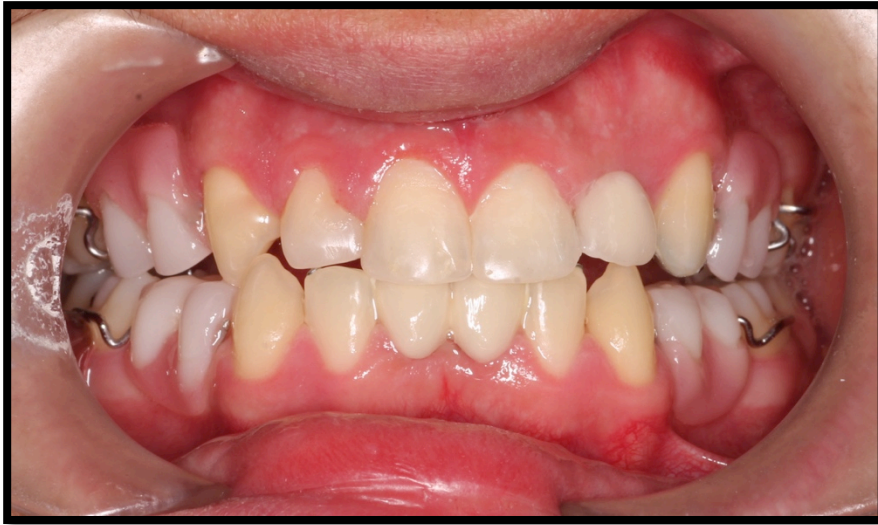Long-term plan:

To review J after every 6 months:

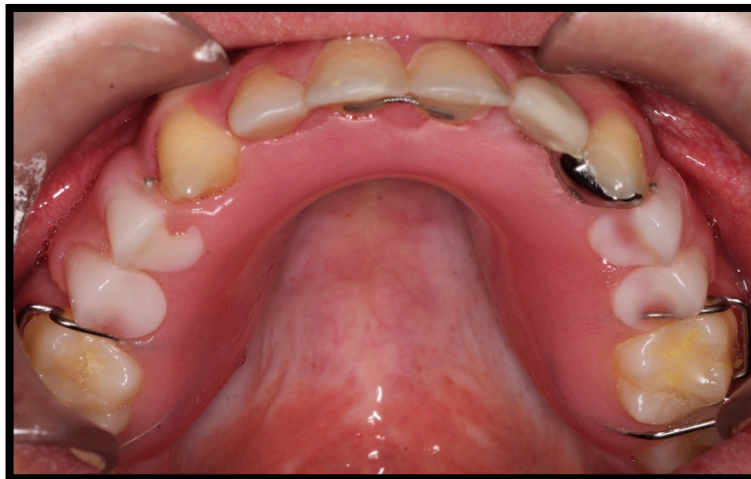- Reinforcement of OHI and diet advises.
- Monitor upper and lower RPD's
- Monitor upper and lower RBB's.
- Monitor composite on UR2 UR1 and UL1.
- Monitor spaces between teeth
- Refer back to hypodontia clinic for annual reviews regarding future planning once he is above 18 years (complete dental development) to consider dental implants if possible in future

Post-operative clinical photographs (12/05/2015)

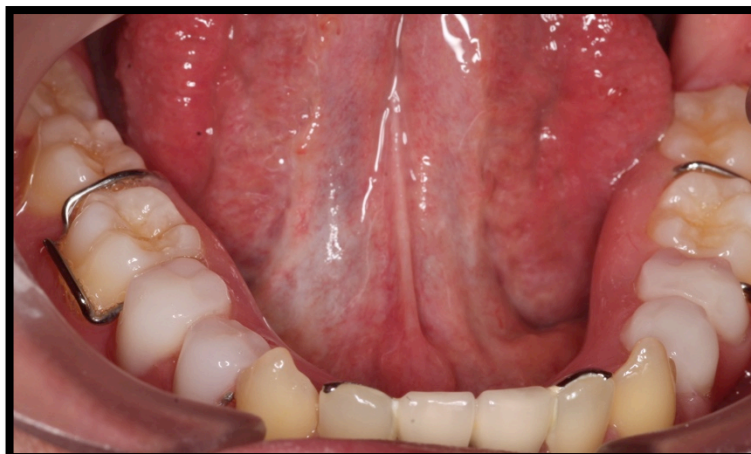Frontal view



Upper occlusal view



Lower occlusal view



Appraisal and Discussion

Hypodontia:

Missing adult teeth can seriously affect a young person physically and emotionally. Hypodontia is defined as the congenital absence of one or more teeth. The cause of it is not yet certain; however, some theories such as, disruptive dental lamina, space limitation, abnormal dental epithelium, and failure of mesenchyme initiation are consequences of teeth absence (Nunn et al., 2003).

It is more common in permanent teeth, around 3.5-6.5% in the Caucasian population. The prevalence is lower in deciduous dentition, ranging between 0.1-0.9%. It occurs in equal frequency in both jaws. The incidence of hypodontia in male to female ratio is 2:3 (Sundram and Walmsley, 2002). Literature showed variation in reporting what tooth types are commonly missing due the ethnic variations. Supposing that the third molars are the most common missing teeth, the following most missing teeth are consequently, mandibular second premolar (2.8%), maxillary lateral incisor (1.6%), maxillary second premolars and mandibular incisors (0.23%-0.08%) (Nunn et al., 2003).

In addition, the main problem with this condition is to improve aesthetics, enable patient to eat wide range of foods, improve speech, promote emotional and psychological well-being, maintain appropriate teeth spaces for future planning, and to ease transition into adolescent (Nunn et al., 2003).

A treatment plan by hypodontia clinic agreed to provide J with:

- Composite build-up of microdont (peg shape) UR2
- Reshaping of UR1 and UR2 with composite veneers
- Extraction of the retained primary teeth (ULB, LLA, and LRA).
- Resin bonded bridge to replace UL2 after extraction of ULB
- Resin bonded bridge to replace LL1 and LR1 after extraction of retained LLA and LRA
- Upper and lower removable partial dentures to replace the missing upper and lower 4's and 5's

The treatment was done according to the hypodontia clinic in order to gain the benefit of the idea of multidisciplinary and interdisciplinary management of young people with hypodontia (Nunn et al., 2003).

Regarding his general health, he has a history of mild asthma. A vigorous history regarding last asthmatic attack, precipitation factors, previous hospitalisation, and medication was undertaken and updated in each visit. Otherwise, J was fit and healthy with no history of early childhood illnesses or any systemic disorders. No any family history of missing or abnormal teeth was reported. J was extremely cooperative and keen to have all the treatment finished. He attended all the appointments and was always on time. Treatment was carried out using NPBM techniques as he was willing to sit for dental treatment.

Microdont teeth and peg-shaped incisors:

It is reported that hypodontia is not an isolated oral condition but can be related to other oral findings. For example, reduced crown dimensions, rotated teeth, lack of alveolar growth, and palatal canines impaction (Nunn et al., 2003). Also a common feature of severe hypodontia is microdontia (Sundram and Walmsley, 2002). Therefore, J presented with proportionally small central incisors and microdont peg shape lateral incisor. Composite fillings to adjust shape were necessary for better aesthetics results.

Prevention:

J.'s oral hygiene was excellent and reinforcement of his oral hygiene and diet habits was formulated according to the Department of Health tool kit (Department of Health, 2009). Maintaining existing dentition is important for normal development and future planning (Hobson et al., 2003). So, J's preventive treatment was necessary for optimising final treatment. In addition prevention of asthmatic attacks was taken into consideration.

Orthodontic treatment:

When first presented J had fixed orthodontic appliances. The orthodontic treatment is essential in managing patient with hypodontia. It can be used to manage the spaces between teeth or to upright and align teeth (Carter et al., 2003). After orthodontic treatment retention is challenging in hypodontic patient, so prosthesis provided will aid as both retentive and function components.

Restorative and prosthodontics treatment:

A range of different restorations can be used to restore affected teeth. For instance, it can be either removable or fixed prosthesis. Constructing removable prosthesis can be used to introduce patient for denture wearing and increase future compliance. On the other hand, fixed prosthesis can be considered when patient is older where growth ceased and edentulous saddle is in favourable conditions (Sundram and Walmsley, 2002).

Composite filling were placed in the microdont teeth. It was preferred, as the growth is still not completed. It is more conservative, effectively bond to teeth, with good mechanical strength and wear resistant compared to GIC and porcelain veneers (Tyas *et al.*, 2000).

Resin bonded bridges has improved lately to be accepted as a definitive restoration. Current researches reported a survival rate over 80% in a period of 6 years. A RBB cantilever design that carries one pontic and single abutment is preferred lately to, ease clinical application, allow flexible path of insertion, and decrease the interproximal metal showing (Jepson *et al.*, 2003). Therefore, this design was formulated in constructing J's RBB. In addition, if missing lateral incisor was to be replaced by RBB in young patients, using the canine as abutment is more favourable to increase aesthetic results. This is by avoiding the greying effect showing through the thin, translucent enamel in central incisors. Ideally 3 months minimally needed between extraction and prosthetic insertion. However, J's retained primary teeth were resorbed and after clinical examination adequate healing was obtained to start formulating the RBB after 2 months.

Removable partial dentures was used to replace upper and lower missing premolars to improve function, maintain spaces for future planning and as an orthodontic retention. The design of the removable partial denture was modified at the insertion stage by removing of the C-clasp in the lower left canine to ease J's ability to insert and remove the denture.

In the reviews appointments and after clinical examination the upper and lower dentures are retentive enough. Therefore, removal of the upper and lower C-clasp was done to enhance the aesthetics.

Maintenance and review

H.J. will be reviewed every 6 months to reinforce OHI and dietary advice (Department of Health, 2015), to monitor the provided prosthesis, monitor the composite fillings in upper anterior teeth, and monitor spaces between teeth. Radiographic review will be every 2 years as needed (SDCEP, 2010). J will also be reviewed annually in the hypodontia clinic for future treatment planning.

Appraisal: J.A. and his parents were happy with the outcome and motivated during the treatment. Providing the prosthesis improved his life style and own perception. It was really rewarding to see him satisfied.

References

- CARTER, N., GILLGRASS, T., HOBSON, R., JEPSON, N., MEECHAN, J., NOHL, F. & NUNN, J. 2003. The interdisciplinary management of hypodontia: orthodontics. *British dental journal*, 194, 361-366.
- Department of Health, 2015. Delivering Better Oral Health An evidence-based toolkit for prevention - third edition.
- HOBSON, R., CARTER, N., GILLGRASS, T., JEPSON, N., MEECHAN, J., NOHL, F. & NUNN, J. 2003. The interdisciplinary management of hypodontia: the relationship between an interdisciplinary team and the general dental practitioner. *British dental journal*, 194, 479-482.
- JEPSON, N., NOHL, F., CARTER, N., GILLGRASS, T., MEECHAN, J., HOBSON, R. & NUNN, J. 2003. The interdisciplinary management of hypodontia: restorative dentistry. *British dental journal*, 194, 299-304.
- NUNN, J., CARTER, N., GILLGRASS, T., HOBSON, R., JEPSON, N., MEECHAN, J. & NOHL, F. 2003. The interdisciplinary management of hypodontia: background and role of paediatric dentistry. *British dental journal*, 194, 245-251.
- Scottish Dental Clinical Effectiveness Programme, 2010. Prevention and Management of Dental Caries in Children.
- SUNDRAM, F. & WALMSLEY, A. 2002. The management of severe hypodontia in a young adult patient: a case report. *Dental update*, 30, 326-330.
- Tyas, M.J. et al., 2000. Minimal intervention dentistry — a review*. *International Dental Journal*, 50(1), pp.1–12.3.