



Horizons in Medicine: Update in diagnosis and management of interstitial lung disease

Journal:	<i>Clinical Medicine</i>
Manuscript ID	CM-2016-0265.R1
Manuscript Type:	Review
Keywords:	Interstitial lung disease, Idiopathic pulmonary fibrosis, cryoscopic lung biopsy

SCHOLARONE™
Manuscripts

Pre-View Only

ABSTRACT

The field of Interstitial Lung Disease (ILD) has undergone significant evolution in recent years, with an increasing incidence and more complex, ever expanding disease classification. In their most severe forms these diseases lead to progressive loss of lung function, respiratory failure and eventually death. Despite notable advances, progress has been challenged by a poor understanding of pathological mechanisms and patient heterogeneity, including, variable progression. The diagnostic pathway is thus being continually refined, with the introduction of tools such as transbronchial cryo lung biopsy and a move towards genetically aided, precision medicine. In this chapter, we will focus on how to approach a patient with ILD and the diagnostic process.

INTRODUCTION

Interstitial lung disease (ILD) is an umbrella term for over 200 different diseases which display considerable variation in terms of clinical course, treatment and prognosis. Broadly speaking they can be sub-divided into those with an identifiable cause and those without, the latter being referred to as idiopathic interstitial pneumonias (IIPs). Clinical assessment aims to identify a possible cause; screening for features of systemic disease (e.g. connective tissue disease, CTD) or environmental triggers. Relevant exposures include pneumotoxic drugs, radiation therapy, occupational exposures (e.g. asbestosis) or implicated allergens (hypersensitivity pneumonitis, HP).

Distinguishing the various forms of pulmonary fibrosis is critical for determining correct management and for predicting prognosis, however, this is often obfuscated by the fact the lung has a limited repertoire in response to injury and consequently, a finite number of disease patterns. In essence, all ILD is characterised by variable degrees of inflammation and fibrosis, not only between diseases, but also among individuals with the same disease (Figure a). In inflammation dominant disease the histology is that of organising pneumonia, or non-specific interstitial pneumonitis (NSIP), whilst in fibrosis dominant disease, one would expect to see usual interstitial pneumonitis (UIP), characterised by fibroblastic foci and only mild to moderate inflammation. These histological patterns are associated with specific radiological features, the recognition of which may abrogate the need for a formal biopsy and tissue diagnosis.

IDIOPATHIC PULMONARY FIBROSIS

IPF is the most common of the IIPs, with an incidence of approximately 6,000 cases per year in the UK, affecting mainly older males. Median survival is worse than many cancers at just three years and the disease accounts for 5,300 deaths each year in the UK (1). IPF is a growing problem, with an annual increase in incidence of 11% between 1991 and 2003, a rise that is only partly explained by an ageing population (2).

As already alluded to, distinguishing IPF from other ILD, including other idiopathic forms, is important for multiple reasons. IPF does not respond to immunosuppressive therapy, in fact, immunomodulation may worsen outcomes (3). By contrast there is evidence, particularly in systemic sclerosis associated ILD (4), of benefit from cyclophosphamide and multiple case reports suggest a potential role for rituximab (5) as salvage therapy in CTD-ILD. In addition, there are now two drugs, pirfenidone and nintedanib, approved by NICE for IPF, however, at an annual cost of around £26,000 per patient and the potential for significant side effects, accurate disease identification is essential. Finally, IPF has a worse prognosis than other ILD, hence a definitive diagnosis allows for timely involvement of palliative care physicians and consideration of lung transplantation.

PATHOGENESIS OF IPF

The pathogenesis of IPF is complex and poorly understood, but involves aberrant wound healing in the context of repetitive alveolar injury. This results in abnormal fibroblast proliferation, differentiation and activation, which in turn drives expansion of the extracellular matrix with loss of normal lung architecture, whilst inflammation plays a less dominant role. This is illustrated schematically in Figure b.

GENETICS IN DIAGNOSIS AND MANAGEMENT OF IPF

Although the initiating events in IPF are poorly understood, the disease is likely to be the result of environment exposures in genetically susceptible individuals. Certainly, it is estimated that approximately 20% of IIPs have a genetic component and familial cases (referred to as Familial Interstitial Pneumonias, FIP) were first described in the 1950s. The majority of these FIPs are autosomal dominant with incomplete penetrance, but some may arise *de novo*. The most commonly affected genes are those involved in surfactant processing and telomere biology. At present, routine genetic testing is not recommended, however, ILD patients with at least one affected first degree

1
2
3 relative, should be offered the opportunity to enrol in the UK wide 100,000 Genomes Project,
4 whereby they undergo whole genome sequencing.
5

6
7 Genetics also have a proven role in sporadic IPF. Polymorphisms in the promoter for the gene
8 encoding the salivary mucin, 5b (MUC5B) and for the Toll-interacting protein (TOLLIP) are both
9 associated with an increased risk of developing IPF, although both result in a relatively mild
10 phenotype. These genetic variants provide the first possible targets for precision medicine in IPF,
11 with a post hoc analysis of the PANTHER data establishing a variable response to N-acetyl cysteine
12 depending on the individual's TOLLIP genotype (6).
13
14
15
16

17 **DIAGNOSTIC WORK UP IN INTERSTITIAL LUNG DISEASES**

18
19 Initial investigations include blood tests to detect the presence of autoantibodies (Table 1),
20 precipitating immunoglobulins against organic antigens and serum ACE. These tests alone rarely
21 confirm the diagnosis and there is potential for both false positive (particularly autoantibodies in
22 older patients) and false negative (failure to identify an antigen and IgG does not exclude HP) results,
23 however, they can be useful in helping direct further diagnostics.
24
25
26
27
28
29

30 Pulmonary function tests (PFTs) are key in appraising these patients and whilst they rarely refine the
31 specific diagnosis in individuals with proven ILD, they inform on disease severity at baseline and
32 response to treatment over follow up.
33
34

35 **RADIOLOGICAL WORK UP**

36 **Chest Radiographs**

37
38 A Chest x-ray (CXR) is often the first radiological investigation in ILD patients and whilst it is rarely
39 sufficient to make a confident diagnosis, X-ray can play a role in establishing disease chronicity and
40 progression.
41
42
43
44
45

46 **High Resolution Computed Tomography**

47
48 High-resolution computed tomography (HRCT) of the thorax has revolutionised the diagnosis and
49 classification of ILD and in many cases removes the need for invasive diagnostic procedures,
50 however, the quality of the images is dependent on the scanning protocol employed (Table 2).
51
52
53

54 The ATS/ERS 2011 consensus statement (7) provides criteria for a definite UIP pattern on HRCT
55 (Figure c), with the presence of these conferring a sensitivity of approximately 40%, but a specificity
56 of 95% for histological UIP. The main discriminating feature for UIP is the presence of
57
58
59
60

1
2
3 honeycombing, however, typical CT appearances are only present in two thirds of patients and it is
4 in the remaining third of cases, that biopsy may have a role.
5
6

7 **BRONCHOSCOPY IN THE ASSESSMENT OF ILD**

8 **Bronchoalveolar Lavage, Endobronchial Ultrasound and Transbronchial Biopsy**

9
10 There is much variation in practice surrounding the use of bronch-alveolar lavage (BAL), particularly
11 between European centres and North American colleagues, who rarely utilise it. Clearly, there is
12 value in excluding infection, which may be a differential diagnosis, however, BAL alone is rarely
13 diagnostic, with perhaps one of the difficulties being a lack of consistency in terms of how samples
14 are taken and processed. Under optimal circumstances BAL reflects cellular traffic in the alveolar
15 space and the cell differential may provide supplemental information to help refine, rather make a
16 diagnosis. In particular, an excess of lymphocytes should call into question a presumptive IPF
17 diagnosis, with Ohshimo et al. describing a BAL lymphocytosis of >30% in 6 of 74 patients with
18 definite UIP features on HRCT. In all six cases, further investigations led to a final diagnosis of chronic
19 hypersensitivity pneumonitis (8).
20
21
22
23
24
25
26
27

28
29 Transbronchial biopsy (TBB) with standard forceps is a minimally invasive technique, but does not
30 always provide adequate lung tissue to establish a final diagnosis. The biopsies are small, subject to
31 crush artefact and may not be representative in spatially heterogeneous disease (9,10). It may,
32 however, be helpful in the diagnosis of sarcoidosis and organising pneumonia.
33
34
35
36

37 **Transbronchial Cryo Lung Biopsy**

38
39 Transbronchial cryo lung biopsy (TBCLB) was first described in 2008 (11). It has since been shown to
40 be a safe, minimally invasive and effective diagnostic tool for the histological diagnosis of ILD, with a
41 diagnostic yield of up to 74–80% (11–15). The advantage of TBCLB over TBB lies in the larger
42 specimen size, with a mean size range of 9mm² to 64mm² (11–20). In addition, the technique avoids
43 crush or bleeding artefact, which can distort the tissue architecture (Figure d). The published data on
44 TBCLB shows a safety profile that is comparable to TBB, with bleeding post biopsy in around 10% of
45 cases, all of which was controlled bronchoscopically. The mean rate of pneumothorax requiring
46 chest drain insertion is around 4%, although there is a wide variation between centres.
47 Exacerbations of ILD are rare (0.5%) and only one mortality has been reported (0.2%) (11–20).
48
49
50
51
52
53
54

55 Pajares et al conducted a prospective randomised trial comparing TBCLB with TBB and demonstrated
56 a mean specimen size for TBCLB samples of 14.7mm² (vs 3.3mm² for TBB biopsy p <0.001) resulting
57
58
59
60

1
2
3 in a histological diagnosis in 74.4% of patients versus 34.2% in the TBB group ($p<0.001$) (14). When
4 comparing this technique with surgical lung biopsy there are various potential advantages. General
5 anaesthesia is not necessary and the procedure can be performed as a day case with uncomplicated
6 cases returning home the same day. Future clinical trials and an increase in real world experience of
7 TBCLB is likely to cement it's use for selected cases, potentially reducing the number of surgical lung
8 biopsies performed.
9
10
11

12 13 **SURGICAL LUNG BIOPSY**

14
15
16 Surgical lung biopsies (SLB) are the current gold standard for obtaining histological material in the
17 diagnosis of clinically and radiologically unclassifiable ILD. SLB is usually performed via the less
18 invasive Video-Assisted Thoracoscopic Surgical (VATS) approach. As previously described the 2011
19 ATS/ERS consensus statement means about two thirds of IPF cases can be diagnosed on the basis of
20 typical clinical and radiological findings of UIP (Figure e), however, indications are that only 7.5%-
21 12% of suspected IPF patients undergo SLB in the UK (28). This reflects clinicians' reluctance to refer
22 patients for a procedure associated with a significant mortality and morbidity.
23
24
25
26
27
28

29 The average hospital stay associated for a VATS biopsy is 2-4 days (23), with mortality rates of 3-4%
30 and an overall complication rate of up to 16% (24). Common complications include; persistent air-
31 leak, exacerbations of underlying ILD due to mechanical stress of single lung ventilation, bleeding
32 and delayed wound healing. In addition, 57% of patients report pain at the incision site 6-12 months
33 after surgery (25). It is also worth remembering that SLB does not guarantee a definite pathological
34 diagnosis, with diagnosis rates ranging from 34% to 100% (23,24).
35
36
37
38
39

40 **MULTIDISCIPLINARY TEAM**

41
42
43 Taking into consideration the various investigations involved in ILD diagnosis it is clear that no single
44 diagnostic test can provide a confident answer. A consensus approach by a Multidisciplinary Team
45 (MDT) with expertise in ILD is thus considered the gold standard (Figure f). The MDT integrates all
46 available data at several stages of the work-up. This not only improves inter-observer agreement
47 and diagnostic confidence, but may also prevent unnecessary surgical biopsies, whilst identifying
48 patients in whom a biopsy may effectively contribute to the diagnosis (26). Current NICE guidelines
49 recommend that IPF should only be diagnosed by MDT consensus and stipulates a minimum MDT
50 composition (27).
51
52
53
54
55
56
57
58
59
60

NOVEL THERAPIES IN IPF

There has been a dramatic increase in clinical trial activity in IPF in recent years, with the discovery and approval of two new anti-fibrotic drugs, pirfenidone and nintedanib, heralding a new era in the disease. While these novel anti-fibrotic agents have been shown to slow the decline in Forced Vital Capacity (FVC) they neither halt progression nor reverse existing fibrosis. In part due to considerable cost, their use is restricted by NICE to patients fulfilling certain criteria, namely a FVC of 50-80% predicted, thereby excluding patients at each extreme of the disease process and those with spuriously maintained FVC due to concurrent emphysema. Given these restrictions, as well as the limitations of these therapies, the importance of non-pharmacological therapy such as pulmonary rehabilitation, plus the enrolment of patients into clinical trials (Figure g) should not be underestimated.

NOVEL BIOMARKERS:

The need to distinguish the different IIPs has driven the search for novel diagnostic biomarkers. In addition, there are marked survival differences even within specific groups such as IPF. Biomarkers that can identify these phenotypes are needed for clinical decision-making, but they also have the potential to aid cohort enrichment in clinical trials. Previous landmark studies have beautifully illustrated this need, with variable rates of decline in placebo arms leading to inconsistent results and a delay in drugs being approved (28).

To date, efforts have focussed on serum biomarkers (29) that are relatively easy to access and novel imaging modalities which potentially inform on disease activity within the lung. In particular, Positron emission tomography (PET) allows non-invasive measurement of cellular metabolism *in vivo*. The 18F-Fluorodeoxyglucose (18F-FDG) PET signal is consistently raised in ILD (30) and is both stable and reproducible (Figure h). In a population of over 200 ILD patients, we have shown that baseline measures of 18F-FDG up-take on PET are related to patient survival in both IPF and other IIPs (paper in preparation). High pulmonary 18F-FDG up-take is associated with poor survival, giving additional information to pulmonary function testing (PFT) and thus, could become a valuable part of the initial work up in newly diagnosed patients.

CONCLUSION

The diagnosis of ILD is a challenging and involved process. It relies on detailed history taking and the integration of various investigations and specialities. The relative rarity of these diseases makes distinguishing subtypes even more difficult for clinicians with a mixed respiratory case workload and

1
2
3 thus, infrequent exposure to ILD. Having said this, the incidence of ILD is increasing and there is
4 potential for specialist centres to become overwhelmed with patients, putting a greater than ever
5 emphasis on collaboration with referring centres and a concerted effort to employ a hub and spoke
6 model. This has the added advantage of facilitating a more patient focussed approach, minimising
7 the need for unnecessary travel and facilitating access to ancillary local services, such as pulmonary
8 rehab, oxygen providers and palliative care services.
9
10

11
12
13 Irrespective of expertise, uncertainty is inherent in the diagnosis of these diseases, although
14 arguably encountering ILD on a frequent basis allows the physician to become more comfortable
15 with these uncertainties, thus embracing the concept of continuous diagnostic review. The hope
16 remains that in time, reliable, non-invasive biomarkers will identify disease subtypes, predict
17 prognosis and potentially replace the need for biopsy. Much of the heterogeneity seen in IPF may be
18 explained by the existence of endotypes, in other words, mechanistically different disease subtypes,
19 which consequently exhibit very different responses to therapy. Future treatments therefore have
20 the potential to be greatly influenced by identifying these groups through the use of genetic testing
21 and a move towards personalised disease management.
22
23
24
25
26
27

28 29 30 31 32 33 34 35 36 37 38 39 40 41 42 43 44 45 46 47 48 49 50 51 52 53 54 55 56 57 58 59 60

References;

1. Lung disease in the UK – big picture statistics | British Lung Foundation [Internet]. Available from: <https://statistics.blf.org.uk/lung-disease-uk-big-picture>
2. Gribbin J, Hubbard RB, Le Jeune I, Smith CJP, West J, Tata LJ. Incidence and mortality of idiopathic pulmonary fibrosis and sarcoidosis in the UK. *Thorax* [Internet]. 2006 Nov [cited 2016 Oct 5];61(11):980–5. Available from: <http://www.ncbi.nlm.nih.gov/pubmed/16844727>
3. Idiopathic Pulmonary Fibrosis Clinical Research Network, Raghu G, Anstrom KJ, King TE, Lasky JA, Martinez FJ. Prednisone, azathioprine, and N-acetylcysteine for pulmonary fibrosis. *N Engl J Med* [Internet]. 2012 May 24 [cited 2016 Jun 10];366(21):1968–77. Available from: <http://www.ncbi.nlm.nih.gov/pubmed/22607134>
4. Tashkin DP, Elashoff R, Clements PJ, Goldin J, Roth MD, Furst DE, et al. Cyclophosphamide versus Placebo in Scleroderma Lung Disease. *N Engl J Med* [Internet]. Massachusetts Medical Society ; 2006 Jun 22 [cited 2016 Oct 5];354(25):2655–66. Available from: <http://www.nejm.org/doi/abs/10.1056/NEJMoa055120>
5. Keir GJ, Maher TM, Ming D, Abdullah R, de Lauretis A, Wickremasinghe M, et al. Rituximab in

- 1
2
3 severe, treatment-refractory interstitial lung disease. *Respirology* [Internet]. 2014 Apr [cited
4 2016 Jan 20];19(3):353–9. Available from: <http://www.ncbi.nlm.nih.gov/pubmed/24286447>
5
6
- 7 6. Oldham JM, Ma S-F, Martinez FJ, Anstrom KJ, Raghu G, Schwartz DA, et al. TOLLIP, MUC5B,
8 and the Response to N-Acetylcysteine among Individuals with Idiopathic Pulmonary Fibrosis.
9 *Am J Respir Crit Care Med* [Internet]. 2015 Dec 15 [cited 2016 Oct 5];192(12):1475–82.
10 Available from: <http://www.ncbi.nlm.nih.gov/pubmed/26331942>
11
12
- 13 7. Raghu G, Collard HR, Egan JJ, Martinez FJ, Behr J, Brown KK, et al. An Official
14 ATS/ERS/JRS/ALAT Statement: Idiopathic Pulmonary Fibrosis: Evidence-based Guidelines for
15 Diagnosis and Management. *Am J Respir Crit Care Med* [Internet]. American Thoracic Society;
16 2011 Mar 15 [cited 2016 Oct 5];183(6):788–824. Available from:
17 <http://www.atsjournals.org/doi/abs/10.1164/rccm.2009-040GL>
18
19
- 20 8. Ohshimo S, Bonella F, Cui A, Beume M, Kohno N, Guzman J, et al. Significance of
21 bronchoalveolar lavage for the diagnosis of idiopathic pulmonary fibrosis. *Am J Respir Crit*
22 *Care Med* [Internet]. 2009 Jun 1 [cited 2016 Oct 5];179(11):1043–7. Available from:
23 <http://www.ncbi.nlm.nih.gov/pubmed/19246718>
24
25
- 26 9. Wall CP, Gaensler EA, Carrington CB, Hayes JA. Comparison of transbronchial and open
27 biopsies in chronic infiltrative lung diseases. *Am Rev Respir Dis* [Internet]. 1981 Mar [cited
28 2016 Oct 5];123(3):280–5. Available from: <http://www.ncbi.nlm.nih.gov/pubmed/7224338>
29
30
- 31 10. Shim HS, Park MS, Park IK. Histopathologic findings of transbronchial biopsy in usual
32 interstitial pneumonia. *Pathol Int* [Internet]. 2010 May [cited 2016 Oct 5];60(5):373–7.
33 Available from: <http://www.ncbi.nlm.nih.gov/pubmed/20518887>
34
35
- 36 11. Babiak A, Hetzel J, Krishna G, Fritz P, Moeller P, Balli T, et al. Transbronchial cryobiopsy: a new
37 tool for lung biopsies. *Respiration* [Internet]. 2009 [cited 2016 Oct 5];78(2):203–8. Available
38 from: <http://www.ncbi.nlm.nih.gov/pubmed/19246874>
39
40
- 41 12. Fruchter O, Fridel L, El Raouf BA, Abdel-Rahman N, Rosengarten D, Kramer MR. Histological
42 diagnosis of interstitial lung diseases by cryo-transbronchial biopsy. *Respirology* [Internet].
43 2014 Jul [cited 2016 Oct 5];19(5):683–8. Available from:
44 <http://www.ncbi.nlm.nih.gov/pubmed/24750376>
45
46
- 47 13. Casoni GL, Tomassetti S, Cavazza A, Colby T V, Dubini A, Ryu JH, et al. Transbronchial lung
48 cryobiopsy in the diagnosis of fibrotic interstitial lung diseases. *PLoS One* [Internet]. 2014
49
50
51
52
53
54
55
56
57
58
59
60

- 1
2
3 [cited 2016 Oct 5];9(2):e86716. Available from:
4 <http://www.ncbi.nlm.nih.gov/pubmed/24586252>
5
6
7 14. Pajares V, Puzo C, Castillo D, Lerma E, Montero MA, Ramos-Barbón D, et al. Diagnostic yield
8 of transbronchial cryobiopsy in interstitial lung disease: a randomized trial. *Respirology*
9 [Internet]. 2014 Aug [cited 2016 Oct 5];19(6):900–6. Available from:
10 <http://www.ncbi.nlm.nih.gov/pubmed/24890124>
11
12
13
14 15. Griff S, Schönfeld N, Ammenwerth W, Blum T-G, Grah C, Bauer TT, et al. Diagnostic yield of
15 transbronchial cryobiopsy in non-neoplastic lung disease: a retrospective case series. *BMC*
16 *Pulm Med* [Internet]. BioMed Central; 2014 Dec 3 [cited 2016 Oct 5];14(1):171. Available
17 from: <http://bmcpulmed.biomedcentral.com/articles/10.1186/1471-2466-14-171>
18
19
20
21
22 16. Fruchter O, Fridel L, Rosengarten D, Raviv Y, Rosanov V, Kramer MR. Transbronchial cryo-
23 biopsy in lung transplantation patients: first report. *Respirology* [Internet]. 2013 May [cited
24 2016 Oct 5];18(4):669–73. Available from: <http://www.ncbi.nlm.nih.gov/pubmed/23294256>
25
26
27
28 17. Kropski JA, Pritchett JM, Mason WR, Sivarajan L, Gleaves LA, Johnson JE, et al. Bronchoscopic
29 cryobiopsy for the diagnosis of diffuse parenchymal lung disease. *PLoS One* [Internet]. Public
30 Library of Science; 2013 [cited 2016 Oct 5];8(11):e78674. Available from:
31 <http://www.ncbi.nlm.nih.gov/pubmed/24265706>
32
33
34
35 18. Pajares V, Torrego A, Puzo C, Lerma E, Gil De Bernabé MA, Franquet T. [Transbronchial lung
36 biopsy using cryoprobes]. *Arch Bronconeumol* [Internet]. 2010 Mar [cited 2016 Oct
37 5];46(3):111–5. Available from: <http://www.ncbi.nlm.nih.gov/pubmed/19939546>
38
39
40
41 19. Jabbardarjani H, Kiani A, Karimi M, Fakhri M. Cryobiopsy shows better safety profile and
42 diagnostic yield as compared to conventional forceps for interstitial lung disease. *Eur Respir J*.
43 2014;42(Suppl 57).
44
45
46
47 20. Hagemeyer L, Theegarten D, Wohlschläger J, Priegnitz C, Treml M, Randerath W.
48 Transbronchial cryobiopsy and open lung biopsy in interstitial lung disease: Comparison of
49 two diagnostic tools. *Eur Respir J*. 2014;42(Suppl 57).
50
51
52
53 21. Johnston ID, Prescott RJ, Chalmers JC, Rudd RM. British Thoracic Society study of cryptogenic
54 fibrosing alveolitis: current presentation and initial management. *Fibrosing Alveolitis*
55 Subcommittee of the Research Committee of the British Thoracic Society. *Thorax* [Internet].
56 BMJ Group; 1997 Jan [cited 2016 Oct 5];52(1):38–44. Available from:
57
58
59
60

- 1
2
3 <http://www.ncbi.nlm.nih.gov/pubmed/9039238>
4
5
6 22. Johnston I, Gomm S, Kalra S, Woodcock A, Evans C, Hind C. The management of cryptogenic
7 fibrosing alveolitis in three regions of the United Kingdom. *Eur Respir J*. 1993;6(6).
8
9
10 23. Morris D, Zamvar V. The efficacy of video-assisted thoracoscopic surgery lung biopsies in
11 patients with Interstitial Lung Disease: a retrospective study of 66 patients. *J Cardiothorac*
12 *Surg* [Internet]. 2014 [cited 2016 Oct 5];9:45. Available from:
13 <http://www.ncbi.nlm.nih.gov/pubmed/24612724>
14
15
16
17 24. Kaarteenaho R. The current position of surgical lung biopsy in the diagnosis of idiopathic
18 pulmonary fibrosis. *Respir Res* [Internet]. BioMed Central; 2013 [cited 2016 Oct 5];14(1):43.
19 Available from: <http://www.ncbi.nlm.nih.gov/pubmed/23587070>
20
21
22
23 25. Maguire MF, Ravenscroft A, Beggs D, Duffy JP. A questionnaire study investigating the
24 prevalence of the neuropathic component of chronic pain after thoracic surgery. *Eur J*
25 *Cardiothorac Surg* [Internet]. 2006 May [cited 2016 Oct 5];29(5):800–5. Available from:
26 <http://www.ncbi.nlm.nih.gov/pubmed/16581259>
27
28
29
30 26. Flaherty KR, Andrei A-C, King TE, Raghu G, Colby T V, Wells A, et al. Idiopathic interstitial
31 pneumonia: do community and academic physicians agree on diagnosis? *Am J Respir Crit*
32 *Care Med* [Internet]. American Thoracic Society; 2007 May 15 [cited 2016 Oct
33 5];175(10):1054–60. Available from: <http://www.ncbi.nlm.nih.gov/pubmed/17255566>
34
35
36
37
38 27. Lynch DA, Godwin JD, Safrin S, Starko KM, Hormel P, Brown KK, et al. High-resolution
39 computed tomography in idiopathic pulmonary fibrosis: diagnosis and prognosis. *Am J Respir*
40 *Crit Care Med* [Internet]. 2005 Aug 15 [cited 2016 Oct 5];172(4):488–93. Available from:
41 <http://www.ncbi.nlm.nih.gov/pubmed/15894598>
42
43
44
45 28. Noble PW, Albera C, Bradford WZ, Costabel U, Glassberg MK, Kardatzke D, et al. Pirfenidone
46 in patients with idiopathic pulmonary fibrosis (CAPACITY): two randomised trials. *Lancet*
47 (London, England) [Internet]. 2011 May 21 [cited 2016 Jun 10];377(9779):1760–9. Available
48 from: <http://www.ncbi.nlm.nih.gov/pubmed/21571362>
49
50
51
52
53 29. Jenkins RG, Simpson JK, Saini G, Bentley JH, Russell A-M, Braybrooke R, et al. Longitudinal
54 change in collagen degradation biomarkers in idiopathic pulmonary fibrosis: an analysis from
55 the prospective, multicentre PROFILE study. *Lancet Respir Med* [Internet]. 2015 Jun [cited
56 2016 Oct 5];3(6):462–72. Available from: <http://www.ncbi.nlm.nih.gov/pubmed/25770676>
57
58
59
60

- 1
2
3 30. Win T, Thomas BA, Lambrou T, Hutton BF, Sreaton NJ, Porter JC, et al. Areas of normal
4 pulmonary parenchyma on HRCT exhibit increased FDG PET signal in IPF patients. *Eur J Nucl*
5 *Med Mol Imaging* [Internet]. 2014 Feb [cited 2016 Jun 28];41(2):337–42. Available from:
6 <http://www.ncbi.nlm.nih.gov/pubmed/23942907>
7
8
9
10
11
12
13
14
15
16
17
18
19
20
21
22
23
24
25
26
27
28
29
30
31
32
33
34
35
36
37
38
39
40
41
42
43
44
45
46
47
48
49
50
51
52
53
54
55
56
57
58
59
60

For Review Only

1
2
3
4
5
6
7
8
9
10
11
12
13
14
15
16
17
18
19
20
21
22
23
24
25
26
27
28
29
30
31
32
33
34
35
36
37
38
39
40
41
42
43
44
45
46
47
48
49
50
51
52
53
54
55
56
57
58
59
60

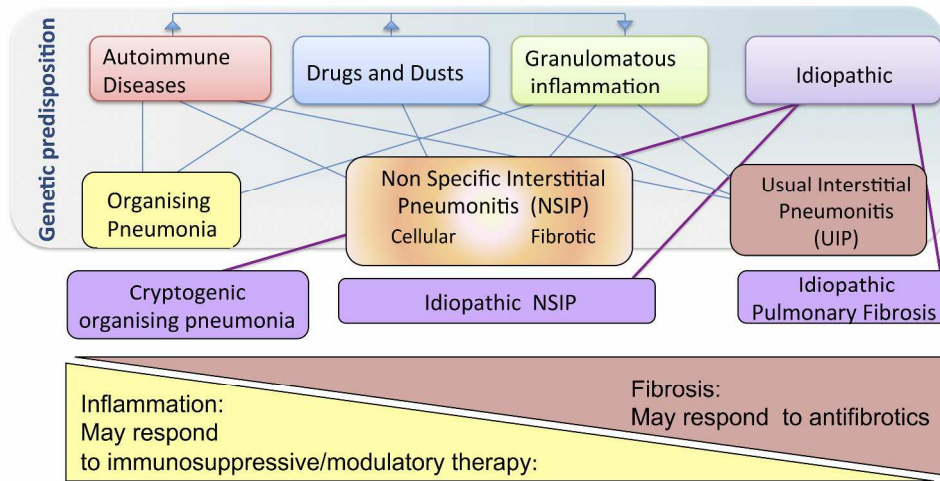


Figure a: Schematic classification of Interstitial Lung Diseases according to aetiology. The finding of histological UIP in a patient with an IIP leads to the specific diagnosis of Idiopathic Pulmonary Fibrosis (IPF)
Figure a

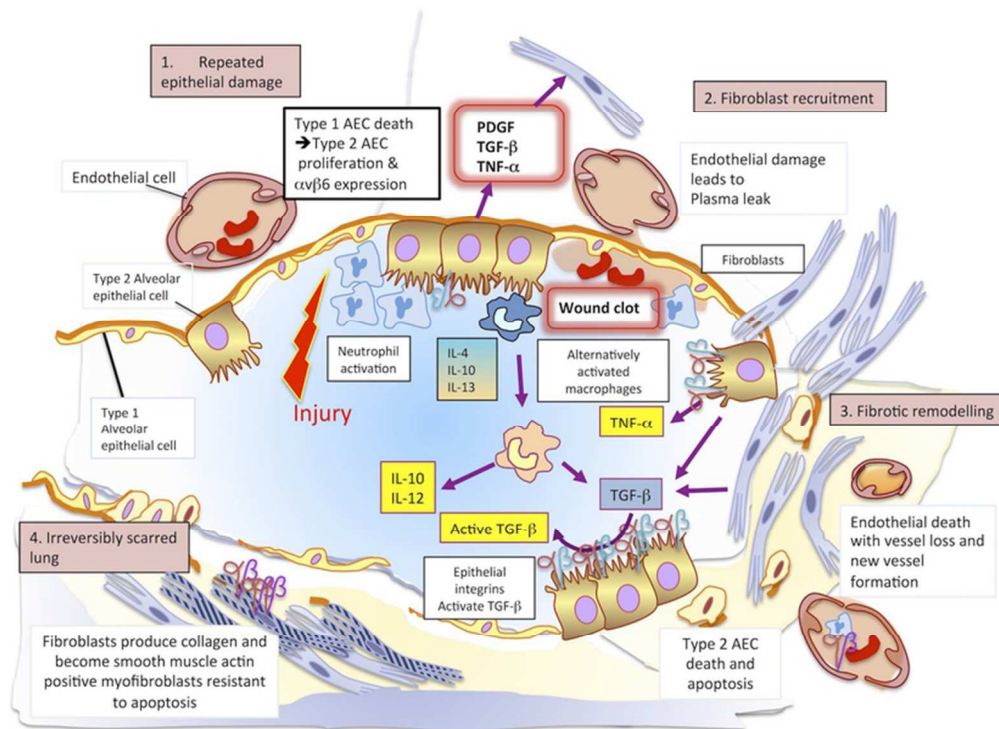


Figure b: The Pathogenesis of IPF. In an initiating phase, there is lung alveolar epithelial damage with loss of the normal lung architecture and disruption of the basement membrane across which gas exchange takes place. With further epithelial damage and apoptosis, comes up-regulation of epithelial integrins such as $\alpha v \beta 6$ and a phase of fibroproliferative repair dominates driven by high levels of TGF β . Released in an inactive form, this cytokine requires an activation step facilitated by integrins that bind the RGD motif of pro-TGF β and promote its cleavage and activation. Locally activated TGF β drives the recruitment of fibroblasts and a feed-forward cycle of further TGF β production. Under these conditions, fibroblasts differentiate into myofibroblasts that express high levels of integrin $\alpha v \beta 6$, are resistant to apoptosis and lay down collagen matrix. Once collagen has been laid down in a lung, the architecture of which is already distorted, gas exchange is no longer efficient. There is a change in the vasculature of the lung parenchyma with both fall-out of blood vessels and neo-angiogenesis driven by local production of vascular endothelial and platelet derived growth factors (VEGF and PDGF). At this final phase the lung is irreversibly scarred.

figure b

34x25mm (600 x 600 DPI)

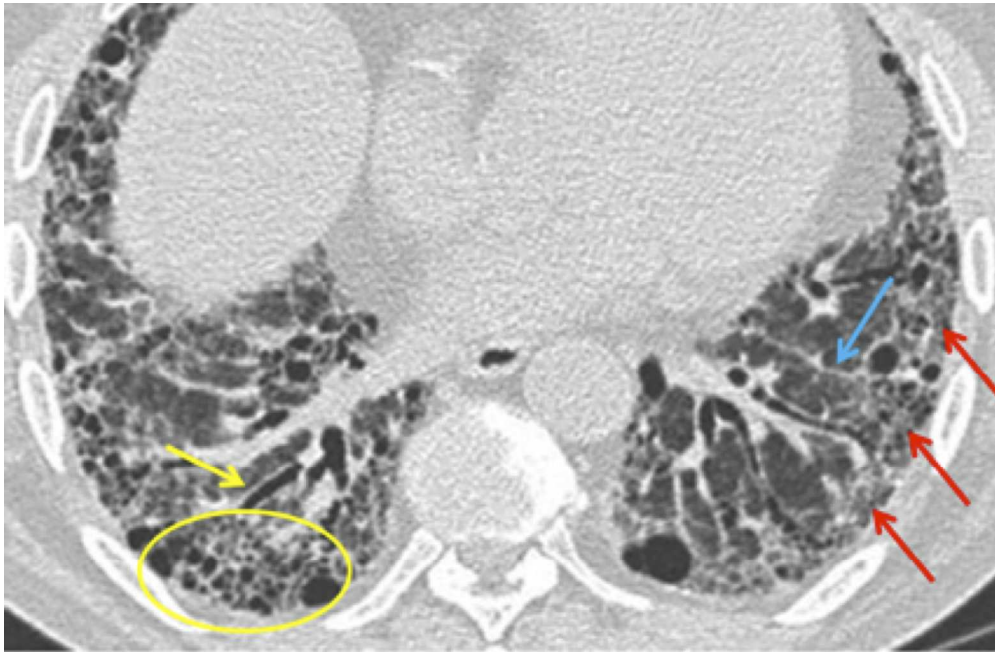


Figure c: Diagnostic criteria for a definite UIP pattern on HRCT:† 1. subpleural, basal predominance; (red). 2. reticular abnormality (blue). 3. honeycombing with or without traction bronchiectasis (yellow). 4. absence of features inconsistent with UIP pattern

Figure c

1
2
3
4
5
6
7
8
9
10
11
12
13
14
15
16
17
18
19
20
21
22
23
24
25
26
27
28
29
30
31
32
33
34
35
36
37
38
39
40
41
42
43
44
45
46
47
48
49
50
51
52
53
54
55
56
57
58
59
60

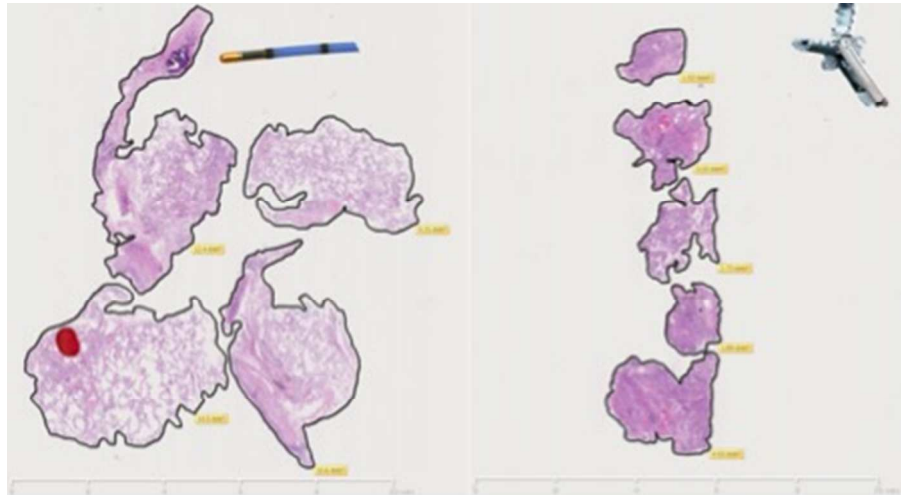


Figure d: Comparison between transbronchial cryo lung biopsy on the left and traditional forceps transbronchial biopsy on the right performed on the same patient at two different sittings. TBCLB shows preserved architecture of parenchymal tissue and a total biopsy area of 46.81 mm² and mean biopsy area of 11.7 mm². TBBx is characterised by crush and haemorrhagic artefact and a total biopsy area of 14.11 mm² and mean biopsy area of 2.8 mm².

Figure d
159x87mm (72 x 72 DPI)

View Only

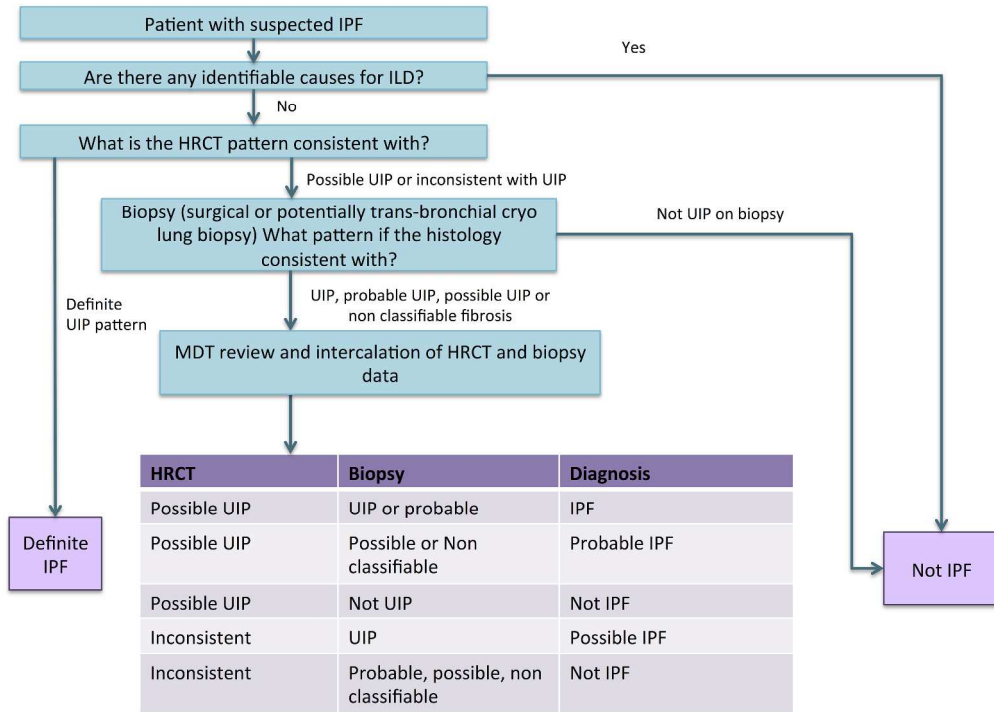


Figure e: Diagnostic algorithm for idiopathic pulmonary fibrosis, in part adapted from the ATS/ERS consensus statement

Figure e

Only

1
2
3
4
5
6
7
8
9
10
11
12
13
14
15
16
17
18
19
20
21
22
23
24
25
26
27
28
29
30
31
32
33
34
35
36
37
38
39
40
41
42
43
44
45
46
47
48
49
50
51
52
53
54
55
56
57
58
59
60

1
2
3
4
5
6
7
8
9
10
11
12
13
14
15
16
17
18
19
20
21
22
23
24
25
26
27
28
29
30
31
32
33
34
35
36
37
38
39
40
41
42
43
44
45
46
47
48
49
50
51
52
53
54
55
56
57
58
59
60

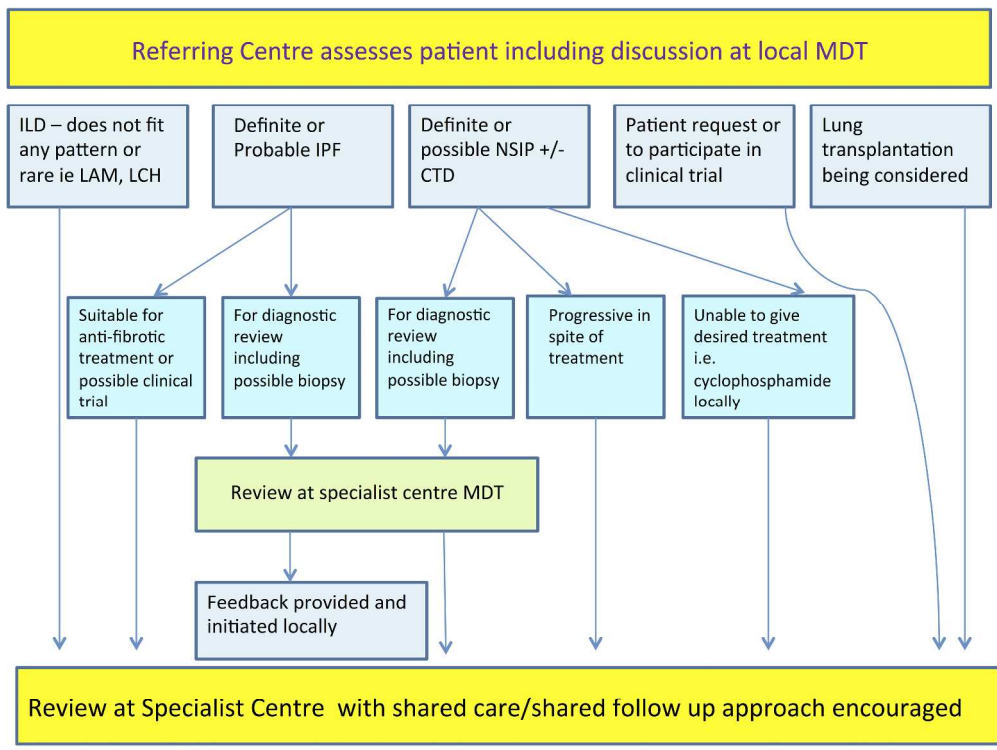


Figure f: The role of Specialist MDTs and Specialist Referral Centres in the diagnosis and management of ILD!! +
Figure f

Only

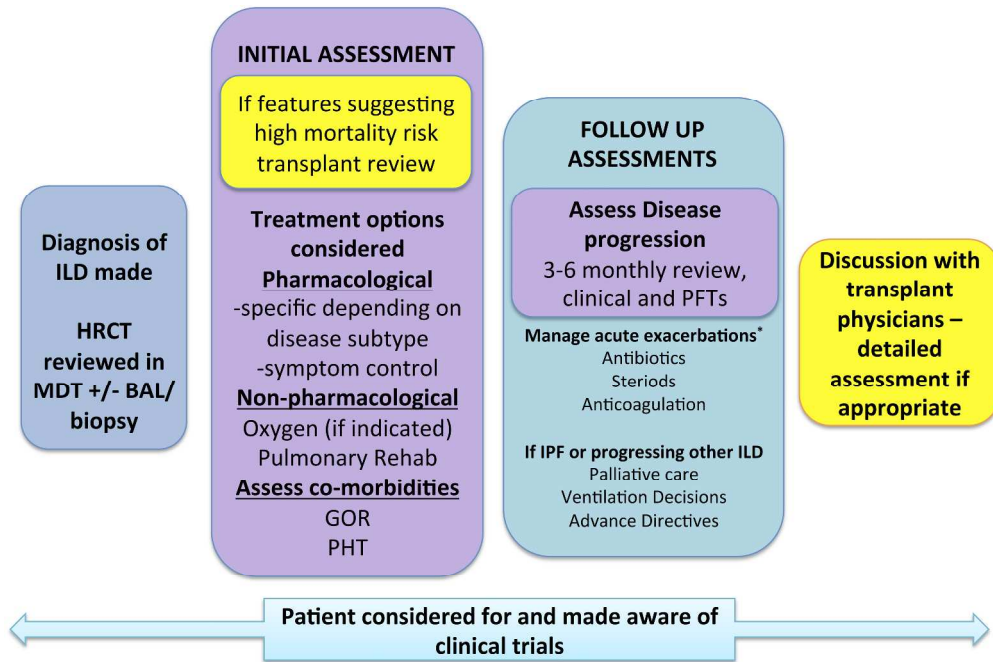


Figure g: Schematic ILD treatment algorithm. *No robust evidence for managing exacerbations with variation between centres, should be discussed with specialist centre if possible. GOR; Gastro-oesophageal reflux. PHT; pulmonary hypertension

Figure g

1
2
3
4
5
6
7
8
9
10
11
12
13
14
15
16
17
18
19
20
21
22
23
24
25
26
27
28
29
30
31
32
33
34
35
36
37
38
39
40
41
42
43
44
45
46
47
48
49
50
51
52
53
54
55
56
57
58
59
60

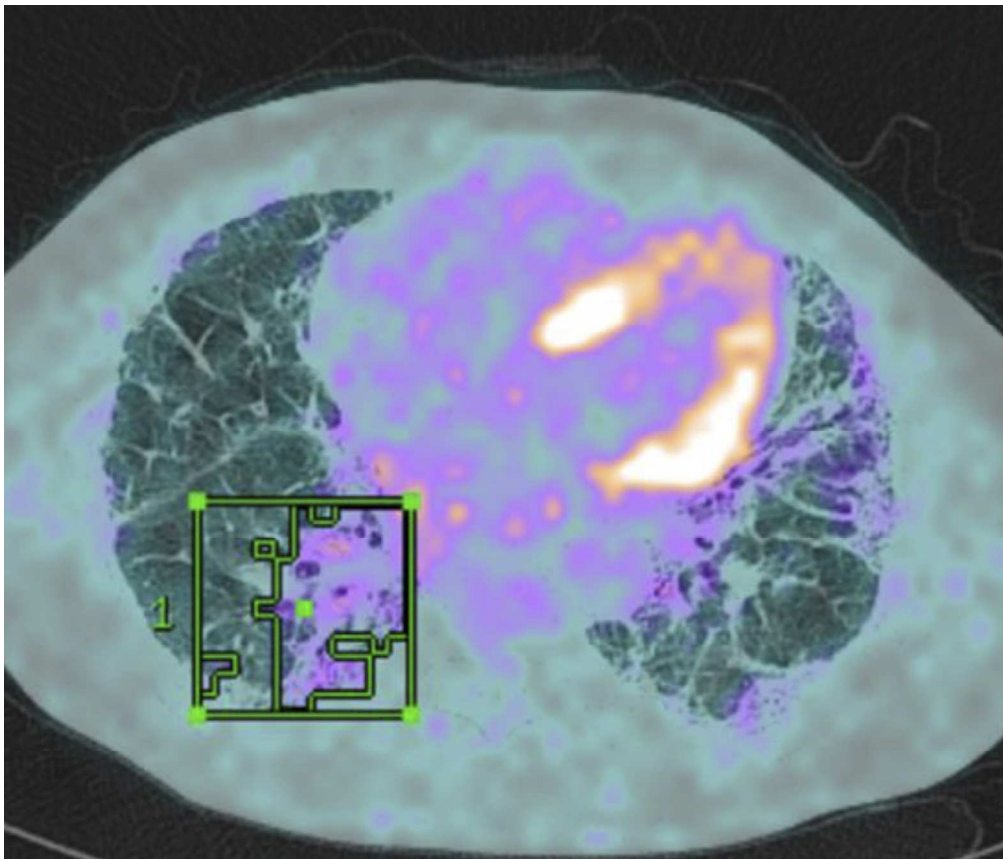


Figure h: PET signal superimposed on HRCT scan of a patient with UIP. A region of interest has been drawn around the area of highest SUV.
figure h

only

Antibody	Associated CTD
ANA (>1:320)	Many
RF (>60 IU/mL)	RA, Sjögrens, SLE
Anti-CCP	RA
Anti-centromere	Systemic sclerosis
Anti-nuclear ANA	Systemic sclerosis
Anti Ro (SS-A)	SLE, Sjögrens and others
Anti La (SS-B)	SLE, Sjögrens
Anti-RNP	SLE, MCTD
Anti-dsDNA	SLE
Anti-Smith	SLE
Anti tRNA synthetase	Poly-/dermatomyositis (anti-synthetase syndrome)
Anti-PM-Scl	Systemic sclerosis/ myositis overlap
Anti-Th/To	Systemic sclerosis
Anti-U3 RNP	Systemic sclerosis
ANCA panel	Vasculitides
Anti topoisomerase (Scl-70)	Systemic sclerosis

Table 1: Autoantibodies in Connective Tissue ILDs

ANA: antinuclear antibody; RF: Rheumatoid Factor; Anti-CCP: anti-cyclic citrullinated peptide antibody anti-RNP: anti-Ribonucleoprotein; anti-dsDNA: anti-double stranded DNA; Anti-PM-Scl: anti polymyositis-scleroderma; ANCA: Anti-neutrophil cytoplasmic antibodies; RA: rheumatoid arthritis; SLE: Systemic lupus erythematosus; MCTD: mixed connective-tissue disease

Optimal HRCT technique for evaluation of ILD

- Non-Contrast scans obtained on full inspiration without respiratory motion
 - Contiguous or non-contiguous axial scans with thin sections, reconstructed at ≤ 2 cm intervals
 - Reconstructed slice collimation ≤ 2 mm
 - High resolution reconstruction algorithm
 - Field of view to include lungs only
 - Expiratory scans are helpful to exclude lobular air trapping suggestive of hypersensitivity pneumonitis
 - Prone scans if dependent density obscures detail on supine images
 - Optional coronal and sagittal reconstructions if volumetric images are obtained
-

Table 2: The ATS/ERS consensus statement for the diagnosis of IPF set out criteria for the optimal HRCT technique for evaluation of ILD¹