

## **Postgraduate Examination Skills: Clubbing**

### **Introduction**

The original description of clubbing was by Hippocrates in the fifth century B.C. in a patient with empyema. Clubbing came into the spotlight again in the 19<sup>th</sup> century when Eugen Bamberger and Pierre Marie described hypertrophic osteoarthropathy which is a frequently concomitant disorder. By the end of World War I clubbing was known to most physicians, usually as an indicator of chronic infection (Mangione, 2000). Clubbing, the focal enlargement of the connective tissue in the terminal phalanges, is associated with a plethora of infectious, neoplastic, inflammatory and vascular conditions and the diagnostic implications of this sign are such that its presence should not go unnoticed or uninvestigated (see fig.1). As well as being associated with a host of conditions, in a paediatric setting, clubbing can indicate chronic conditions like cystic fibrosis or cyanotic forms of congenital heart disease. However it is also important to remember that clubbing can be a benign sporadic hereditary condition (Myers and Farquhar, 2001).

### **Clinical Anatomy and Pathophysiology**

The dorsal portion of the distal phalanges are covered by a protective hard keratin cover, the nail plate. This is formed by nail matrix at the proximal end of the nail plate, creating the superficial layers whilst the nail matrix at the distal end creates the deeper layers. Any impairment in this production causes a distortion of the nail. For example disruption of production at the proximal end leads to superficial nail problems such as psoriatic pitting, and disruption of production at the distal end leads to deeper problems like ridging of the nail. A transient health problem during development of the nail plate leads to a transverse line across the nail – (Beau's line) (Fawcett *et. al.*, 2004).

Clubbing develops when there is increased vascularity in the nail bed leading to hyperplasia of fibrous tissue and oedema. This causes a thickening of the tissue beneath the nail plate giving the diagnostic criteria of loss of the hyponychial angle, fluctuance of the nail bed and the abnormal phalangeal depth ratio (Lancet editorial, 1975). It is usually painless and can involve both fingers and toes but can also be unilateral in certain conditions, for example arterial aneurysms and Pancoast's tumour and in some cases is even unidigital (Mangione, 2000).

Despite physicians' awareness of clubbing for centuries, the pathogenesis of the sign is still poorly understood. Mendlowitz *et. al.* showed that under conditions of maximal vasodilatation there is increased heat elimination from the fingertip and accelerated clearance of Krypton-85 after injection into the finger pulp, thereby deducing that the increased blood supply to clubbed fingers exceeds

tissue requirements (Lancet editorial, 1975). Currie and Gallagher studied post-mortem angiograms and concluded that this increased vascularity is a result of vasodilatation, not hyperplasia of vessels, as there were no anatomical differences between clubbed and control cases (Currie and Gallagher, 1988). Rush *et. al.* (1992) used thermography to show a rise in temperature by half a degree in clubbed fingers and Ward *et. al.* (1995) documented a higher glucose metabolism in clubbed fingers using positron emission tomography. These observations suggest that in patients with clubbing there is increased blood flow and metabolism within the distal phalanges.

Tissue hypoxia and genetic factors (such as those seen in familial clubbing) have both been suggested as the underlying cause (Shneerson, 1981). The 'neural reflex' theory suggests that the vagus nerve has a pivotal role in the aetiopathogenesis of clubbing. Afferent impulses travel via the vagus nerve from the inciting focus e.g. a lung malignancy to the central nervous system, then via an unknown efferent path vascular changes are mediated leading to hypertrophy of the fibroconnective tissue. In some patients with inoperable bronchial carcinoma, division of the vagus nerve resulted in regression of clubbing (McPhee, 1990). The 'toxic substance' theory suggests that a substance normally deactivated by the lungs is shunted and able to selectively act on the peripheral vasculature as a vasodilator. Substances implicated in this theory include oestrogens, ferritin, prostaglandins and growth hormone (Currie and Gallagher, 1988). The release of platelet-derived growth factor (PDGF) following impaction of megakaryocytes and platelets in the peripheral vasculature has also been suggested, as PDGF causes increased permeability of capillaries, fibroplastic activity and hyperplasia of smooth muscle. Fox, Day and Gatter (1991) found evidence to support this theory by finding platelet microthrombi in patients with clubbing.

### **Examining the hands**

Clubbing has three diagnostic features:

1. Loss of the hyponychial angle
2. Fluctuance of the nail
3. Abnormal phalangeal depth ratio

In the past, many methods have been used to try to diagnose clubbing including water displacement, measurement of nail curvature using an unguisometer (which measures depth of indentation in mm (Chord-Arc distance)), and measuring angle and ratios using plaster casts and shadow projections. However, the two most used methods are visual inspection and palpation of the cuticle for a 'spongy' nail bed. Aside from the obvious increase in connective tissue there is also a

shiny, smooth cuticle on observation and a lilac hue of the nail fold has also been described resulting from vasodilatation (Myers and Farquhar, 2001).

The hyponychial angle is the angle between the nail base and its surrounding skin. It can be assessed by placing a pencil on the finger resting over the nail. In a normal person this angle is less than  $188^\circ$  and in clubbed fingers the angle exceeds  $192^\circ$  (Moreira *et al.*, 2006).

### Make a figure of angles – fig 2

Fluctuance of the nail is increased sponginess of the soft tissue at the nail base causing the nail plate to develop a 'springy' feeling. If the skin proximal to the nail is compressed the nail moves away from the compression and returns once the pressure is removed giving the sensation of a floating nail bed (Mangione, 2000). In advanced cases the proximal edge of the nail may even be felt. The sign is elicited effectively by holding the sides of the finger with the examiner's thumb and middle finger and using their index finger to gently rock the nail using the nail bed as a fulcrum (Myers and Farquhar, 2001).

The phalangeal depth ratio is calculated by comparing the depth of the finger at the base of the nail (the distal phalangeal depth), and the interphalangeal joint (the interphalangeal depth). The ratio in a normal individual is on average 0.895. As connective tissue accumulates, the pulp of the finger expands and reverses the ratio. So patients with clubbing have a ratio of 1 or more (Mangione, 2000).

In 1976 Schamroth, reported a clinical sign (eponymously called Schamroth's sign) that incorporates two of the diagnostic features of clubbing after noticing the sign on himself while suffering from recurrent episodes of endocarditis. Normally if the dorsal surfaces of similar fingers are juxtaposed a diamond shaped window is seen between the two nailbeds. However in clubbing the loss of the hyponychial angle obliterates the diamond window. This technique has become popular with physicians as it is quick and easy to do in a bedside examination (Mangione, 2000) (see fig.2).

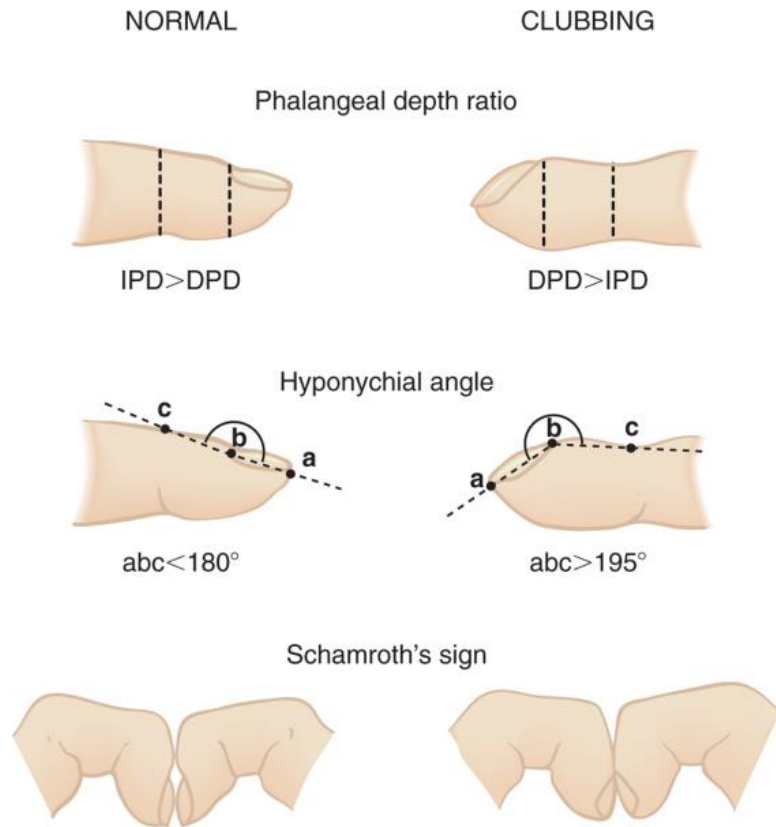


Fig. 2

Clubbing can be graded in the following way (table 1):

Grade	Description
I	Fluctuation and softening of the nail bed
II	Loss of the hyponychial angle
III	Accentuated convexity of the nail
IV	Fingertip develops a clubbed appearance
V	Nail and surrounding skin develops a glossy change with longitudinal striations of the nail.

### Reliability of these methods

The accuracy of the techniques described above to detect clubbing has not been formally established but the literature indicates that interobserver agreement is only fair to moderate. Although impractical in most cases, if clubbing is suspected, using callipers at the bedside to elicit the phalangeal depth ratio may be the most reliable test as it has good sensitivity and specificity. A ratio greater than 1 was found in 85% of children with cystic fibrosis and in fewer than 5% of children with chronic asthma, a disease not commonly associated with clubbing of the fingers (Mangione,2000). Furthermore, such measurements have been used in an attempt to establish if the degree of clubbing is predictive of its aetiology. Myers and Farquhar (2001) found that while a normal depth ratio does not exclude lung cancer, an abnormal ratio implies an increased probability

of underlying malignancy (likelihood ratio =3.9, 95%CI =1.6-9.4). Pallarés-Sanmartin *et. al.* (2010) looked at the inter-observer validity and reliability of the Schamroth sign and found it had a sensitivity of 77-87% and a specificity of 90%. This led them to conclude that the technique is a reasonably accurate method for diagnosing clubbing and the most practical at the bedside.

### Causes

Clubbing is classified as being idiopathic or acquired. There are two forms of idiopathic clubbing. The hereditary form becomes apparent during childhood and persists lifelong and is inherited in an autosomal recessive pattern (Tariq *et. al.*, 2009). The second form is associated with hypertrophic osteoarthropathy and is characterised by clubbing, skin changes and periostitis, hence its other name of pachydermoperiostosis (Peerbhoy *et. al.*, 2006).

Conditions associated with acquired clubbing - common causes seen in the PACES exam are highlighted in bold (see table 2):

System	Causes (Prevalence)	Other Clinical Features
<b>Respiratory</b>	<b>Cystic fibrosis</b>  <b>Bronchiectasis</b>  Lung abscess Empyema  Chronic mycobacterial or fungal infection <b>Pulmonary fibrosis (65%)</b>  Pneumoconiosis  Asbestosis  <b>Bronchial carcinoma (29%)</b>  Mesothelioma  Pleural fibroma	Young age, Bowel obstruction Recurrent chest infections Dyspnoea, Disabling cough, Profuse green/yellow sputum Cough, Fever, Night sweats Systemically unwell, 'stony dull' on percussion Cough, Spiking fevers Chronic dry cough, Coarse 'late inspiratory' bibasal crackles Dry cough, Fine inspiratory crackles Dyspnoea, Pleuritic pain Dyspnoea, Haemoptysis, Cachexia As above Chest pain
<b>Cardiovascular</b>	<b>Cyanotic congenital heart disease</b> Infective endocarditis  Arterial graft sepsis Atrioventricular malformation Arteriovenous fistula Atrial myxoma	Cyanosis, Heart murmur Fever, New or changing heart murmur, Septic embolism Fever, Rigors Left parasternal heave Palpable thrill over fistula Platypnoea, Dizziness, Palpitations

Gastrointestinal	<b>Inflammatory bowel disease (15-38%)</b> Oesophageal carcinoma	Abdominal pain, Change in bowel habit, Weight loss Dysphagia and Odynophagia
Hepatobiliary	<b>Cirrhosis (esp. primary biliary cirrhosis) (24%)</b> <b>Chronic active hepatitis (29%)</b>	Jaundice, Feter hepaticus, Ascites Weight loss, easy bruising and ascites
Endocrine	Thyroid acropachy (20%)	Swelling of whole finger or toe, ophthalmoplegia
Other	Thalassaemia Hodgkin's lymphoma Metastatic osteogenic sarcoma	Anaemia Night sweats, Splenomegaly Pathological Fractures, Bone pain

### **Investigations and Management**

As clubbing has such a wide differential it is important that a full and complete history and clinical examination is carried out, as that will focus investigations in most cases. It is important to note onset of clubbing as a recent presentation of the sign will indicate a need for more intensive investigation. Specific management is then dictated by the underlying cause of the clubbing (Llewelyn et. al., 2009).

### **Conclusion**

Although clubbing can be a benign incidental finding on examination with no underlying pathology the possibility of sinister causes should prompt a thorough history and investigations. The sign can be readily observed at the bedside and simple techniques can confirm its presence and its prompt diagnosis and subsequent investigations could make all the difference in a patient's care.

#### **Key Points**

- Clubbing has three diagnostic features:
  - loss of the hyponychial angle
  - fluctuance of the nail
  - an abnormal phalangeal depth ratio
- There is increased vascularity leading to hyperplasia of fibrous tissue and oedema causing thickening of the tissue in the finger pulp.
- Underlying aetiopathogenesis is still unclear.
- Clubbing can be diagnosed at the bedside. Inter-observer agreement is fair to moderate. Measuring the phalangeal depth ratio with callipers is the most accurate technique to confirm the diagnosis.

## References

1. Currie and Gallagher (1988): **The pathology of clubbing: vascular changes in the nail bed.** *British Journal of Diseases of the Chest*, **82**:382
2. Editorial (1975 Jun 7). **Finger Clubbing.** *Lancet* , 1(7917):1285
3. Fawcett *et. al.*, (2004): **Nail abnormalities: Clues to Systemic Disease.** *American Family Physician*, **69**(6): 1417-24
4. Fox, Day and Gatter (1991, Aug 3): Association **between platelet microthrombi and finger clubbing.** *Lancet*, **338**(8762): 313-4
5. Llewelyn *et. al.* (2009): **General and endocrine symptoms and physical signs.** In Oxford Handbook of Clinical Diagnosis, 2<sup>nd</sup> Ed, Edited by Llewelyn H, Aun Ang H, Lewis K, Al-Abdullah A, Oxford University Press; 72-73
6. Mangione (2000): **The Extremities.** In *Physical Diagnosis Secrets*, 1<sup>st</sup> Ed, Edited by Mangione S, Hanley & Belfus, Inc; 482-486
7. McPhee (1990): **Clubbing.** In *Clinical Methods: The History, Physical and Laboratory Examinations.* 3<sup>rd</sup> Ed, Edited by Walker HK, Hall WD, Hurst JW, Butterworth Publishers
8. Moreira *et. al.*, (2008): **Clubbed Fingers: Radiological evidence of the nail bed thickness.** *Clinical Anatomy*, **21**:314-318
9. Myers and Farquhar (2001): **Does this patient have clubbing?** *Journal of the American Medical Association*, **286**(3):341-347
10. Pallarés-Sanmartin *et. al.*, (2010): **Validity and Reliability of the Schamroth sign for the diagnosis of clubbing.** *Journal of the American Medical Association*, **304**(2):159-161
11. Peerbhoy *et. al.*, (2006): **Idiopathic Clubbing.** *Journal of Association of Physicians of India*, **54** : 506
12. Rush *et al.* (1992): **The use of thermography in clubbing.** *Respiratory Medicine*, **86**: 257-259

13. Schneerson (1981): **Digital Clubbing and Hypertrophic Osteoarthropathy: the underlying mechanisms.** *British Journal of Diseases in the Chest*, **75**:113-131
14. Tariq et. al. (2009): **Mutation in the HPGD gene encoding NAD<sup>+</sup> dependant 15-hydroxyprostaglandin dehydrogenase underlies isolated congenital nail clubbing.** *Journal of Medical Genetics*, **46**:14-20
15. Ward et. al. (1995): **Digital Clubbing. Demonstration with positron emission tomography.** *Chest*, **107**:1172-1173