

# **Egocentric vs. allocentric spatial memory in behavioural variant frontotemporal dementia and Alzheimer's disease**

Sicong Tu<sup>1,2,3</sup>, Hugo J. Spiers<sup>4</sup>, John R. Hodges<sup>1,3</sup>, Olivier Piguet<sup>1,3</sup>, Michael Hornberger<sup>3,5</sup>

<sup>1</sup> Brain and Mind Centre, Sydney Medical School, University of Sydney, Sydney, Australia.

<sup>2</sup> FMRIB, Nuffield Department of Clinical Neurosciences, Oxford University, Oxford, United Kingdom.

<sup>3</sup> Australian Research Council Centre of Excellence in Cognition and its Disorders, Sydney, Australia.

<sup>4</sup> Institute of Behavioural Neuroscience, Department of Experimental Psychology, University College London, London, United Kingdom.

<sup>5</sup> Norwich Medical School, University of East Anglia, Norwich, United Kingdom.

**Running Title: Spatial Representation in bvFTD/AD**

**Corresponding author:**

Prof. Michael Hornberger

Norwich Medical School, University of East Anglia, Norwich, NR47UQ, United Kingdom

Tel: +44 (0)1603 597139

[m.hornberger@uea.ac.uk](mailto:m.hornberger@uea.ac.uk)

## **Abstract**

**Background:** Diagnosis of behavioural variant frontotemporal dementia (bvFTD) can be challenging, in particular when patients present with significant memory problems, which can increase the chance of a misdiagnosis of Alzheimer's disease (AD). Growing evidence suggests spatial orientation is a reliable cognitive marker able to differentiate these two clinical syndromes.

**Objective:** Assess the integrity of egocentric and allocentric heading orientation and memory in bvFTD and AD, and their clinical implications.

**Method:** A cohort of 22 patient with dementia (11 bvFTD; 11 AD) and 14 healthy controls were assessed on the virtual supermarket task of spatial orientation and a battery of standardized neuropsychological measures of visual and verbal memory performance.

**Results:** Judgements of egocentric and allocentric heading direction were differentially impaired in bvFTD and AD, with AD performing significantly worse on egocentric heading judgements than bvFTD. Both patient cohorts, however, showed similar degree of impaired allocentric spatial representation, and associated hippocampal pathology.

**Conclusions:** The findings suggest egocentric heading judgements offer a more sensitive discriminant of bvFTD and AD than allocentric map-based measures of spatial memory.

**Keywords:** orientation, hippocampus, frontotemporal dementia, Alzheimer's disease

## **Introduction**

Alzheimer's disease (AD) and the behavioural variant of frontotemporal dementia (bvFTD) are two neurodegenerative dementia conditions with distinct and overlapping cognitive and pathological features [1,2]. For a long time differences in memory performance have been proposed to be a key clinical feature in the early differential diagnosis of bvFTD and AD, with AD patients expressing greater memory deficits than bvFTD patients [3,4]. Growing evidence, however, shows that bvFTD patients exhibit considerable variability in memory function, resulting in a misdiagnosis of AD [5,6]. This may be a result of significant hippocampal pathology, which has also been reported in bvFTD [7,8]. Nevertheless, posterior regions of the brain, in particular, the posterior cingulate and parietal lobe remain relatively intact in sporadic bvFTD, but are affected in the early stages of AD [9,10]. This has important implications for the neural basis of spatial memory and the development of neuro-anatomically targeted cognitive tools to aid in differential diagnosis of dementia syndromes.

Spatial disorientation is a prominent feature in the early stages of Alzheimer's disease (AD), but tends to be preserved in frontotemporal dementia (FTD) [6,11-15]. Increasing evidence shows that spatial orientation is a sensitive diagnostic discriminant of AD and bvFTD [11,12], while episodic memory performance can vary significantly [5,6,16,17]. While the diagnostic accuracy of AD and bvFTD can be significantly improved when considering spatial orientation in conjunction with established memory measures [11,12], orientation is rarely assessed objectively as part of routine cognitive screenings in dementia. An outstanding question is how can orientation best be used to differentially diagnose AD and bvFTD in a generalized clinical setting?

Spatial orientation requires the representation of the spatial relationships among separate entities in the world. Information can be referenced with respect to the body (egocentric representations) or with respect to invariant landmarks in the environment (allocentric representations) [18]. The posterior parietal cortex has been implicated in coding egocentric information and a circuit involving the hippocampus and parahippocampal structures has been argued to support allocentric representations, with the retrosplenial cortex thought to mediate both frameworks of spatial information processing [18,19]. In particular the hippocampus has been argued to form an internal map of space to support long-term memory for space and events occurring in them [18]. While spatial navigation has been studied in AD and its prodromal stage [20], with a variety of tasks adapted for patient testing [21-23], bvFTD patients' spatial abilities have rarely been examined [11]. This is likely due to the lack of observed spatial memory impairment in bvFTD reported in the clinic. When considered in the context of differential diagnosis with AD, however, this feature becomes highly relevant.

Assessments of spatial navigation tapping into both egocentric and allocentric processing have been extensively studied in AD, with tasks drawing upon newly acquired [21,24] or existing spatial information [23]. Patients with an AD diagnosis have been consistently reported impaired on spatial orientation task [20], with a selective deficit in the translation of information between egocentric and allocentric information [23], resulting in an impaired ability to make accurate judgement of heading direction [11]. This finding corroborates with reports of significant topographical disorientation in community dwelling AD patients, placing a significant level of burden on caregivers [13]. In bvFTD, however, this does not appear to be the case [11,14,21,25]. Previous studies of spatial navigation in FTD involved the semantic language variant, who performed at a comparable level to healthy controls on tasks requiring egocentric

and allocentric based spatial memory [14,21,25]. Of greater clinical interest is comparative spatial processing ability between AD and bvFTD, given the difficulty of diagnosis in the earliest stages when behavioural symptoms remain mild.

To our knowledge, previous work by our group provides the only characterisation of egocentric spatial processing in bvFTD patients [11]. Whether bvFTD patients also show hippocampal-dependent allocentric spatial memory deficits remains unknown. To address this question we used an ecological virtual supermarket environment, which does not require prior learning or training, to assess judgements of egocentric heading direction in AD and bvFTD. Spatial orientation performance using the virtual supermarket task has been shown to hold the same level of sensitivity as episodic memory in differentiating between AD and bvFTD patients, with significantly increased diagnostic accuracy when the two variables were considered in combination [11]. In the current study, the virtual supermarket task was employed with a novel spatial layout component to compare egocentric and allocentric spatial processing in AD and bvFTD. Structural neuroimaging was carried out in combination to assess the impact of hippocampal pathology on spatial memory in these two patient cohorts.

## **Method**

### **Participants**

Twenty two dementia patients (11 AD; 11 bvFTD) and 14 age-matched healthy controls were recruited from the Sydney frontotemporal dementia research group (FRONTIER) database. All participants were assessed at the FRONTIER clinic located at Neuroscience Research Australia, Sydney. Study approval was provided by the South Eastern Sydney Local Health District and the

University of New South Wales human research ethics committees. All participants provided signed consent for neuropsychological assessment and neuroimaging prior to testing. All dementia patients fulfilled international consensus criteria for AD [26] and bvFTD [2]. Clinical diagnoses were established by consensus among senior neurologist, occupational therapist and neuropsychologist, based on a clinical interview, comprehensive neuropsychological assessment, and evidence of brain atrophy on structural neuroimaging. All bvFTD patients showed disease progression as well as atrophy on scans to exclude any phenocopy cases [27]. Participant demographics and clinical characteristics were recorded.

Exclusion criteria for all participants included prior history of mental illness, head injury, movement disorders, alcohol and drug abuse, limited English proficiency, and, for controls, presence of abnormality on MRI. Participants were administered a battery of cognitive tests to assess overall cognitive function, verbal and visual memory, and working memory. This assessment included: Addenbrooke's Cognitive Examination-Revised (ACE-R), Rey Auditory Verbal Learning Test (RAVLT), Rey Complex Figure Test (RCFT), and Digit Span. For a brief description of cognitive tasks see Supplementary Table 1.

### **Virtual supermarket task**

Spatial orientation was assessed using an ecological virtual supermarket task consisting of 14 video trials [11], based on a small-scale supermarket environment [28] (Fig. 1A). Videos were presented from a first person perspective and involved travelling to set locations within the supermarket while making a series of 90 degree turns. All trials began at the same location, but followed different routes to reach their respective end locations. Video trials were standardized for length and number of turns, such that half of the trials lasted 20s with 3 turns, while the other half lasted 40s with 5 turns. All video trials were presented in a randomized order across

participants. At the end of each trial, participants were prompted to make a judgement of heading direction from the new location relative to the starting location based on egocentric body turns (Fig. 1A). Critically, correct judgements of direction cannot be made from simply viewing the image of the new location at the end of each video trial. Building upon a previous study using this task [11], participants are then presented with a spatial map of the supermarket environment, with starting location marked, and asked to indicate current location and heading direction. This requires participants to translate their current view to a map coordinate and orientation, thus drawing upon allocentric spatial representations (Fig. 1B).

---INSERT FIGURE 1 AROUND HERE---

Prior to testing, participants were explicitly instructed that they would be viewing a number of short videos that involved moving to new locations within the supermarket and were required to make a judgement of heading direction and location relative to the original starting location. A single practice video trial (10 s, 2 turns) was provided at the start of testing to introduce participants to the virtual supermarket environment and make clear task instructions were understood. No further training is provided. Consequently, the formulation of a working internal spatial representation of the immediate environment for making judgements of direction and location [29] reflects incidental acquisition present in everyday spatial navigation. Correct judgements of heading direction required participants to accurately distinguish whether the relative starting location, either verbally or physically (i.e. point in a direction), was in front/behind and to the left/right of their current location using an egocentric, followed by an allocentric framework. For spatial location, locations marked within a 4 mm radius of the correct location were considered to be correct, which was determined to be the average discrepancy from the correct location during pilot testing in healthy controls. In addition, the Euclidean

distance between the participants' response and the correct location was measured, as was the mean Euclidean distance between all marked locations and the centre of the spatial map. The mean Euclidean distance to the centre was used to examine any bias in the responses, such as would occur if responses were clustered in the middle or edges of the map.

### **Statistical Analyses**

Differences in participant groups, were assessed using SPSS 21.0 (IBM Corp., Armonk, NY). Kolmogorov-Smirnov tests were run to determine the suitability of variables for parametric analyses. Kruskal-Wallis tests, followed by post-hoc Mann-Whitney tests were used to analyze participant performance on the ACE-R, RAVLT. Analysis of variance (ANOVA) and two-tailed post hoc multiple comparisons were carried out between participant group demographics, and RCFT and Digit Span cognitive measures. Spatial performance on the experimental task was assessed using multivariate analysis of covariance (MANCOVA) and two-tailed post-hoc multiple comparisons to compare performance between groups while taking into account degree of memory impairment on standard cognitive measures of verbal and visual memory performance. In all analyses,  $p$  values  $< 0.05$  were considered statistically significant.

### **Imaging Acquisition**

Whole-brain structural T1 images were acquired for all participants using a 3T Philips MRI scanner with standard quadrature head coil (eight channels). Structural T1 scans were acquired as follows: coronal orientation, matrix 256 x 256, 200 slices, 1mm isotropic, TE/TR = 2.5/5.4 ms, flip angle  $\alpha = 8^\circ$ . Prior to analyses, all participant scans were visually inspected for significant head movements and artefacts, and excluded from imaging analyses. All scans were examined by a radiologist for structural abnormalities.

### **Imaging Analyses**



Voxel-based morphometry (VBM) was conducted on whole-brain T1-weighted scans, using the VBM toolbox in FMRIB's Software Library (FSL; <http://www.fmrib.ox.ac.uk/fsl/>). First, the brain was extracted from each scan using FSL's BET algorithm with a fractional intensity threshold of 0.22 [30]. Each scan was visually checked following brain extraction to ensure no brain matter was excluded, and no non-brain matter was included. A study specific template of grey matter was generated from 11 scans for each participant cohort. An equivalent number of scans from each cohort were used to create the template, avoiding potential bias towards any single group's topography during registration. Template scans were then registered to the Montreal Neurological Institute (MNI) standard brain (MNI 152), resulting in a study-specific grey matter template at 2 mm<sup>3</sup> resolution in MNI standard space. Simultaneously, participant brain-extracted scans were segmented into CSF, grey matter and white matter using FMRIB's Automatic Segmentation Tool (FAST) [31]. The FAST algorithm corrected scans for spatial intensity variations such as bias field or radio-frequency inhomogeneity, resulting in partial volume maps. Grey matter partial volume maps were then non-linearly registered to the study-specific template. After normalization and modulation, grey matter maps were smoothed using an isotropic Gaussian kernel ( $\sigma = 3$  mm).

Region of interest analyses of the hippocampus and retrosplenial region (Brodmann areas 29/30) located at the tail of the posterior cingulate were carried out between each patient group and controls, as well as between AD and bvFTD cohorts. The accuracy of volumetric examination of the retrosplenial cortex itself is insufficient using standard 3T clinical scans. These two regions were examined based on a priori evidence of spatial memory deficits linked to these regions [32]. Grey matter volumes were extracted with reference to the Harvard-Oxford subcortical and cortical structural atlases, and correlated with spatial orientation performance.

ANOVA and two-tailed post-hoc multiple comparisons were carried out between participant cohorts with years of education included as a confounding covariate. Scans were spatially normalized to a common group template during the FSL-VBM processing pipeline, which corrects for difference in participant intra-cranial volume.

## **Results**

### **Demographics**

Participant demographics and clinical characteristics are provided in Table 1. Briefly, AD patients presented with predominantly episodic memory impairment with preserved social behaviour. BvFTD patients demonstrated changes in social functioning, loss of insight, disinhibition and increased apathy. AD and bvFTD patient cohorts were well matched on demographic variables, including age, education, and disease duration and functional severity (Table 1; all p values > 0.2). The healthy control cohort was matched for age (p values > 0.7), but demonstrated higher mean years of education compared to bvFTD patients (p value = 0.013). ANOVA of participant groups' performance across standard cognitive tests revealed significant group differences for all components (all p values < 0.03). Between patient groups, bvFTD showed a better cognitive profile on the ACE-R compared to AD (Total: U = 28, p = 0.032; Memory: U = 13.5, p = 0.002; Orientation: U = 24.5, p = 0.015), and verbal memory recall on the RAVLT (T1-5: U = 9.5, p = 0.011; 30 min: U = 8.5, p = 0.007). The two patient groups, however, did not differ on visual memory and working memory as indicated by the RCFT (all p values > 0.1) and digit span (all p values > 0.6), respectively. Compared to controls, AD performed significantly worse on all cognitive test components (all p values < 0.05). BvFTD

showed a similar pattern of impairment. Performance was, however, not significantly worse for recognition on the RAVLT, compared to controls.

---INSERT TABLE 1 AROUND HERE---

### **Spatial Orientation Performance**

Heading orientation was scored for a correct judgement of direction to the starting location at the end of each trial using egocentric and allocentric frameworks on the first-person and spatial map components of the virtual supermarket task, respectively (Fig. 2). MANCOVA indicated significant group differences across both conditions (all p values < 0.03). Compared to controls, AD performed significantly worse on both conditions (all p values < 0.05), however, bvFTD were impaired only in the allocentric condition (p value = 0.02). Within patient groups, AD performed significantly worse than bvFTD in both conditions of heading orientation (all p values < 0.05).

---INSERT FIGURE 2 AROUND HERE---

Spatial representation was scored for correct indication of location and distance from correct location for each trial on the supermarket layout (Fig. 3). MANCOVA indicated significant group differences across both conditions (all p values < 0.02). Patient groups were impaired in locating the correct location on each trial, and distance from the correct location was significantly greater compared to controls (all p values < 0.02). While there was no significant difference in performance between patients groups in regard to forming an accurate spatial representation of the supermarket layout, the measure of Euclidean distance from the centre between trial locations found AD were significantly more impaired than bvFTD and control (Fig. 4; all p values < 0.05). Furthermore, this dissociation is reflected through qualitative differences in the pattern of responses on the spatial map component (Supplementary Fig. 1). Specifically,

AD patients demonstrated little ability in integrating navigational information from an egocentric framework to form an allocentric spatial representation of location and distance. When asked for a location at the end of each trial, patients often mention they are “at the back of the supermarket” resulting in a clustered spatial representation often located near the outer edges of the spatial map. In contrast, while AD and bvFTD performance did not significantly differ in terms of accuracy, bvFTD patient’s demonstrated evidence of ability to incorporate egocentric information, resulting in a spatial representation that was evenly distributed similar to that of controls.

---INSERT FIGURE 3 AROUND HERE---

---INSERT FIGURE 4 AROUND HERE---

### **Hippocampal and Posterior Cingulate Volume**

Regional grey matter volume of the left and right hippocampi and tail of the posterior cingulate was compared across participant groups. Bilateral hippocampal volume was significantly reduced compared to control in bvFTD and AD patient groups (all p values < 0.01) (Fig. 5). Hippocampal volume did not, however, differ between patient groups (all p values > 0.2). Volume of the posterior cingulate was also compared between control, bvFTD, and AD. No significant differences were found between participant groups (all p values > 0.4) (Fig. 5). Hippocampal and posterior cingulate volume did not show a significant correlation with egocentric and allocentric orientation performance in each participant group (all p values > 0.1).

---INSERT FIGURE 5 AROUND HERE---

## **Discussion**

Using a novel spatial memory task set in a virtual reality supermarket we reveal differences in the spatial orientation performance of bvFTD and AD patients while accounting for differences in their memory impairment. AD patients were impaired at both judging the egocentric direction back to a starting location and estimating distances and locations on a map. In contrast, bvFTD patients were only impaired on estimating distances and locations on a map. This is important because, while FTD and AD have been compared before on spatial tasks [14,21], prior studies have not directly compared bvFTD and AD, their differential performance on egocentric and allocentric spatial processing, or the association with underlying integrity of hippocampal and retrosplenial region of the posterior cingulate. Notably, it is the differential discrimination of bvFTD and AD that poses the greatest challenge during clinical diagnosis of dementia. In the current study, structural neuroimaging uncovered a similar degree of hippocampal atrophy in both patient cohorts, compared to controls. Given the strong links between the hippocampus and allocentric memory [18], and past evidence of AD patients spatial impairments [11,13], it is plausible that the hippocampal damage in both patient groups relates to the impaired allocentric map-based memory observed. By contrast, the spared performance of the bvFTD patients in the context of their extensive hippocampal damage suggests that other brain regions may mediate the ability to estimate egocentric heading direction.

Recent years has seen an influx of advanced virtual paradigms being used to address spatial navigation deficits in AD [21,22,24,33-35], as well as pre-symptomatic carriers with a genetic mutation linked to the disease [36]. A concern, however, is the extensive training necessary to form a working representation of the environment, to allow subsequent testing, in a patient population characterised by memory impairment. In this regard measures of heading

direction, relying on existing environmental knowledge [13,37] or a familiar construct (i.e. novel supermarket), provides a purer measure of disorientation while reducing cognitive load on memory processes and can be employed in patient populations with existing memory impairment, as we have previously shown using a variation of the current experimental task [11]. This is of particular interest in differentiating different patient populations with underlying hippocampal pathology, such as bvFTD and AD, as our current findings demonstrate similar levels of impaired ability to form an accurate spatial representation of the environment but a clear preservation of heading orientation performance in bvFTD.

Spatial representation of the virtual supermarket was acquired incidentally across trials in the current experimental task. Without explicit training, the accuracy of identifying correct trial locations was expected to be low. Nevertheless, average bvFTD and AD performance in identifying the correct location and erroneous distance from correct location was impaired by more than twofold, compared to control participants. This is consistent with previous spatial navigation studies that have reported allocentric hippocampal dependent spatial memory is impaired in AD [20,38]. The hippocampus is suggested to be of particular importance in accurate representation of distance between environmental objects [39,40]. Our findings, reveal bvFTD have a similar level of impairment to allocentric spatial memory as AD patients. While bvFTD is characterised by frontal and anterior temporal lobe atrophy, recent findings have implicated significant hippocampal pathology during disease progression to the same degree as AD [7,8]. Similarly, in the current study, bvFTD and AD showed the same level of bilateral hippocampal atrophy, which may account for the similar degree of inaccuracy in judging location and distance for spatial layout.

While bvFTD and AD patient groups showed the same level of accuracy in forming a correct spatial representation of the virtual supermarket, there were inherent quantitative and qualitative differences in estimating distance between the two patient groups that may hold clinical value. Across trials, bvFTD patients showed some semblance of being able to translate egocentric information obtained from viewing the video trials to an allocentric representation of spatial location. Despite being inaccurate, bvFTD patients were able to indicate a more logical position on the provided supermarket layout maps, compared to AD who would often indicate they had travelled to the same location across trials but were facing a different direction. This inability to translate spatial information from different frames of reference has been noted in previous studies in AD [13,21] and believed to represent topographical impairment resulting from dysfunction in the retrosplenial region of the posterior cingulate [19,41,42].

Our finding that bvFTD patients' show preserved ability to estimate heading direction to a point of origin has implications for the brain regions supporting path integration. Path integration is the ability to use self-motion cues to estimate the distance and direction to a point of origin, which is required in our heading orientation test. There has been disagreement in past neuropsychological studies about the extent to which the hippocampus is required for path integration [43-45]. Our data provide further evidence that, in the context of significant hippocampal damage and impaired allocentric spatial memory, the ability to estimate the heading orientation to a starting location can be relatively spared. Thus, in AD it may be damage to subcortical circuits and possibly the retrosplenial cortex that disrupts this ability. More research with larger patient cohorts will be useful to determine this.

In the current study we limited structural neuroimaging to hippocampal and posterior cingulate volume given the focus on egocentric and allocentric spatial representation in bvFTD

and AD. The retrosplenial cortex was considered too small and prone to partial volume effects for a direct volumetric analysis. The absence of a significant correlation between neural structures and behavioural performance may be a result of our small patient sample size, despite evidence of a functional dissociation between patient groups, on the virtual supermarket task. Future studies with a larger sample size will allow a more comprehensive approach for investigating underlying neural mechanisms of spatial memory processing in dementia. While patient groups were matched for disease duration, there was considerable variability present in the AD cohort, which may have influenced our volumetric analysis of the hippocampus. Our finding of a similar level of hippocampal pathology between bvFTD and AD patient groups, however, is consistent with growing reports of atrophy to this structure present in FTD, in particular bvFTD [7,8]. FTD and AD, in particular, provide a unique opportunity to further elucidate the functional interaction of regions beyond the medial temporal lobe in topographical memory processes, given the similar degree of hippocampal pathology present across these clinical syndromes.

In conclusion, allocentric spatial representations are impaired in both bvFTD and AD, which share hippocampal pathology during the course of disease. In contrast, heading orientation is preserved in bvFTD and should be the targeted by clinical tasks of spatial memory performance to aid differential diagnosis. Future studies of spatial orientation in selective bvFTD cases with more extensive memory impairment would be of particular value in establishing its role as a discriminating diagnostic feature to AD.



## **Acknowledgements**

This work was supported by funding to Forefront, a collaborative research group dedicated to the study of frontotemporal dementia and motor neurone disease, from the National Health and Medical research Council (NHMRC) of Australia program grant (#1037746), the Australian Research Council (ARC) Centre of Excellence in Cognition and its Disorders Memory Node (#CE110001021) and an ARC Discovery Project grant (DP1093279). ST is supported by Alzheimer's Australia Dementia Research Foundation and NHMRC of Australia awards. OP is supported by a NHMRC Career Development Fellowship (APP1022684). MH is supported by Alzheimer Research UK and the Isaac Newton Trust. These funding sources had no involvement in the study design, collection, analysis and interpretation of data, writing the manuscript, and in the decision to submit the manuscript for publication. The authors report no conflict of interest. We are grateful to the research participants and carers involved with ForeFront research studies.

## References

- [1] Chare L, Hodges JR, Leyton CE, McGinley C, Tan RH, Kril JJ, Halliday GM (2014) New criteria for frontotemporal dementia syndromes: clinical and pathological diagnostic implications. *J Neurol Neurosurg Psychiatry* **85**, 865-870.
- [2] Rascovsky K, Hodges JR, Knopman D, Mendez MF, Kramer JH, Neuhaus J, van Swieten JC, Seelaar H, Dopper EG, Onyike CU, Hillis AE, Josephs KA, Boeve BF, Kertesz A, Seeley WW, Rankin KP, Johnson JK, Gorno-Tempini ML, Rosen H, Prigleau-Latham CE, Lee A, Kipps CM, Lillo P, Piguet O, Rohrer JD, Rossor MN, Warren JD, Fox NC, Galasko D, Salmon DP, Black SE, Mesulam M, Weintraub S, Dickerson BC, Diehl-Schmid J, Pasquier F, Deramecourt V, Lebert F, Pijnenburg Y, Chow TW, Manes F, Grafman J, Cappa SF, Freedman M, Grossman M, Miller BL (2011) Sensitivity of revised diagnostic criteria for the behavioural variant of frontotemporal dementia. *Brain* **134**, 2456-2477.
- [3] Perry RJ, Hodges JR (2000) Differentiating frontal and temporal variant frontotemporal dementia from Alzheimer's disease. *Neurology* **54**, 2277-2284.
- [4] Glosser G, Gallo JL, Clark CM, Grossman M (2002) Memory encoding and retrieval in frontotemporal dementia and Alzheimer's disease. *Neuropsychology* **16**, 190-196.
- [5] Bertoux M, de Souza LC, Corlier F, Lamari F, Bottlaender M, Dubois B, Sarazin M (2014) Two distinct amnesic profiles in behavioral variant frontotemporal dementia. *Biol Psychiatry* **75**, 582-588.
- [6] Hornberger M, Piguet O, Graham AJ, Nestor PJ, Hodges JR (2010) How preserved is episodic memory in behavioral variant frontotemporal dementia? *Neurology* **74**, 472-479.
- [7] de Souza LC, Chupin M, Bertoux M, Lehericy S, Dubois B, Lamari F, Le Ber I, Bottlaender M, Colliot O, Sarazin M (2013) Is hippocampal volume a good marker to differentiate Alzheimer's disease from frontotemporal dementia? *J Alzheimers Dis* **36**, 57-66.
- [8] Hornberger M, Wong S, Tan R, Irish M, Piguet O, Kril J, Hodges JR, Halliday G (2012) In vivo and post-mortem memory circuit integrity in frontotemporal dementia and Alzheimer's disease. *Brain* **135**, 3015-3025.
- [9] Bruner E, Jacobs HI (2013) Alzheimer's disease: the downside of a highly evolved parietal lobe? *J Alzheimers Dis* **35**, 227-240.
- [10] Nestor PJ, Fryer TD, Ikeda M, Hodges JR (2003) Retrosplenial cortex (BA 29/30) hypometabolism in mild cognitive impairment (prodromal Alzheimer's disease). *Eur J Neurosci* **18**, 2663-2667.

- [11] Tu S, Wong S, Hodges JR, Irish M, Piguet O, Hornberger M (2015) Lost in spatial translation - A novel tool to objectively assess spatial disorientation in Alzheimer's disease and frontotemporal dementia. *Cortex* **67**, 83-94.
- [12] Yew B, Alladi S, Shailaja M, Hodges JR, Hornberger M (2013) Lost and forgotten? Orientation versus memory in Alzheimer's disease and frontotemporal dementia. *J Alzheimers Dis* **33**, 473-481.
- [13] Pai MC, Jacobs WJ (2004) Topographical disorientation in community-residing patients with Alzheimer's disease. *Int J Geriatr Psychiatry* **19**, 250-255.
- [14] Pengas G, Patterson K, Arnold RJ, Bird CM, Burgess N, Nestor PJ (2010) Lost and found: bespoke memory testing for Alzheimer's disease and semantic dementia. *J Alzheimers Dis* **21**, 1347-1365.
- [15] Pengas G, Hodges JR, Watson P, Nestor PJ (2010) Focal posterior cingulate atrophy in incipient Alzheimer's disease. *Neurobiol Aging* **31**, 25-33.
- [16] Pennington C, Hodges JR, Hornberger M (2011) Neural correlates of episodic memory in behavioral variant frontotemporal dementia. *J Alzheimers Dis* **24**, 261-268.
- [17] Irish M, Piguet O, Hodges JR, Hornberger M (2014) Common and unique gray matter correlates of episodic memory dysfunction in frontotemporal dementia and Alzheimer's disease. *Hum Brain Mapp* **35**, 1422-1435.
- [18] O'Keefe J, Nadel L (1978) *The Hippocampus as a Cognitive Map*, Oxford University Press.
- [19] Vann SD, Aggleton JP, Maguire EA (2009) What does the retrosplenial cortex do? *Nat Rev Neurosci* **10**, 792-802.
- [20] Serino S, Cipresso P, Morganti F, Riva G (2014) The role of egocentric and allocentric abilities in Alzheimer's disease: a systematic review. *Ageing Res Rev* **16**, 32-44.
- [21] Bellassen V, Igloi K, de Souza LC, Dubois B, Rondi-Reig L (2012) Temporal order memory assessed during spatiotemporal navigation as a behavioral cognitive marker for differential Alzheimer's disease diagnosis. *J Neurosci* **32**, 1942-1952.
- [22] Laczó J, Vlcek K, Vyhnalek M, Vajnerova O, Ort M, Holmerova I, Tolar M, Andel R, Bojar M, Hort J (2009) Spatial navigation testing discriminates two types of amnesic mild cognitive impairment. *Behav Brain Res* **202**, 252-259.
- [23] Pai MC, Yang YC (2013) Impaired translation of spatial representation in young onset Alzheimer's disease patients. *Curr Alzheimer Res* **10**, 95-103.

- [24] Laczó J, Andel R, Vyhnalek M, Vlcek K, Magerova H, Varjassyova A, Nedelska Z, Gazova I, Bojar M, Sheardova K, Hort J (2012) From Morris Water Maze to computer tests in the prediction of Alzheimer's disease. *Neurodegener Dis* **10**, 153-157.
- [25] Luzzi S, Cafazzo V, Damora A, Fabi K, Fringuelli FM, Ascoli G, Silvestrini M, Provinciali L, Reverberi C (2015) The neural correlates of road sign knowledge and route learning in semantic dementia and Alzheimer's disease. *J Neurol Neurosurg Psychiatry* **86**, 595-602.
- [26] McKhann GM, Knopman DS, Chertkow H, Hyman BT, Jack CR, Jr, Kawas CH, Klunk WE, Koroshetz WJ, Manly JJ, Mayeux R, Mohs RC, Morris JC, Rossor MN, Scheltens P, Carrillo MC, Thies B, Weintraub S, Phelps CH (2011) The diagnosis of dementia due to Alzheimer's disease: recommendations from the National Institute on Aging-Alzheimer's Association workgroups on diagnostic guidelines for Alzheimer's disease. *Alzheimers Dement* **7**, 263-269.
- [27] Kipps CM, Hodges JR, Hornberger M (2010) Nonprogressive behavioural frontotemporal dementia: recent developments and clinical implications of the 'bvFTD phenocopy syndrome'. *Curr Opin Neurol* **23**, 628-632.
- [28] Waterlander WE, Scarpa M, Lentz D, Steenhuis IH (2011) The virtual supermarket: an innovative research tool to study consumer food purchasing behaviour. *BMC Public Health* **11**, 589-2458-11-589.
- [29] Land MF (2014) Do we have an internal model of the outside world? *Philosophical Transactions of the Royal Society B: Biological Sciences* **369**.
- [30] Smith SM (2002) Fast robust automated brain extraction. *Hum Brain Mapp* **17**, 143-155.
- [31] Zhang Y, Brady M, Smith S (2001) Segmentation of brain MR images through a hidden Markov random field model and the expectation-maximization algorithm. *IEEE Trans Med Imaging* **20**, 45-57.
- [32] Spiers HJ, Maguire EA (2007) The neuroscience of remote spatial memory: a tale of two cities. *Neuroscience* **149**, 7-27.
- [33] Morganti F, Stefanini S, Riva G (2013) From allo- to egocentric spatial ability in early Alzheimer's disease: a study with virtual reality spatial tasks. *Cogn Neurosci* **4**, 171-180.
- [34] Weniger G, Ruhleder M, Lange C, Wolf S, Irle E (2011) Egocentric and allocentric memory as assessed by virtual reality in individuals with amnesic mild cognitive impairment. *Neuropsychologia* **49**, 518-527.
- [35] Plancher G, Tirard A, Gyselinck V, Nicolas S, Piolino P (2012) Using virtual reality to characterize episodic memory profiles in amnesic mild cognitive impairment and Alzheimer's disease: influence of active and passive encoding. *Neuropsychologia* **50**, 592-602.

- [36] Kunz L, Schroder TN, Lee H, Montag C, Lachmann B, Sariyska R, Reuter M, Stirnberg R, Stocker T, Messing-Floeter PC, Fell J, Doeller CF, Axmacher N (2015) Reduced grid-cell-like representations in adults at genetic risk for Alzheimer's disease. *Science* **350**, 430-433.
- [37] Campbell JI, Hepner IJ, Miller LA (2014) The influence of age and sex on memory for a familiar environment. *J Environ Psychol* **40**, 1-8.
- [38] Burgess N, Trinkler I, King J, Kennedy A, Cipelotti L (2006) Impaired allocentric spatial memory underlying topographical disorientation. *Rev Neurosci* **17**, 239-251.
- [39] Morgan LK, Macevoy SP, Aguirre GK, Epstein RA (2011) Distances between real-world locations are represented in the human hippocampus. *The Journal of neuroscience : the official journal of the Society for Neuroscience* **31**, 1238-45.
- [40] Howard LR, Javadi AH, Yu Y, Mill RD, Morrison LC, Knight R, Loftus MM, Staskute L, Spiers HJ (2014) The hippocampus and entorhinal cortex encode the path and Euclidean distances to goals during navigation. *Curr Biol* **24**, 1331-1340.
- [41] Ino T, Doi T, Hirose S, Kimura T, Ito J, Fukuyama H (2007) Directional disorientation following left retrosplenial hemorrhage: a case report with fMRI studies. *Cortex* **43**, 248-254.
- [42] Takahashi N, Kawamura M, Shiota J, Kasahata N, Hirayama K (1997) Pure topographic disorientation due to right retrosplenial lesion. *Neurology* **49**, 464-469.
- [43] Worsley CL, Recce M, Spiers HJ, Marley J, Polkey CE, Morris RG (2001) Path integration following temporal lobectomy in humans. *Neuropsychologia* **39**, 452-464.
- [44] Philbeck JW, Behrmann M, Levy L, Potolicchio SJ, Caputy AJ (2004) Path integration deficits during linear locomotion after human medial temporal lobectomy. *J Cogn Neurosci* **16**, 510-520.
- [45] Kim S, Sapiurka M, Clark RE, Squire LR (2013) Contrasting effects on path integration after hippocampal damage in humans and rats. *Proc Natl Acad Sci U S A* **110**, 4732-4737.

**Table 1.** Participant demographic characteristics and performance on standardised neuropsychological assessments.

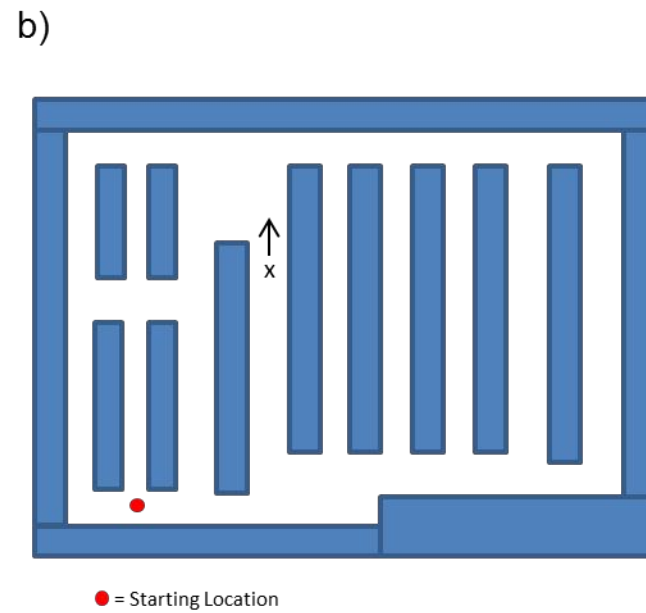
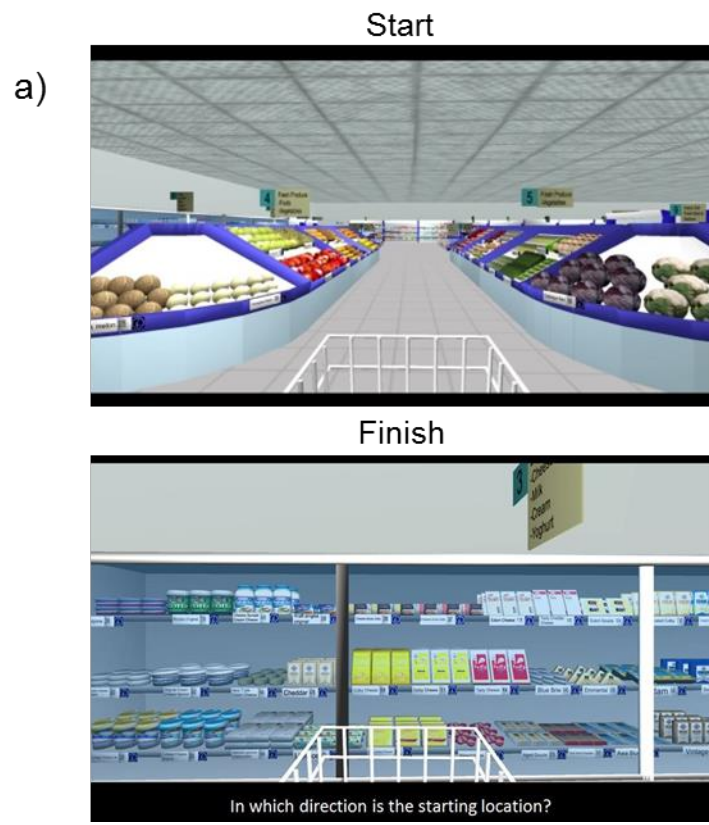
	<b>AD (n = 11)</b>	<b>bvFTD (n = 11)</b>	<b>Control (n = 14)</b>	<b>Group Effect</b>	<b>AD vs. bvFTD</b>	<b>Control vs. AD</b>	<b>Control vs. bvFTD</b>
<b>Sex (M/F)</b>	7 M, 4 F	8 M, 3 F	7 M, 7 F	-	-	-	-
<b>Handedness (L/R)</b>	10 R, 1 L	11 R	14 R	-	-	-	-
<b>Age (y.o)</b>	65 (7.9)	61.3 (7.6)	65 (6.2)	n/s	n/s	n/s	n/s
<b>Education (yrs)</b>	11.8 (2.4)	11.3 (2.5)	14.2 (2.3)	*	n/s	n/s	*
<b>Disease Duration (yrs)</b>	4.2 (3.4)	3.6 (1.4)	-	-	n/s	-	-
<b>CDR (SOB)</b>	4.5 (1.7)	5.9 (3.2)	-	-	n/s	-	-
<b>ACE-R:</b>							
<b>Total (/100)</b>	62.9 (9.1)	78.3 (13)	95.8 (2.7)	**	*	**	**
<b>Memory (/26)</b>	10.8 (4.5)	18.3 (4.2)	25.1 (1.4)	**	**	**	**
<b>Orientation (/10)</b>	6.5 (2.4)	8.9 (1.3)	10 (0)	**	*	**	*
<b>RAVLT:</b>							
<b>T1-5 (/75)</b>	22.1 (7.5)	35.7 (12.2)	51.4 (7.5)	**	*	**	*
<b>30 min (/15)</b>	1.5 (1.7)	6.3 (3.5)	9.5 (3.2)	**	*	**	*
<b>Recognition (/15)</b>	10.8 (4.3)	13.6 (1.4)	13.6 (1)	*	n/s	*	n/s
<b>RCFT:</b>							
<b>Copy (/36)</b>	25.5 (10.5)	27.3 (7.6)	33.4 (1.9)	*	n/s	*	n/s
<b>Delayed (/36)</b>	4.6 (5.4)	9.5 (6.6)	19.9 (5.3)	**	n/s	**	**
<b>Digit Span:</b>							
<b>Forward (/16)</b>	8 (2.5)	9.1 (2.8)	12.2 (2)	**	n/s	**	*
<b>Backward (/14)</b>	4.3 (2.3)	5.5 (1.8)	8.5 (2.2)	**	n/s	**	**

**Note:** Clinical dementia rating (CDR) sum of boxes; Addenbrooke's cognitive examination revised (ACE-R); Rey auditory verbal learning test (RAVLT); Rey complex figure test (RCFT). RAVLT scores were available from 8 AD and 9 bvFTD patients.

n/s = not significant

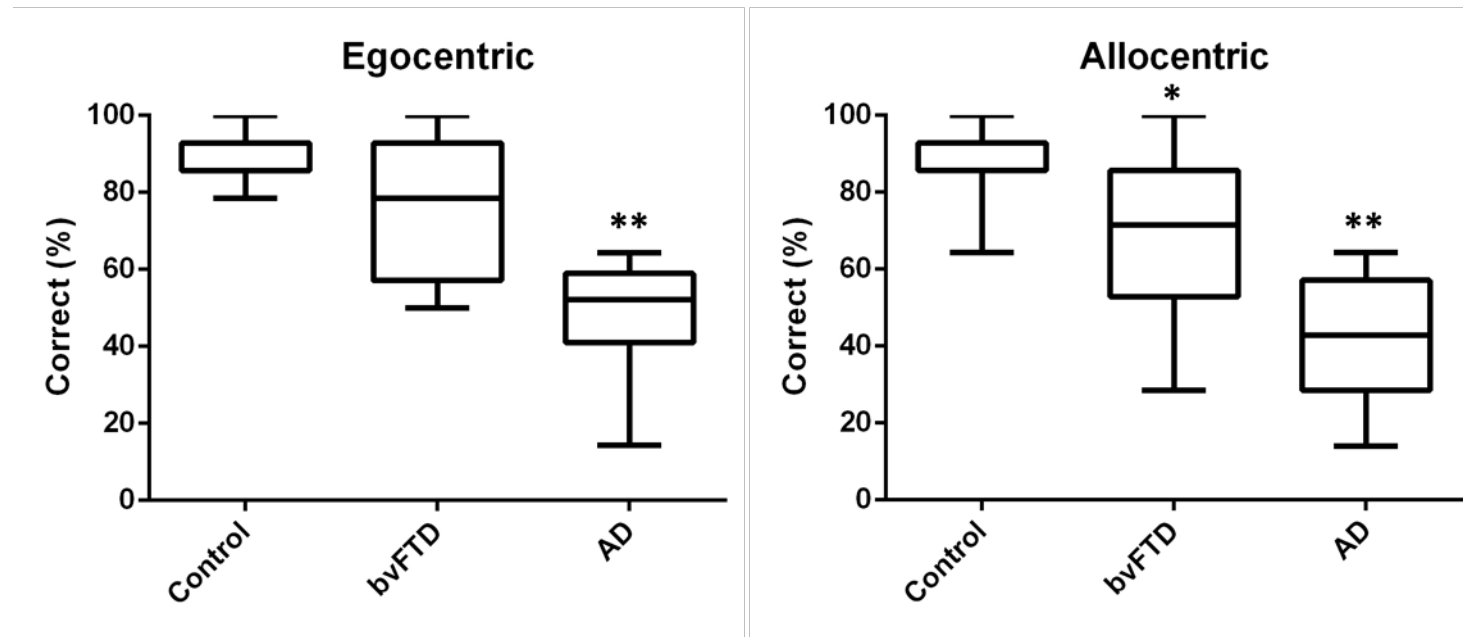
\* P < 0.05

\*\*P < 0.005



**Figure 1.** Example of egocentric and allocentric components of the virtual supermarket task. (a) Participants view videos travelling to a new location within the supermarket and asked for heading direction to starting location. (b) Participants are presented with a spatial map and asked to mark current location and heading direction.

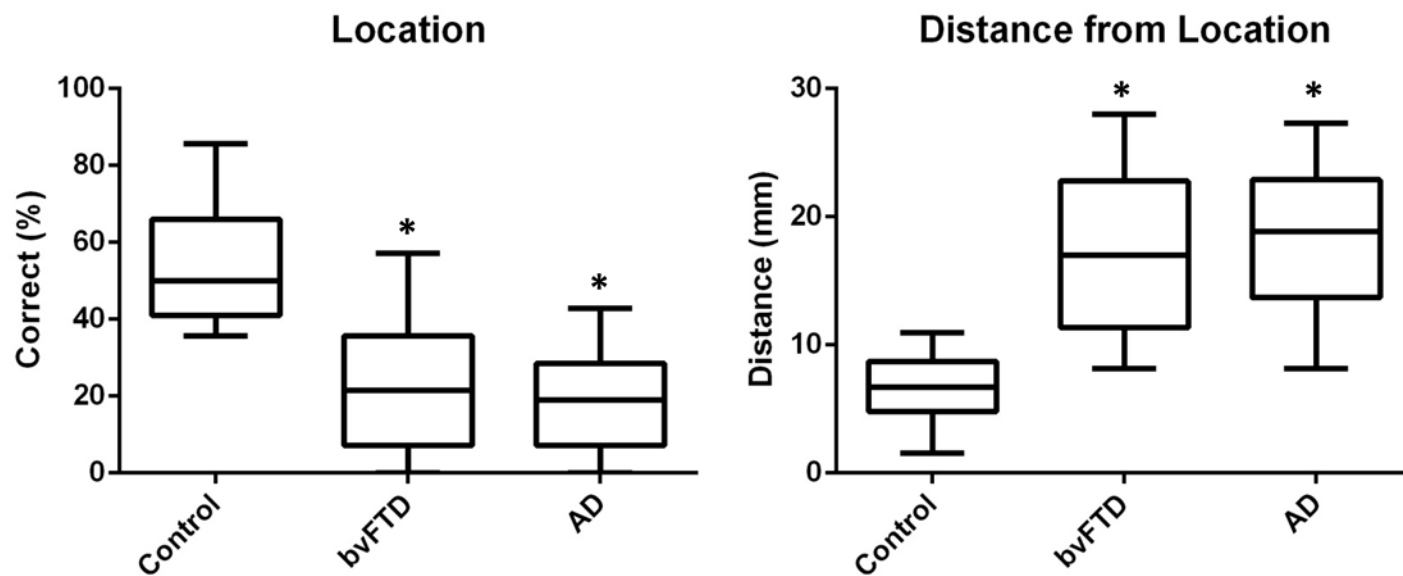
## Heading Orientation



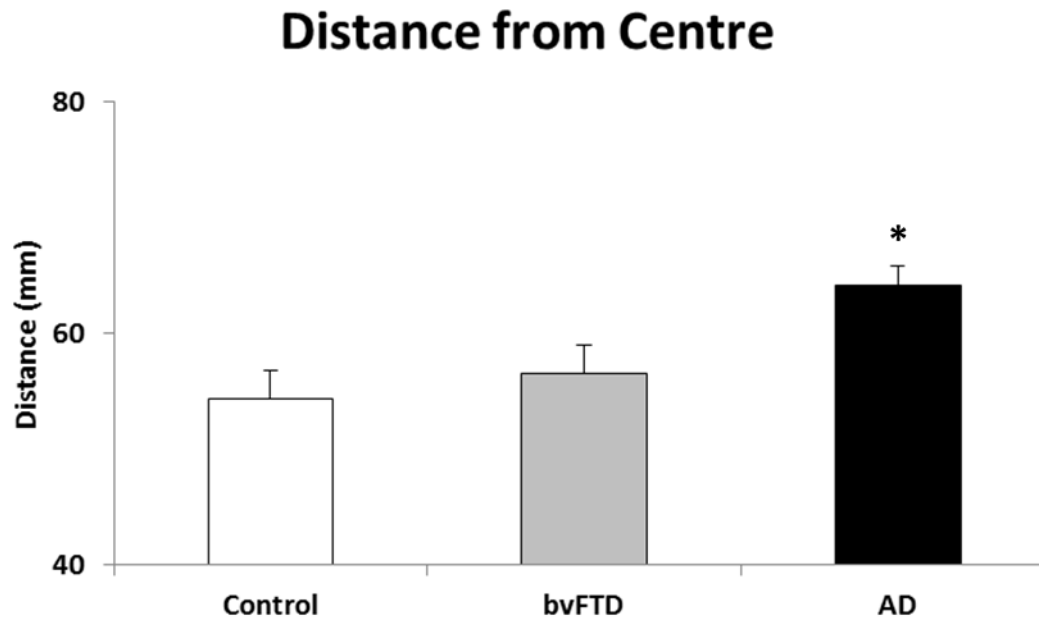
**Figure 2.** Correct egocentric and allocentric heading direction performance on the virtual supermarket task in patient and control participants. \*Indicates significance to control and AD groups at  $p < 0.05$ . \*\*Indicates significance to control and bvFTD groups at  $p < 0.05$ .



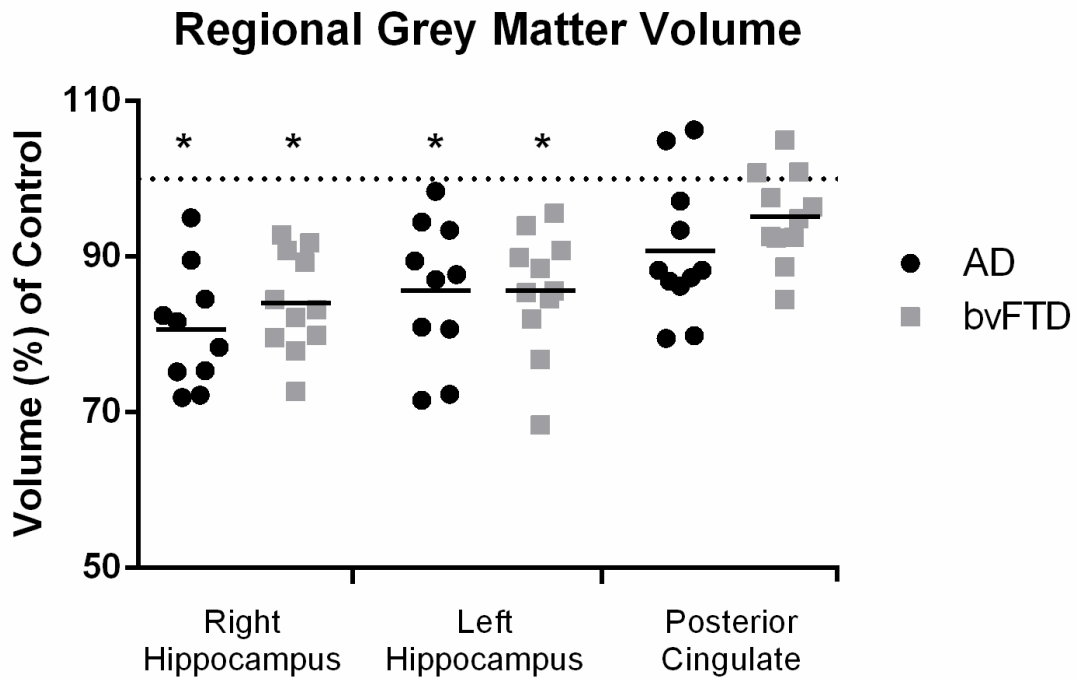
## Spatial Layout



**Figure 3.** Patient and healthy control participants' performance on the spatial layout component of the virtual supermarket task: judgement of correct spatial location and distance from correct location. \*Indicates significance to control at  $p < 0.01$ .



**Figure 4.** Mean Euclidean distance of participants' spatial representations from the centre of the map on the spatial layout component of the virtual supermarket task. \*Indicates significance to control and bvFTD at  $p < 0.01$ .



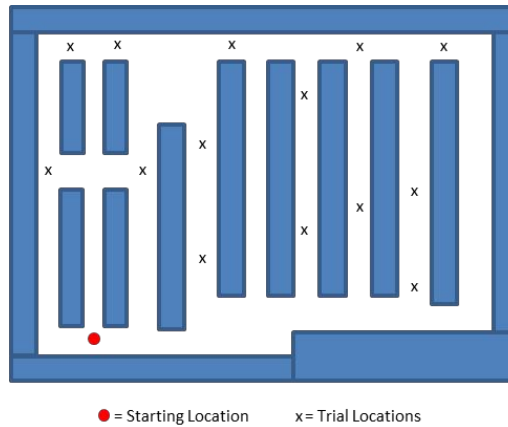
**Figure 5.** Regional grey matter volume in AD and bvFTD patients as a percentage of healthy control volume. \* Indicates significance to control at  $p < 0.05$ .

**Supplementary Table 1.** Description of neuropsychological tasks administered.

Neuropsychological Test	Task Components
Addenbrooke Cognitive Exam –Revised (ACE-R)  (Mioshi et al., 2006)	The ACE-R is a general screening measure of cognition scored out of 100 and contains sub-components assessing: attention and orientation, memory, verbal fluency, language, and visuospatial skills. The memory subtest score comprises (1) recall after brief distraction of a three-item list, (2) recall of a seven-item name and address on the third learning trial, (3) delayed recall and recognition of the name and address, (4) recall of the names of 4 specified current and previous politicians.
Rey Auditory Verbal Learning Test (RAVLT)  (Schmidt, 1996)	RAVLT is a measure of episodic memory recall for verbal information. <b>A1-5:</b> a list of 15 words is read aloud over five consecutive trials, each followed by a free recall test <b>B1:</b> a second ‘interference’ list of 15 words is read aloud followed by a free recall test <b>A6:</b> participants are required to recall words from the first list again <b>30 min Delayed recall:</b> 30min after A6, participants are asked to recall words from the first list <b>Recognition:</b> after the delayed recall test, participants perform a recognition test containing all items from the first and interference lists in addition to 20 new words. They are asked to say yes or no as to whether each word occurred on the first list.
Rey-Osterrieth Complex Figure Test (RCFT)  (Meyers & Meyers, 1995)	RCFT is a measure of episodic memory recall for visual information. <b>Copy:</b> participants are asked to copy a complex figure as accurately as possible <b>Delayed:</b> 3 minutes after copying, participants are instructed to reproduce the figure from memory
Digit Span  (Kaplan & Saccuzzo, 2009)	Digit Span is a measure of working memory. A series of numbers are read aloud and participants must repeat the numbers either in the same order ( <b>Forward</b> ) or reversed ( <b>Backward</b> ).

References

- Meyers, J., & Meyers, K. (1995). *The Meyers Scoring System for the Rey Complex Figure and the Recognition Trial: Professional Manual*. Odessa, FL: Psychological Assessment Resources.
- Mioshi, E., Dawson, K., Mitchell, J., Arnold, R., & Hodges, J. R. (2006). The Addenbrooke's Cognitive Examination Revised (ACE-R): a brief cognitive test battery for dementia screening. *Int J Geriatr Psychiatry*, 21(11), 1078-1085.
- Schmidt, M. (1996). *Rey Auditory and Verbal Learning Test: A Handbook*. Los Angeles: Western Psychological Services.
- Kaplan, R. M. & Saccuzzo, D. P. (2009). *Psychological Testing: Principles, Applications, and Issues*. Belmont (CA): Wadsworth.






● = Starting Location    x = Trial Locations

**Control**

**bvFTD**

**AD**



**Supplementary Figure 1.** Representative responses on the spatial map component of the virtual supermarket task from participant groups. An example map of correct trial locations is shown at the top.

**Supplementary Table 2.** Mean participant hippocampal and posterior cingulate volume. Mean and standard deviation provided.

	<b>AD</b>	<b>bvFTD</b>	<b>Control</b>
<b>Left HC</b>	3754.5 (352.2)*	3913.8 (301.1)*	4655.7 (133.3)
<b>Right HC</b>	4072.2 (432.2)*	4071.4 (371.7)*	4756 (188.5)
<b>Posterior Cingulate</b>	2760.3 (325.8)	2782.2 (325.7)	3011.5 (311)

\*Indicates significance to control at  $p < 0.05$